

**BRYSON BORG, MD**Department of Diagnostic Radiology,
The Cleveland Clinic Foundation**BRIAN R. HERTS, MD**Department of Diagnostic Radiology,
The Cleveland Clinic Foundation**THOMAS J. MASARYK, MD**Head, Section of Neuroradiology, Department of
Diagnostic Radiology, and the Department of
Neurologic Surgery, The Cleveland Clinic Foundation

Imaging in Practice

Imaging in acute brain infarction

Q: A 77-YEAR-OLD AFRICAN AMERICAN woman is brought by ambulance to the emergency department at 2:15 PM. At 12:30 PM she had been at church, when her friends noted that she seemed dazed. Since they knew she has diabetes mellitus, they thought she might be hypoglycemic and so gave her some orange juice, but she did not improve. She developed weakness on her right side, and her friends called 911.

On physical examination, she responds to loud questions with simple one-word or two-word sentences, correctly gives the year and her age, and can follow simple commands. Her pupils measure 3 mm, are symmetric, and react normally to light, and eye movements are intact. There may be a right visual field deficit. Right-arm strength is +1/5, right leg +2/5, and both left extremities +5/5. She has an upgoing Babinski reflex on the right.

Acute stroke is strongly suspected.

Which imaging test is recommended in the management of this patient?

A: Given that the benefit of intravenous thrombolysis for acute stroke—if therapy is given within 3 hours of onset of symptoms—has been validated by several clinical trials, two key principles currently guide the use of imaging in stroke therapy:

Imaging must rule out contraindications

The current standard of care for initiating thrombolytic therapy does not depend on a positive radiographic diagnosis. The diagnosis of acute stroke can be reliably made on the basis of patient history and the physical examination. The primary goal of imaging is to rule out contraindications to thrombolytic therapy, such as intracranial hemorrhage or brain metastases.

Imaging must be immediately available

Thrombolytic therapy is most successful when started within 3 hours of the onset of symptoms. After 3

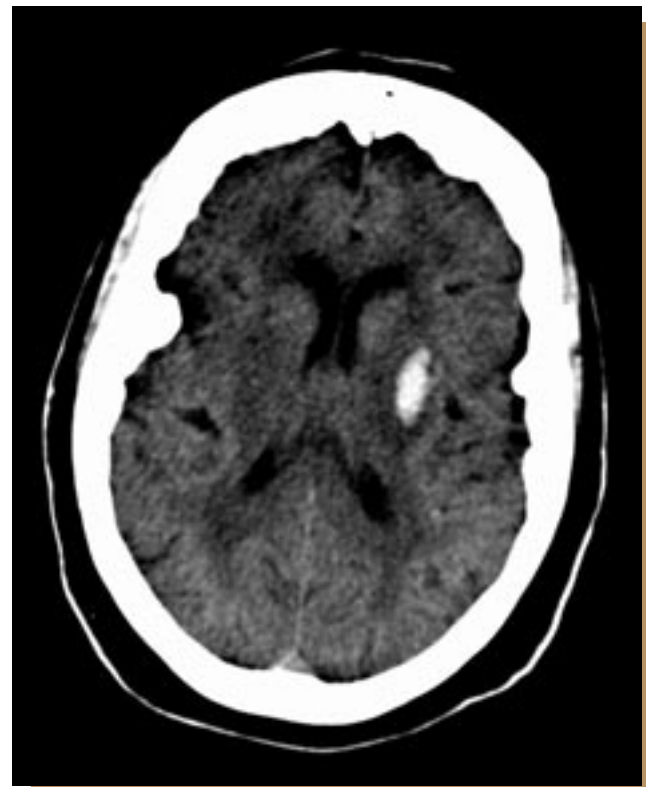

FIGURE 1. A noncontrast CT image of a different patient with malignant hypertension who developed an intraparenchymal hemorrhage in the left globus pallidus. Thrombolytic therapy would likely cause serious complications in this patient.

hours, the benefit of thrombolytic therapy is lost due to completion of the underlying infarction, as well as to an increased incidence of intracranial hemorrhage with thrombolytic therapy. Thus, for an imaging procedure to make an impact on patient outcome, it must be immediately available.

Get with the Guidelines, the American Heart Association and American Stroke Association pro-



gram for acute care hospitals, states that imaging must be obtained within 20 minutes of arrival to the emergency department and interpreted within 20 minutes after that.

The decision to give thrombolytic therapy should not be made lightly. If used incorrectly, such as when there is intracranial hemorrhage (**FIGURE 1**), thrombolytic therapy can worsen outcome by causing additional intracranial hemorrhage.

■ IMAGING OPTIONS

Noncontrast computed tomography (CT) of the brain is currently the examination of choice for initial imaging of suspected acute stroke. It is simple, takes less than 5 minutes, and is available in almost every emergency department. It is not as sensitive as magnetic resonance imaging (MRI) for acute ischemic stroke, and the scan is often normal during the first few hours of symptoms, but it has a high sensitivity for acute bleeding, one of the primary exclusion criteria for thrombolytic therapy. Noncontrast CT can also identify other contraindications to thrombolytic therapy, such as subdural and epidural hematomas and intracranial mass lesions of sufficient size to cause neurologic dysfunction, but it is not sensitive for small lesions.

Ischemic findings on noncontrast CT first appear 2 to 6 hours after the onset of symptoms. Involvement of more than one third of a vascular territory typically indicates that the opportunity for treatment has passed.

Contrast-enhanced CT of the brain is not often used in the evaluation of acute stroke. Normal leptomeningeal enhancement may obscure small amounts of subarachnoid blood, and therefore contrast-enhanced CT should not be used alone. Moreover, routinely performing contrast-enhanced CT in addition to noncontrast CT provides little additional information and takes additional time.

CT angiography. Newer CT scanners offer the possibility of performing both perfusion and angiographic examinations in one setting. CT angiography uses rapid bolus intravenous injection of contrast material in conjunction with high-resolution and sub-second helical CT scanning techniques. Neurologic CT angiography can detect aneurysms, dissections, vascular stenoses, and many occlusions. Still, these newer CT techniques cannot clearly image certain features of the anatomy, eg, the small vessels supplying the basal ganglia. Therefore, a negative CT angiogram does not exclude a patient from consideration for

thrombolytic therapy.

CT perfusion imaging is used to identify regions of the brain parenchyma with diminished or delayed blood flow. However, CT perfusion is performed only at two levels in the brain and therefore may miss ischemic regions outside the evaluated slices. Workstation software calculates cerebral blood volume, time to peak enhancement, and cerebral blood flow. The information gained from CT perfusion studies is being used by various investigators to predict final infarct size and may someday be a part of standardized treatment protocols.

MRI with diffusion-weighted imaging is the most sensitive way to detect acute cerebral infarction. MRI is also sensitive for intracranial hemorrhage. However, many emergency departments lack easy access to MRI and so it is not often available for the evaluation of acute stroke. The examination takes 20 to 25 minutes and is thus more time-consuming than CT. Ischemic changes due to transient ischemic attack or stroke become apparent on diffusion-weighted MRI within minutes of symptom onset, hours before changes are visible on either noncontrast CT or standard MRI. A diffusion abnormality nearly always returns to normal 2 weeks or more after symptom onset, so diffusion-weighted MRI is useful in differentiating acute ischemia from subacute or chronic ischemia.

As with CT, both perfusion imaging and angiography can be performed with MRI. A mismatch between an area of diminished perfusion and an area of restricted diffusion may indicate a region of viable brain tissue, which can be expected to become infarcted if no intervention is performed.

In the future, an examination with limited diffusion-weighted MRI and perfusion MRI may become part of a standard treatment protocol. In patients in whom the diagnosis of cerebrovascular infarction needs to be confirmed in either the acute or the subacute setting, MRI would be the test of choice. Of importance, patients with cardiac pacing devices and certain other implantable devices should not undergo MRI.

Ultrasonography has limited use in the evaluation of acute stroke, mostly because the information gained from it plays little or no role in directing immediate therapy. Some investigators contend that transcranial Doppler ultrasonography can be used in the acute setting to monitor the progress of thrombolytic therapy, yet ultrasonography continues to be used mainly in the subacute setting.

Carotid artery ultrasound can evaluate for critical stenosis or plaques in the carotid bifurcations, which

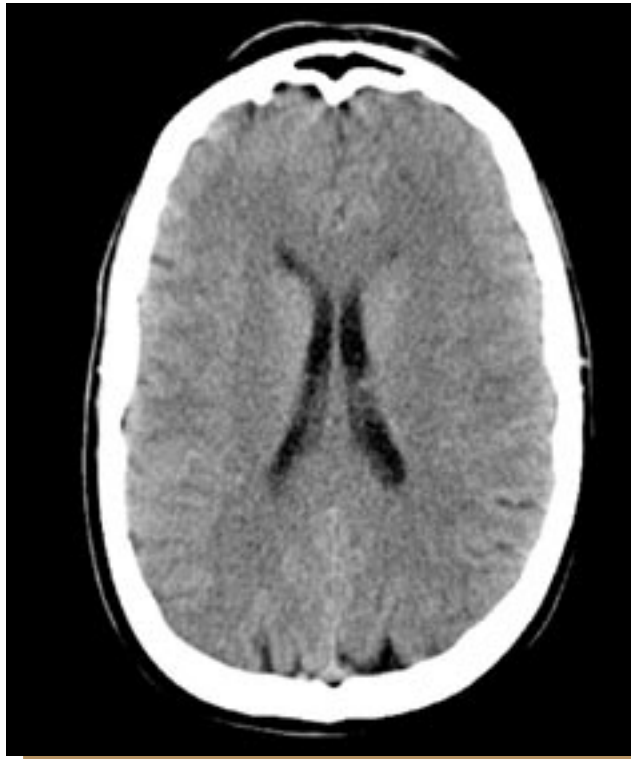

FIGURE 2. A noncontrast CT image of the brain through the level of the corona radiata is normal, with normal differentiation of the gray and white matter and no mass effect or intracranial hemorrhage.

may be the source of emboli. Similarly, echocardiography can be used to evaluate the heart for mural thrombus or valvular vegetations. Transcranial Doppler ultrasonography can show lack of flow in the cerebral vessels or waveform changes that suggest a more distal obstruction.

Cerebral angiography can accurately show occlusion of the intracranial vessels, but due to its invasiveness, high cost, and time required, it is not appropriate for the primary evaluation of acute stroke. In addition, angiography can rarely define occlusion of the small vessels responsible for lacunar infarcts, and it only indirectly detects subarachnoid hemorrhage. As such, its primary use in acute stroke is in guiding intra-arterial thrombolytic therapy delivered via catheter. Cerebral angiography is also useful for the diagnosis and treatment of spasm related to subarachnoid hemorrhage.

Cerebral radionuclide scintigraphy has no role in the evaluation of acute stroke because it takes too long to perform and is not often available 24 hours a day.

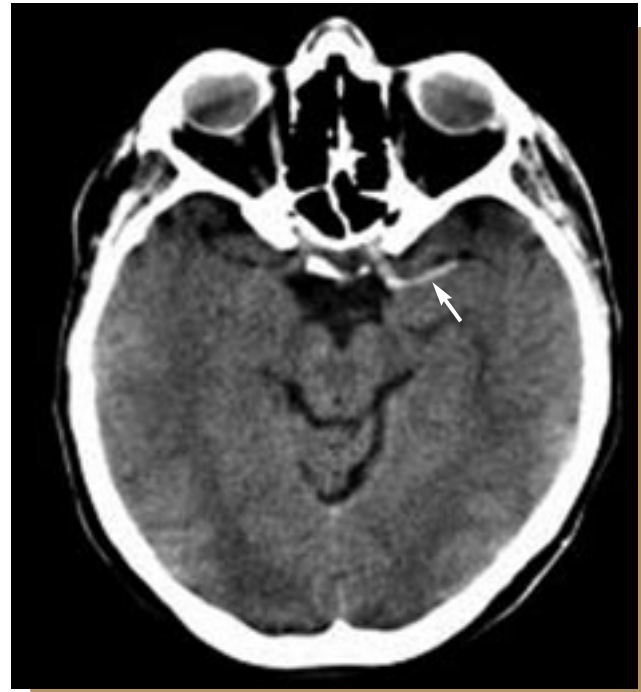

FIGURE 3. A CT image through the level of the internal carotid artery terminus showed a curvilinear density just lateral to the left anterior clinoid process (arrow). This finding represents embolism within the left internal carotid artery.


IMAGING FINDINGS

Our patient undergoes noncontrast CT of the brain, which shows no evidence of intracranial hemorrhage (FIGURE 2). The border between the gray and white matter is preserved throughout the brain, and there is no evidence of parenchymal edema. There is, however, a curvilinear density in the internal carotid artery terminus and proximal left middle cerebral artery, representing acute embolic material (FIGURE 3). Subsequently, the patient undergoes catheter-directed intra-arterial thrombolysis with mechanical disruption of the embolus.

SUMMARY

Imaging in a patient suspected of having suffered an acute stroke is used primarily to clear the patient for thrombolytic therapy, by excluding intracranial hemorrhage and nonstroke causes of the patient's symptoms, within a critical 3-hour window. Noncontrast CT of the brain is the imaging test of choice for the initial evaluation of a patient with suspected acute ischemic stroke. It is rapid and readily available and



has a high sensitivity for intracranial hemorrhage. Contrast-enhanced CT angiography and perfusion imaging may provide additional information with only a minimal increase in scanning time. Finally, diffusion-weighted magnetic resonance sequences have a high sensitivity for acute stroke and, with magnetic resonance perfusion imaging, may play an increasing role in the future treatment of stroke. 

■ SUGGESTED READING

The National Institute of Neurological Disorders and Stroke rt-PA Stroke Study Group. Tissue plasminogen activator for acute ischemic stroke. *N Engl J Med* 1995; 333:1581–1587.

Chan PH. Role of oxidants in ischemic brain damage. *Stroke* 1996; 27:1124–1129.

Furlan A, Higashida R, Wechsler L, et al. Intra-arterial prourokinase for acute ischemic stroke. The PROACT II study: a randomized controlled trial. *Prolyse in Acute Cerebral Thromboembolism. JAMA* 1999; 282:2003–2011.

Hacke W, Kaste M, Fieschi C, et al. Intravenous thrombolysis with recombinant tissue plasminogen activator for acute hemispheric stroke. The European Cooperative Acute Stroke Study (ECASS). *JAMA* 1995; 274:1017–1025.

Katzan IL, Furlan AJ, Lloyd LE, et al. Use of tissue-type plasminogen activator for acute ischemic stroke: the Cleveland area experience. *JAMA* 2000; 283:1151–1158.

Koenig M, Kraus M, Theek C, Klotz E, Gehlen W, Heuser L. Quantitative assessment of the ischemic brain by means of perfusion-related parameters derived from perfusion CT. *Stroke* 2001; 32:431–437.

Schellinger PD, Fiebach JB, Mohr A, Ringleb PA, Jansen O, Hacke W. Thrombolytic therapy for ischemic stroke—a review. Part I—intravenous thrombolysis. *Crit Care Med* 2001; 29:1812–1818.

Schellinger PD, Fiebach JB, Mohr A, Ringleb PA, Jansen O, Hacke W. Thrombolytic therapy for ischemic stroke—a review. Part II—intra-arterial thrombolysis, vertebrobasilar stroke, phase IV trials, and stroke imaging. *Crit Care Med* 2001; 29:1819–1825.

Sunshine JL, Bambakidis N, Tarr RW, et al. Benefits of perfusion MR imaging relative to diffusion MR imaging in the diagnosis and treatment of hyperacute stroke. (*AJNR*) *Am J Neuroradiol* 2001; 22:915–921.

Tanne D, Mansbach HH, Verro P, et al. Intravenous rt-PA therapy for stroke in clinical practice: a multicenter evaluation of clinical outcome [abstract]. *Stroke* 1998; 29:288.

Tomandl BF, Klotz E, Handschu R, et al. Comprehensive imaging of ischemic stroke with multisection CT. *Radiographics* 2003; 23:565–592.

von Kummer R, Allen KL, Holle R, et al. Acute stroke: usefulness of early CT findings before thrombolytic therapy. *Radiology* 1997; 205:327–333.

ADDRESS: Bryson Borg, MD, Department of Diagnostic Radiology, Hb6, The Cleveland Clinic Foundation, 9500 Euclid Avenue, Cleveland, OH 44195.