

Noninvasive diagnostic strategies for peripheral arterial disease

■ ABSTRACT

A variety of diagnostic methods for peripheral arterial disease (PAD) are available, each with strengths and limitations. The ankle-brachial index is a simple and useful screening tool for PAD that can be performed in the office setting. Segmental limb pressure examinations and pulse volume recordings aid in identifying the location of disease. Pulse volume recordings are especially useful, along with the ankle-brachial index, in assessing functional status during exercise. Duplex ultrasonography, magnetic resonance angiography, and computed tomographic angiography are helpful in providing anatomic detail and thus yield additional information for planning interventional therapy. Conventional angiography, the “gold standard” study for PAD diagnosis, is now usually pursued only once an intervention is planned.

Diagnostic testing for peripheral arterial disease (PAD) must be accurate, inexpensive, widely accessible, easy to perform, and preferably noninvasive.

A variety of noninvasive techniques are available to detect the presence of PAD as well as to localize areas of stenosis, assess severity of disease, and follow patients for disease progression or response to therapy. Several techniques can be performed in the outpatient office setting, facilitating rapid and accurate assessment of symptoms and offering an opportunity to screen asymptomatic individuals who are at risk for PAD. Once PAD has been diagnosed and there is interest in evaluating options for revascularization therapy, several imaging strategies exist. Recently, minimally invasive imaging techniques have offered excellent alternatives to contrast angiography, which

is now reserved for patients in whom an intervention is planned.

This article reviews and assesses various noninvasive methods for diagnosing and evaluating PAD.

■ THE ANKLE-BRACHIAL INDEX

The ankle-brachial index (ABI) is a simple and inexpensive test that can identify patients with PAD by determining the ratio of systolic blood pressure at the ankle arteries relative to that at the brachial arteries. This test (also occasionally called the arm-ankle index) requires a blood pressure cuff and a handheld continuous-wave 5- to 10-mHz Doppler probe.

Measurements for the ABI should be obtained after the patient has been supine for 5 to 10 minutes. The test requires that the systolic blood pressure be recorded in both brachial arteries and in both dorsalis pedis and posterior tibial arteries. The ABI is calculated for each leg by dividing the highest ankle systolic pressure by the highest brachial systolic pressure, recording the value to two decimal places. In general, the ankle pressure will exceed the brachial pressure by 10 to 15 mmHg in healthy individuals as a result of higher peripheral resistance at the ankles.¹

Interpreting the ABI

According to recently published practice guidelines for PAD management from the American College of Cardiology and the American Heart Association (ACC/AHA), ABI ratios are interpreted as follows¹:

- ≥ 1.30 : noncompressible vessel
- 1.00 to 1.29: normal
- 0.91 to 0.99: borderline (equivocal)
- 0.41 to 0.90: mild to moderate PAD
- 0.00 to 0.40: severe PAD.

An ABI of 0.90 or less has a sensitivity of 95% and a specificity of 100%, relative to contrast angiography, for detecting a stenotic lesion of at least 50% in the limb.²

Vessels are noncompressible when there is significant medial artery calcification. This finding is most commonly seen in some diabetic patients but may also be present in elderly individuals, patients with

* Dr. Begelman reported that she has no financial relationships that pose a potential conflict of interest with this article. Dr. Jaff reported that he has received honoraria for teaching and speaking from the Bristol-Myers Squibb/Sanofi Pharmaceuticals Partnership.

† At the time this article was written, Dr. Begelman was employed in the Department of Cardiovascular Medicine, Cleveland Clinic, Cleveland, OH.

chronic kidney disease who require dialysis, and patients receiving chronic steroid therapy.

An alternative: The toe-brachial index

The inability of the ABI to reliably detect PAD in the presence of noncompressible vessels is its primary limitation. A toe-brachial index may be a better test for assessing lower limb perfusion when the ABI is 1.30 or greater, because small arteries are less susceptible to calcification.³ To obtain a toe-brachial index, the systolic pressure is measured from the great toe using a small cuff and a Doppler probe, similar to an ABI. Normal toe pressures run lower than brachial and ankle pressures. Therefore, a toe-brachial index less than 0.70 is considered diagnostic of PAD.

ABI correlates with outcomes

Epidemiologic studies have shown an association between the ABI and cardiovascular morbidity and mortality as well as between the ABI and reduced limb function.

In a cohort study of 154 patients with an ABI less than 0.90, Sikkink et al⁴ reported the following 5-year cumulative survival rates, according to patients' resting ABIs:

- 63% for those with an ABI less than 0.50
- 71% for those with an ABI of 0.50 to 0.69
- 91% for those with an ABI of 0.70 to 0.89.

Resnick et al⁵ expanded on this association in a study of all-cause and cardiovascular mortality in patients with either low ABIs (< 0.90) or high ABIs (> 1.40). Adjusted risk estimates for all-cause mortality, relative to patients with an ABI of 0.90 to 1.40, were 1.69 for patients with low ABIs and 1.77 for those with high ABIs; estimates for cardiovascular mortality were 2.52 and 2.09, respectively. The researchers concluded that there is a U-shaped association between ABI and mortality risk.

In fact, this and other studies are changing the definition of a "normal" ABI. Wang et al⁶ showed that both low-normal ABIs (which they defined as 0.91 to 0.99) and high ABIs (≥ 1.40) were associated with higher rates of lower extremity symptoms than were normal ABIs (defined as 1.00 to 1.39 in this study). Similarly, McDermott et al⁷ found that an ABI of 0.90 to 0.99 was associated with a significantly higher prevalence of subclinical atherosclerosis (increased carotid intima-media thickness and coronary artery calcium assessed by computed tomography) when compared with a normal ABI (defined as 1.10 to 1.29) in both men and women. Historically, individuals whose ABI fell within the range of 0.90 to 0.99 have been categorized as "normal" in population-based studies.

Who should be screened with the ABI?

The recent ACC/AHA practice guidelines for PAD management¹ recommend that a resting ABI be obtained for the following patient groups:

- Individuals with suspected PAD due to exertional leg symptoms or nonhealing wounds
- Individuals aged 70 years or older
- Individuals between 50 and 70 years of age who have a history of tobacco use or diabetes mellitus.

Additionally, the American Diabetes Association suggests that a screening ABI be performed in patients with diabetes who are younger than 50 years and have additional risk factors for PAD, such as smoking, hypertension, hyperlipidemia, or diabetes of long duration (> 10 years).⁸

Although clinicians now overwhelmingly recognize the benefits of measuring the ABI, use of this test has been limited as a result of a lack of reimbursement by most health care payers and time constraints.⁹ A recent study suggests that automated oscillometry may be used for ABI measurements.¹⁰ If its accuracy can be substantiated, automated oscillometry may help overcome the time-constraint barrier by facilitating more rapid measurement.

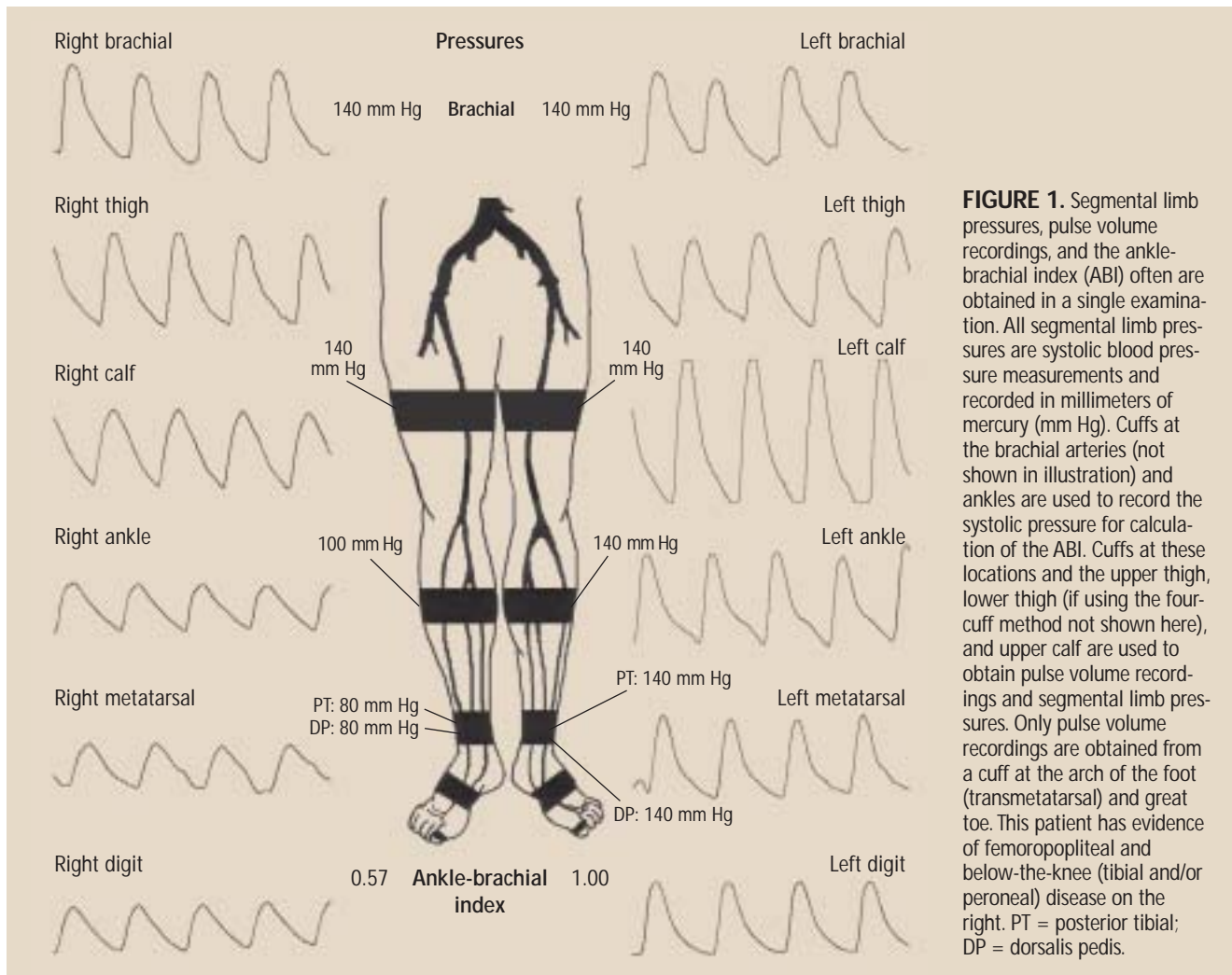
■ SEGMENTAL LIMB PRESSURE EXAMS AND PULSE VOLUME RECORDINGS

Segmental limb pressures. The location and extent of PAD can be further defined by segmental limb systolic pressure measurements, recorded with a Doppler instrument from plethysmographic cuffs placed over the brachial arteries and at various points on the lower limb, including the upper thigh, the lower thigh, the upper calf just below the knee, and the ankle (**Figure 1**). (Measurements at the lower thigh are omitted by vascular laboratories that use the three-cuff method.) Typically, a 20-mm Hg gradient between adjacent levels indicates underlying arterial stenosis. For example, segmental limb pressures of 120 mm Hg at the lower thigh and 100 mm Hg at the upper calf would suggest distal superficial femoral artery or popliteal artery disease.

Segmental limb pressure measurements have the same limitation as the ABI with regard to noncompressible vessels.

Although segmental limb pressures can be measured alone, they are more commonly obtained with pulse volume recordings; the combination of the two measures has a reported diagnostic accuracy of 97%.¹¹

Pulse volume recordings, or arterial waveforms, are obtained with a cuff system that incorporates a pneumoplethysmograph to detect volume changes in



the limb throughout the cardiac cycle. Changes in pulse contour and amplitude can be analyzed, providing additional information on the status of the underlying vessels.

A normal waveform has a steep upstroke, a sharp systolic peak, a narrow pulse width, a dicrotic notch, and a downslope bowing to the baseline¹² (Figure 2A). In the presence of arterial disease, the slope of the upstroke flattens, the peak becomes more rounded and has a wider pulse width, the dicrotic notch disappears, and the downslope bows away from the baseline (Figure 2B).

Valuable information about the status of small vessels can be obtained by wrapping a cuff around the arch of the foot or the first digit. Assessment of these vessels may help to further define the nature of the underlying disease (eg, differentiating an embolic event or small vessel vasculitis from large vessel ath-

erosclerosis) and gauge the potential for digital wound healing. Although pulse volume recordings are a subjective tool for evaluation, waveforms that are dampened or flat at the transmetatarsal or first-digit levels relative to the ankle level suggest small vessel disease.

It should be recognized that pulse volume recordings constitute a qualitative, not quantitative, study and may be less accurate than duplex ultrasonography for localizing a lesion.

■ EXERCISE STRESS TESTING

Exercise treadmill testing, combined with pre- and postexercise ABI measurements, can be used to determine whether a patient's lower extremity symptoms are due to PAD (claudication) or an alternate cause (pseudoclaudication) and to assess the functional status of a patient with PAD. It also is a good method of noninvasively detecting PAD when the

resting ABI is normal but there is a high clinical suspicion for arterial disease.

Performing the test: Look for a drop in ABI

Once a baseline ABI is obtained, the patient is placed on a treadmill using a constant speed and grade (often 2 mph at a 10% or 12% incline); variable-grade testing also can be used. The patient's leg symptoms, their intensity, and their location should be recorded at symptom onset, with changes during the examination, and at the time of maximal discomfort when the patient must stop walking. Any associated symptoms, such as shortness of breath, limb fatigue, or chest pain, also should be recorded. When the patient has walked until reaching maximal discomfort or a predefined end point (eg, 5 minutes), the ABI is remeasured at 1-minute intervals until the pre-exercise baseline is reached.¹ Because of time constraints, some vascular laboratories record only the 1-minute postexercise measurement.

Exercise produces significant peripheral vasodilatation; in the presence of arterial stenosis, this results in a significant blood pressure gradient. A normal individual will have no change or a slight increase in the ABI, whereas the ABI will drop in a patient with PAD.

A change in pulse volume recording morphology during exercise may be used to detect PAD in patients whose ABI cannot be calculated due to low pressures or vessel calcification.

Exercise treadmill tests should not be performed in patients with critical limb ischemia (ischemic rest pain or nonhealing ulcers/gangrene), significant musculoskeletal problems, or cardiopulmonary symptoms (unstable angina or shortness of breath).

Plantarflexion for physically limited patients

An alternative form of exercise testing, active pedal plantarflexion, correlates well with the more traditional treadmill technique.¹³ This may be the preferred method for patients with physical limitations that prevent them from walking on a treadmill or when access to a treadmill is limited. After an ABI is obtained, the patient stands flat-footed, often with his or her fingertips resting against a wall for balance. The patient is then encouraged to perform repeated ankle plantarflexions by raising the heels off the floor with knees fully extended. When the patient has completed the test, either by executing 50 repetitions or developing symptoms, the ABI is repeated.

■ DUPLEX ULTRASONOGRAPHY

Arterial duplex ultrasonographic examination of the

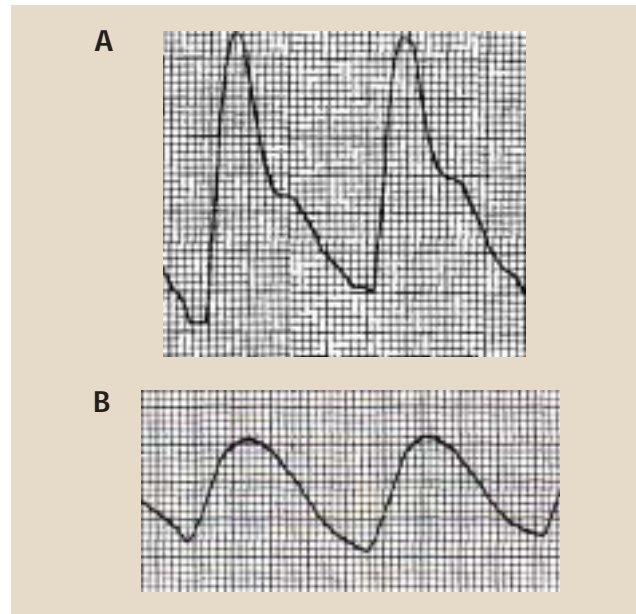


FIGURE 2. Pulse volume recordings showing a normal waveform in a healthy individual (A) and an abnormal waveform in a patient with peripheral arterial disease (B). In the presence of arterial disease, the slope flattens, the pulse width widens, and the diastolic notch is lost.

lower extremities can also be used to diagnose PAD. It is especially helpful in determining the location of disease and in delineating between stenotic and occlusive lesions, an added benefit when preparing for an intervention. Duplex ultrasonography combines Doppler waveform analysis and Doppler velocities.

A normal peripheral arterial Doppler waveform is triphasic (**Figure 3A**). Cardiac systole results in the initial forward flow, followed by a brief period of flow reversal in early diastole and subsequent forward flow in late diastole. The flow-reversal component, a result of high peripheral vascular resistance, is absent in the presence of hemodynamically significant stenosis (**Figure 3B**). Doppler waveform analysis can be used to identify other indicators of disease, including changes in pulsatility and the presence of turbulence.

Detecting and defining stenosis

The degree of stenosis is determined by a combination of waveform analysis and measurement of the peak systolic velocity. Five categories of stenosis have been described¹⁴:

- Normal (no stenosis)
- 1% to 19% stenosis, when flow disturbances result in changes in the waveform but not in the peak systolic velocity
- 20% to 49% stenosis, when the peak systolic velocity increases by 30% to 100% relative to

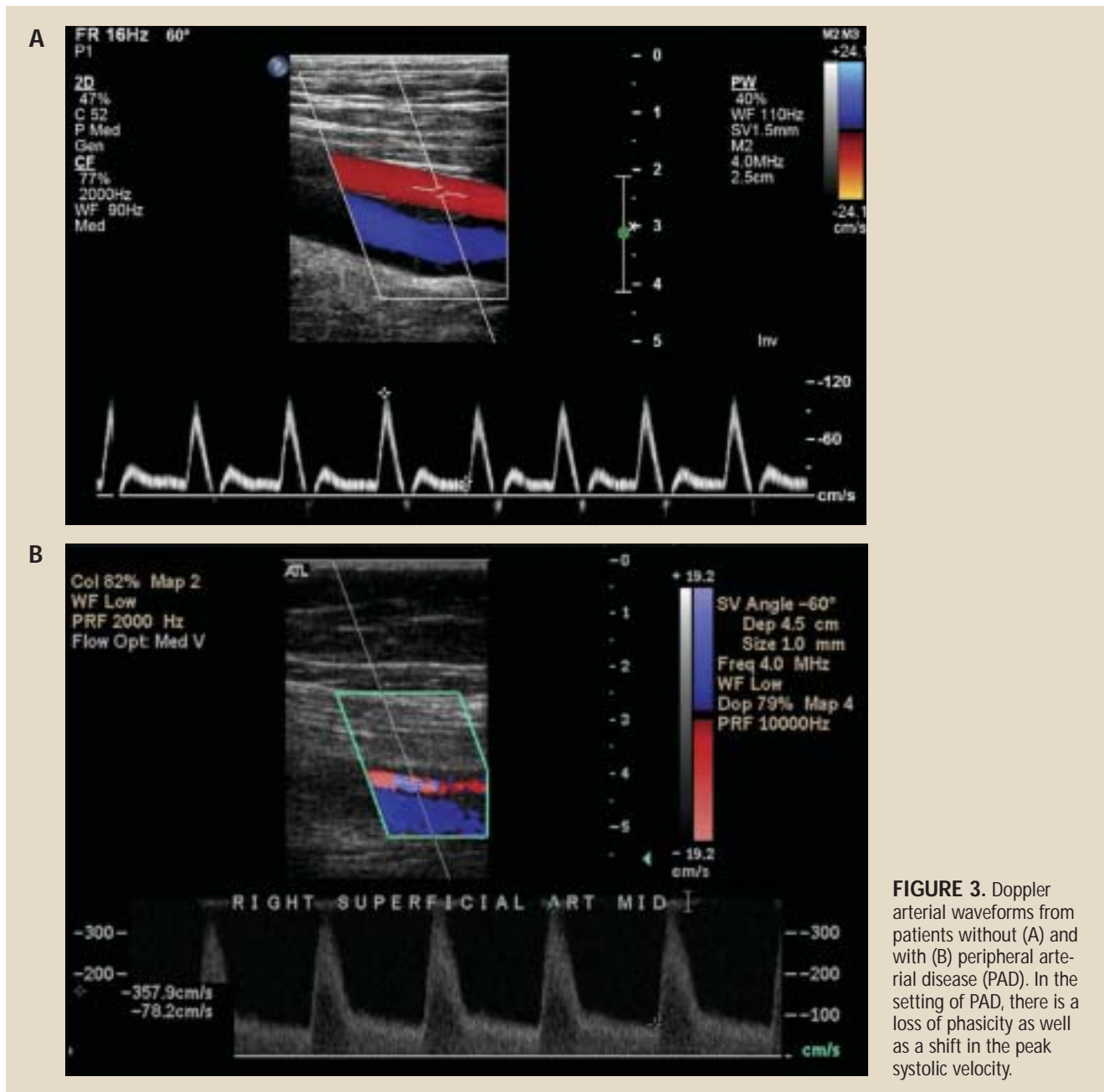


FIGURE 3. Doppler arterial waveforms from patients without (A) and with (B) peripheral arterial disease (PAD). In the setting of PAD, there is a loss of phasicity as well as a shift in the peak systolic velocity.

the proximal normal segment

- 50% to 99% stenosis, when the peak systolic velocity increases by greater than 100% relative to the proximal normal segment; typically there is a loss of flow reversal
- Occlusion, if no flow is identified in the artery.

Koelmay et al¹⁵ performed a meta-analysis of studies on the utility of duplex ultrasonography for detecting occlusion or a stenosis of 50% or greater. They found sensitivity and specificity rates of 86% and

97%, respectively, for the aortoiliac arteries; 80% and 96% for the femoropopliteal arteries; and 83% and 84% for the infragenicular arteries (tibial and peroneal vessels).

Duplex ultrasonography is widely accepted and recommended for postrevascularization surveillance of vein grafts despite mixed results in published studies of its clinical utility.¹ Although surveillance scans of synthetic grafts or arteries after angioplasty are often performed, their value remains questionable.

Despite accuracy, some limitations

Although duplex ultrasonography is an accurate non-invasive test for PAD, it requires technical expertise that may be lacking in many centers. Other limitations are its diminished accuracy in assessing the aortoiliac vessels due to body habitus and bowel gas, signal “dropout” in heavily calcified vessels, and reduced sensitivity for significant stenosis in the presence of multiple lesions within close proximity (tandem lesions).

■ MAGNETIC RESONANCE ANGIOGRAPHY

Magnetic resonance angiography (MRA) is a particularly useful imaging tool in PAD. It does not expose patients to ionizing radiation, and the recent advent of non-iodine-based intravenous contrast agents (with minimal risk of nephropathy or hypersensitivity) offers advantages in evaluating revascularization options for patients.

Modern MR scanners make possible the prompt acquisition of images for analyzing the arterial tree from the suprarenal abdominal aorta to the distal calves (**Figure 4**). Impressive images of pedal arteries can also be obtained, although these often require separate “staging” to obtain maximal vessel resolution.

Documented utility in guiding revascularization

Early experience comparing contrast-enhanced MRA with duplex ultrasonography showed MRA to be impressively accurate in planning peripheral arterial revascularization. A retrospective series of 100 patients who underwent both imaging methods found that MRA was more effective than duplex ultrasonography in planning revascularization.¹⁶ A recent prospective study compared pre-intervention duplex ultrasonography with contrast MRA in 295 patients, including 152 who also underwent contrast angiography as a reference standard.¹⁷ Results for detecting significant stenosis were as follows:

- Sensitivity: 76% with ultrasonography vs 84% with MRA
- Specificity: 93% with ultrasonography vs 97% with MRA
- Accuracy: 89% with ultrasonography vs 94% with MRA.

The differences in sensitivity and specificity were statistically significant in favor of MRA.¹⁷

The ACC/AHA guidelines on PAD suggest that MRA may be useful in determining the location and severity of stenosis and may aid in decisions between endovascular and surgical revascularization.¹

Patient-related and technological limitations

The limits of MRA center on patient factors and technology issues.

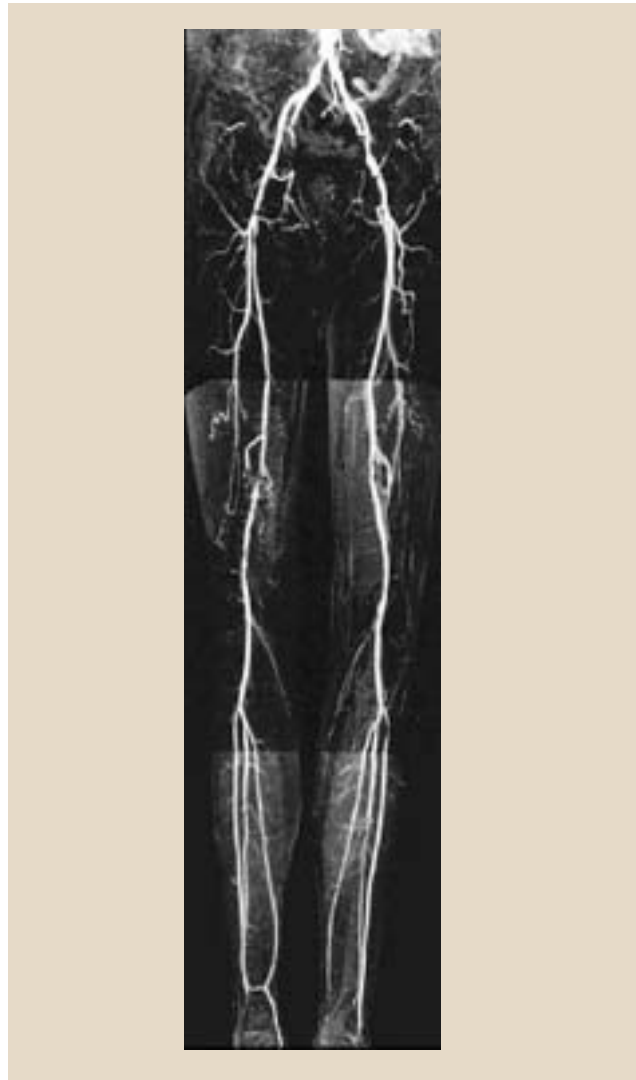

FIGURE 4. A gadolinium-enhanced magnetic resonance angiogram demonstrating excellent visualization from the suprarenal aorta to the ankles bilaterally. Note moderate bilateral external iliac artery disease.

Patients with implantable defibrillators and permanent pacemakers may not undergo MR studies, for fear of causing these devices to malfunction. Patients with intracranial aneurysm clips also are deemed to be at high risk if exposed to the magnetic environment. Claustrophobia also is a major issue, preventing approximately 10% of patients from completing MR studies.

From a technology standpoint, MR often has classified moderate stenoses as severe, and severe stenoses as occlusions. This tendency to overestimate the extent of stenosis may be avoided by close post-processing of images (using equipment enhancement techniques after the images have been obtained) and by improved

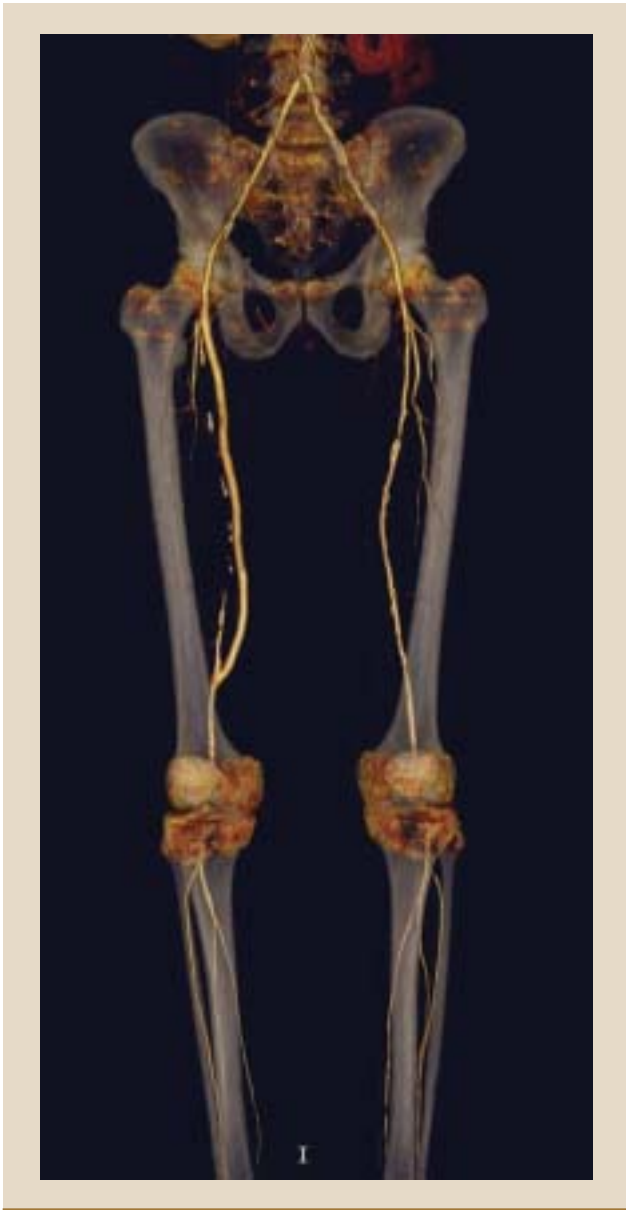

FIGURE 5. Computed tomographic angiogram showing a patent right femoropopliteal artery bypass graft and focal stenosis of the left superficial femoral artery.

timing of contrast agent administration. In addition, MRA cannot reliably detect arterial calcification, which is a potential limitation when revascularization options are being considered. Finally, the metal alloys used in current endovascular stents result in signal dropout, which precludes imaging of the in-stent segments, although MRA can reliably determine the presence of flow proximal and distal to the stent. With newer alloys, imaging within stents using MRA may become a reality.

■ COMPUTED TOMOGRAPHIC ANGIOGRAPHY

The use of computed tomographic angiography (CTA) as a diagnostic method in PAD is relatively recent, prompted by improvements in image resolution and scan times with the advent of 64-channel “multidetector” scanners. Rapid sequence acquisition provides detailed images from the suprarenal abdominal aorta to the ankles (**Figure 5**). In contrast to MRA, CTA visualizes calcification well, which is advantageous when considering revascularization strategies.

Promising data emerging

A recent comparative study of 25 patients who underwent CTA and contrast angiography of the lower extremity arteries found CTA to have the following detection rates for various degrees of stenosis:¹⁸

- 86% sensitivity and 90% specificity for stenosis of less than 50%
- 79% sensitivity and 89% specificity for 50% to 99% stenosis
- 85% sensitivity and 98% specificity for occlusion.

Early experience with multidetector CTA for evaluating peripheral arterial bypass grafts has been reported. Willmann et al¹⁹ evaluated 85 bypass grafts in 65 patients by both duplex ultrasonography and four-channel CTA, finding each method to have excellent and comparable sensitivity and specificity for graft stenosis and other measures.

Evaluation of peripheral arterial stents can be performed with CTA, as there is no signal dropout during CTA scanning. However, the true degree of in-stent stenosis cannot be adequately quantified with current technology and scanning algorithms. The use of CTA has recently been evaluated in carotid artery stents,²⁰ suggesting utility in assessing post-carotid stent restenosis. However, no data are yet available on CTA for evaluating the patency of peripheral arterial stents.

The ACC/AHA guidelines on PAD suggest that CTA may be useful in planning revascularization strategies, offering faster image acquisition capabilities than MRA.¹

Limitations from iodine-based contrast media

Because of the need for large volumes of iodinated contrast media administered via a peripheral intravenous cannula, CTA cannot be performed in patients with azotemia or in individuals at increased risk of contrast-induced acute tubular necrosis. In addition, repetitive CTA studies are not recommended, as they would result in patients receiving considerable doses of ionizing radiation.

■ CONTRAST ANGIOGRAPHY

Contrast angiography, the “gold standard” for the diagnosis of PAD,¹ is rarely required as a diagnostic tool. It is now reserved for patients with PAD who are being considered for endovascular or surgical revascularization, owing to the risks associated with an invasive procedure. Multiple studies suggest that contrast-enhanced MRA obviates the need for contrast angiography in most cases.²¹ Similar data are emerging with CTA.²²

■ GUIDANCE FOR CHOOSING AMONG DIAGNOSTIC OPTIONS

As detailed above, there are several options for the non-invasive detection and assessment of underlying PAD, each with its advantages and limitations. The preferred test depends on the indication for the study and, at least for imaging methods, the available technology and the available expertise in image acquisition and interpretation. For instance, duplex ultrasonography requires the skill of an experienced vascular technologist, specific-

ly for assessment of aortoiliac segments.

Patient factors also play a significant role. For example, a patient with critical limb ischemia and azotemia is a suboptimal candidate for CTA because of the iodinated contrast media required. A similar patient with an implantable defibrillator is not a candidate for MRA.

The ACC/AHA practice guidelines on PAD¹ recommend the following options for the clinical indications outlined:

- **Asymptomatic PAD—ABI**
- **Symptomatic PAD—ABI**; pulse volume recordings and/or segmental limb pressure examination; duplex ultrasonography; or ABI with exercise stress testing to assess functional status
- **Possible pseudoclaudication—ABI with exercise**
- **Candidate for revascularization—duplex ultrasonography, MRA, or CTA.**

For most patients, conventional contrast angiography should be performed only if an intervention or surgery is planned.

■ REFERENCES

1. Hirsch AT, Haskal ZJ, Hertzler NR, et al. ACC/AHA 2005 guidelines for the management of patients with peripheral arterial disease (lower extremity, renal, mesenteric, and abdominal aortic): executive summary. *J Am Coll Cardiol* 2006; 47:1239–1312.
2. Management of peripheral arterial disease (PAD). TASC Working Group. TransAtlantic Inter-Society Consensus (TASC). *J Vasc Surg* 2000; 31(Suppl):S5–S34.
3. Brooks B, Dean R, Patel S, Wu B, Molyneaux L, Yue DK. TBI or not TBI: that is the question. Is it better to measure toe pressure than ankle pressure in diabetic patients? *Diabet Med* 2001; 18:528–532.
4. Sikkink CJ, van Asten WN, van't Hof MA, van Langen H, van der Vliet JA. Decreased ankle/brachial indices in relation to morbidity and mortality in patients with peripheral arterial disease. *Vasc Med* 1997; 2:169–173.
5. Resnick HE, Lindsay RS, McDermott MM, et al. Relationship of high and low ankle brachial index to all-cause and cardiovascular disease mortality: the Strong Heart Study. *Circulation* 2004; 109:733–739.
6. Wang JC, Criqui MH, Denenberg JO, McDermott MM, Golomb BA, Fronck A. Exertional leg pain in patients with and without peripheral arterial disease. *Circulation* 2005; 112:3501–3508.
7. McDermott MM, Liu K, Criqui MH, et al. Ankle-brachial index and subclinical cardiac and carotid disease: the Multi-Ethnic Study of Atherosclerosis. *Am J Epidemiol* 2005; 162:33–41.
8. American Diabetes Association. Peripheral arterial disease in people with diabetes. *Diabetes Care* 2003; 26:3333–3341.
9. Mohler ER 3rd, Treat-Jacobson D, Reilly MP, et al. Utility and barriers to performance of the ankle-brachial index in primary care practice. *Vasc Med* 2004; 9:253–260.
10. Beckman JA, Higgins CO, Gerhard-Herman M. Automated oscillometric determination of the ankle-brachial index provides accuracy necessary for office practice. *Hypertension* 2006; 47:35–38.
11. Rutherford RB, Lowenstein DH, Klein MF. Combining segmental systolic pressures and plethysmography to diagnose arterial occlusive disease of the legs. *Am J Surg* 1979; 138:211–218.
12. Darling RC, Raines JK, Brener BJ, et al. Quantitative segmental pulse volume recorder: a clinical tool. *Surgery* 1972; 72:873–877.
13. McPhail IR, Spittell PC, Weston SA, Bailey KR. Intermittent claudication: an objective office-based assessment. *J Am Coll Cardiol* 2001; 37:1381–1385.
14. Strandness DE Jr. Peripheral arterial system. In: Strandness DE Jr, ed. *Duplex Scanning in Vascular Disorders*. 3rd ed. Philadelphia, PA: Lippincott Williams & Wilkins; 2002:118–143.
15. Koelemay MJ, den Hartog D, Prins MH, Kromhout JG, Legemate DA, Jacobs MJ. Diagnosis of arterial disease of the lower extremities with duplex ultrasonography. *Br J Surg* 1996; 83:404–409.
16. Leiner T, Tordoir JH, Kessels AG, et al. Comparison of treatment plans for peripheral arterial disease made with multi-station contrast medium-enhanced magnetic resonance angiography and duplex ultrasound scanning. *J Vasc Surg* 2003; 37:1255–1262.
17. Leiner T, Kessels AG, Nelemans PJ, et al. Peripheral arterial disease: comparison of color duplex US and contrast-enhanced MR angiography for diagnosis. *Radiology* 2005; 235:699–708.
18. Bui TD, Gelfand D, Whipple S, et al. Comparison of CT and catheter arteriography for evaluation of peripheral arterial disease. *Vasc Endovascular Surg* 2005; 39:481–490.
19. Willmann JK, Mayer D, Banyai M, et al. Evaluation of peripheral arterial bypass grafts with multi-detector row CT angiography: comparison with duplex US and digital subtraction angiography. *Radiology* 2003; 229:465–474.
20. Goldman CK, Morshedi-Meibodi A, White CJ, Jaff MR. Surveillance imaging for carotid in-stent restenosis. *Catheter Cardiovasc Intervent* 2006; 67:302–308.
21. Koelemay MJ, Lijmer JG, Stoker J, Legemate DA, Bossuyt PM. Magnetic resonance angiography for the evaluation of lower extremity arterial disease: a meta-analysis. *JAMA* 2001; 285:1338–1345.
22. Kock MC, Adriaensen ME, Pattinama PM, et al. DSA versus multi-detector row CT angiography in peripheral arterial disease: randomized controlled trial. *Radiology* 2005; 237:727–737.

Address: Susan M. Begelman, MD, FACC, Associate Director, Clinical Sciences/Cardiovascular, Nuvelo, Inc., 201 Industrial Road, Suite 310, San Carlos, CA 94070-6211; sbegelman@nuvelo.com.