

AMJAD ALMAHAMEED, MD, MPH, FACP\*†

Division of Cardiology  
Harvard Medical School and Beth Israel Deaconess Medical Center  
Boston, MA

DEEPAK L. BHATT, MD, FACC, FSCAI, FESC, FACP\*

Department of Cardiovascular Medicine  
Cleveland Clinic  
Cleveland, OH

## Contemporary management of peripheral arterial disease: III. Endovascular and surgical management

### ■ ABSTRACT

Traditional indications for invasive treatment in patients with peripheral arterial disease (PAD) have been salvage of a threatened limb or improvement of functional capacity in cases of disabling intermittent claudication, but advances in interventional therapy may be lowering the threshold for these therapies. Percutaneous transluminal angioplasty (PTA), with or without stent placement, is the most common endovascular intervention in patients with occlusive lower extremity PAD. In general, PTA is best suited to cases of short-segment stenosis or large-bore vessels, whereas surgery is best applied to multilevel occlusions involving smaller and more distant vessels. This article reviews endovascular therapy, catheter-based thrombolysis, and surgical revascularization procedures in patients with PAD, with special attention to recommendations from new American College of Cardiology/American Heart Association guidelines.

**T**he classic indications for invasive (endovascular or surgical) treatment in patients with lower extremity peripheral arterial disease (PAD) are salvage of a threatened limb (usually presenting as rest pain, nonhealing ulceration, or gangrene) and improvement of functional capacity in patients with short-distance, lifestyle- or vocation-limiting intermittent claudication (IC). Several considerations must be taken into account before a patient with IC is offered the option of any invasive revascularization therapy (**Tables 1 and 2**).<sup>1,2</sup>

Recent advances in the management of vascular disease, combined with the evolution of experienced vascular interventionalists and the increasingly multidisciplinary approach to peripheral interventions, have

improved the risk-benefit ratio of percutaneous revascularization procedures. This shift, along with current understanding of the elusive symptomatology of PAD and its alarming effects on functional status (beyond those of IC), may have lowered the threshold for invasive therapy of lower extremity arterial occlusive disease. This article reviews current understanding of when and how patients with lower extremity PAD are best managed with revascularization therapies, with the recognition that more clinical trials are needed to further examine these strategies and test newer devices.

### ■ ENDOVASCULAR INTERVENTIONS

#### Explosive—and continuing—growth

Since Dotter and Judkins first described percutaneous catheter-based angioplasty for the treatment of symptomatic PAD in 1964,<sup>3</sup> peripheral interventional procedures have proliferated. The use of angioplasty to treat lower extremity disease increased sevenfold in the United States between 1979 and 1996.<sup>4</sup> In some regions the growth has been even more explosive. For example, the annual rate of percutaneous transluminal angioplasty (PTA) for lower extremity PAD, adjusted for age and sex, rose 24-fold (from 1 to 24 per 100,000 residents) in Maryland from 1979 to 1989.<sup>5</sup> More recent estimates suggest that this proliferation continues, with the number of peripheral interventions increasing from 90,000 in 1994 to more than 200,000 in 1997, making endovascular intervention the fastest growing therapeutic area of vascular medicine.<sup>6</sup> While this growth rate already exceeds the growth rate of coronary interventional procedures, this growth is expected to continue as endovascular techniques become applicable to many peripheral arterial conditions that traditionally have been managed surgically.

The most commonly used percutaneous strategy for the treatment of infrainguinal occlusive disease is PTA with or without stent placement. Other strategies, such as subintimal angioplasty, cutting-balloon angioplasty, cryoplasty, and the use of atherectomy devices (eg, laser and thermal devices), are also employed and considered valuable in subgroups of patients. Newer techniques, such as the use of drug-

\* Dr. AlMahameed reported that he has received honoraria for teaching and speaking from Sanofi-Aventis, GlaxoSmithKline, and Pfizer. Dr. Bhatt reported that he has received honoraria for teaching, speaking, and consulting from Sanofi-Aventis and from Bristol-Myers Squibb.

† At the time this article was written, Dr. AlMahameed was on the staff of the Department of Cardiovascular Medicine, Cleveland Clinic, Cleveland, OH.

**TABLE 1**  
**Indications for revascularization in patients with intermittent claudication (IC)**

Before a patient with IC is offered the option of any invasive revascularization therapy, either endovascular or surgical, the following considerations must be taken into account:

- Whether patient has a predicted or observed lack of adequate response to exercise therapy and IC pharmacotherapies
- Whether patient has severe disability, ie, is unable to perform normal work or has very serious impairment of other activities important to him/her
- Whether patient has another disease that would limit exercise even if IC were improved (eg, angina or chronic respiratory disease)
- Whether patient's anticipated natural history and prognosis justify the intervention
- Whether morphology of the lesion is such that the appropriate intervention would have low risk and a high probability of initial and long-term success

Adapted from reference 1.

eluting or biodegradable stents, are considered investigational at present.

Generally, endovascular therapy of PAD is associated with a low rate of serious adverse outcomes in most patients. However, contrast-induced acute renal failure, contrast-related allergic reactions, atheromatous (renal and lower extremity) embolization, and access-related complications such as pseudoaneurysm, arteriovenous fistula, bleeding, and hematoma can all be seen.<sup>2</sup>

**What determines indications and outcomes?**

In light of differences in structural and anatomic characteristics, the lower extremity arterial system can be divided into three distinct anatomic territories:

- Aortoiliac
- Femoropopliteal
- Infrapopliteal (also referred to as crural, below-the-knee, infrageniculate, or tibioperoneal).

The indications and outcomes of endovascular procedures differ depending on the segment involved as well as other systemic factors (see discussion of these factors in following paragraph). In general, optimal PTA results are achieved when the procedure is offered for short-segment stenosis of large-bore vessels, whereas surgical methods are best applied to multilevel occlusions involving smaller and more distant vessels. Proposed patient-specific predictors of long-term patency following percutaneous therapy include the following:<sup>7-9</sup>

- **Lesion severity at baseline** (fewer, concentric, noncalcific, and stenotic lesions, as opposed to heavily calcific and occluded arterial segments)
- **Anatomy of the affected limb** (greater baseline inflow and presence of two- or three-vessel runoff)
- **The limb's physiologic adaptation to ischemia, as manifested by clinical presentation** (claudication as the presenting symptom rather than critical or acute limb ischemia)
- **Angiographic response of the limb to intervention** (absence of residual stenosis following angioplasty)
- **Physiologic response of the lesion to intervention** (normalization of the ankle-brachial index to > 0.90 at 24 hours after the procedure).

Systemic factors, such as ongoing smoking, the presence of diabetes mellitus,<sup>9</sup> and optimal control of other atherosclerotic risk factors such as hyperlipidemia, hypertension, obesity, and a sedentary lifestyle play a fundamental role in the long-term fate of the arterial segment that is the target of the intervention (Table 3).

**Endovascular therapy of iliac artery disease**

The iliac arteries are most amenable to endovascular therapy and, if disease is present, require intervention first. Successful iliac artery angioplasty improves the inflow and augments collateral blood flow, thus leading to more durable results even when other segments are affected in the same leg. Available PTA techniques have shown an impressive 88% success rate for recanalization of occluded common or external iliac arteries,<sup>10,11</sup> with a 5-year cumulative patency rate as high as 66%.<sup>12</sup> A meta-analysis of six PTA studies and eight stent studies showed a higher initial success rate and an overall 39% reduction in long-term failures (after 4 years) with iliac stents compared with PTA alone, regardless of the indication for the procedure (claudication vs critical limb ischemia) or the type of underlying lesion (stenotic vs occlusive).<sup>13</sup>

Despite the clinical benefits of iliac stent placement as demonstrated by this meta-analysis,<sup>13</sup> many endovascular specialists favor selective stent use for distinctly complex lesions, for those with flow-limiting dissections, or when PTA results are unsatisfactory. Recently published guidelines from the American College of Cardiology and the American Heart Association (ACC/AHA) for the management of PAD give a class IB recommendation for PTA as primary therapy for common and/or external iliac artery stenoses and occlusions and a class I recommendation for stenting as primary therapy for such lesions (evidence level B for common lesions and level C for external lesions) (Table 2).<sup>2</sup>

**TABLE 2**  
Key ACC/AHA recommendations on revascularization therapy for lower extremity peripheral arterial disease\*

Presentation/indication	Class	Evidence level	Recommendations
Intermittent claudication (IC)	I	A	Endovascular procedures are indicated for patients with vocation- or lifestyle-limiting IC who have shown inadequate response to exercise or pharmacotherapy and have a favorable lesion profile (eg, focal aortoiliac occlusive disease)
		B	Endovascular procedures are the preferred therapy for TASC type A iliac and femoropopliteal lesions
		B	Primary stenting is the preferred therapy for common iliac artery stenoses and occlusions
		B	Provisional stenting is indicated as salvage therapy following a suboptimal result from iliac artery balloon dilation
		C	Stenting is effective as primary therapy for external iliac artery stenoses and occlusions
		C	Translesional pressure gradients should be obtained to evaluate borderline (50% to 75%) angiographic iliac arterial stenoses before intervention
Critical limb ischemia (CLI)	I	B	Inflow lesions should be addressed first
		B	An outflow revascularization procedure should be performed only if symptoms of CLI or infection persist despite inflow revascularization
Acute limb ischemia (ALI)	I	A	Catheter-based thrombolysis is recommended for patients with ALI (Rutherford categories I and IIa <sup>†</sup> ) of less than 14 days' duration
		B	Patients with a salvageable extremity should undergo emergent anatomic evaluation for revascularization
	IIa	B	Mechanical thrombectomy devices can be used as adjunctive therapy for ALI due to peripheral arterial occlusion
	IIb	B	Catheter-based thrombolysis or thrombectomy may be considered for patients with ALI (Rutherford category IIb <sup>†</sup> ) of more than 14 days' duration
	III	B	Patients with a nonviable extremity should not undergo evaluation or attempts at revascularization

\* Adapted from reference 2. Strength of recommendations is greatest for class I, then class II, etc. Evidence base is strongest for level A, then level B, etc. See reference 2 for full details.

<sup>†</sup> See table on page S19 of this supplement for explanation of Rutherford categories.

ACC/AHA = American College of Cardiology/American Heart Association; TASC = TransAtlantic Inter-Society Consensus

Furthermore, iliac artery endovascular therapy serves as an excellent adjunctive procedure for preserving inflow to surgical bypass grafts in patients with coexistent infrainguinal disease. In a study of 70 consecutive patients undergoing femorofemoral bypass grafting, iliac PTA (with and without stenting) provided adequate inflow to the graft for more than

14 years after the procedure, providing an alternative to aortofemoral bypass surgery.<sup>14</sup>

Relative contraindications to endovascular therapy of occlusive iliac disease include long occlusions (> 5 cm), iliac artery aneurysmal disease, atheroembolic disease, and long-segment, severe diffuse bilateral aortoiliac disease.<sup>15</sup>

**TABLE 3**  
Factors that increase risk of limb loss in patients with critical limb ischemia

Permission not granted to reprint this table online.

Please see original source table from ACC/AHA 2005 Practice Guidelines for the Management of Patients with Peripheral Arterial Disease. *Circulation* 2006; 113:463–654. © 2006, American Heart Association, Inc.

### Endovascular therapy of femoropopliteal disease

Atherosclerotic involvement of the femoropopliteal segment is the most common cause of IC.<sup>16</sup> Whereas stenotic lesions are more common in the iliac arteries, occlusions (typically long segments) are far more prevalent in the femoropopliteal system (**Figure 1**). In addition to being smaller than the iliac arteries, the femoropopliteal arteries have higher resistance, are more susceptible to spasm, and have lower overall blood flow rates. These factors, combined with the numerous external forces exerted on this segment (extension/contraction, torsion, compression, and flexion) and the impact of inflow and outflow status on procedural outcome, explain the higher rate of restenosis (more than 50% to 80% in some reports) following femoropopliteal PTA.<sup>16</sup> Although primary stent placement in this territory does not seem to significantly improve late patency rates (likely due to a high incidence of in-stent restenosis), such a strategy actually appears costly, increasing initial treatment costs by as much as \$3,000 relative to primary PTA.<sup>17</sup>

Given these findings, the recent ACC/AHA guidelines on PAD management recommend against primary stent placement in the femoral, popliteal, or tibial arteries (**Table 2**).<sup>2</sup> Provisional stent use (in which stent placement is limited to cases of suboptimal PTA results or cases of vessel recoil) remains an acceptable alternative.

### Endovascular therapy of infrapopliteal disease

Although described in the early work of Dotter and Judkins,<sup>3</sup> use of infrapopliteal (tibioperoneal trunk, anterior tibial, posterior tibial, and peroneal arteries) endovascular therapy has been far more limited. Infrapopliteal PTA (with and without stenting) is primarily offered to patients who present with critical limb ischemia or debilitating short-distance IC (walking distance < 200 m) who are not candidates for surgical revascularization. Infrapopliteal PTA is also used to complement proximal revascularization procedures, such as femoropopliteal PTA or bypass surgery, particularly when poor outflow threatens the long-term patency of the proximal segment. Although balloon-expandable coronary stents are the only available option for use in the infrapopliteal vasculature, dedicated and vessel-specific drug-eluting and biodegradable stents are being tested for use in this territory.

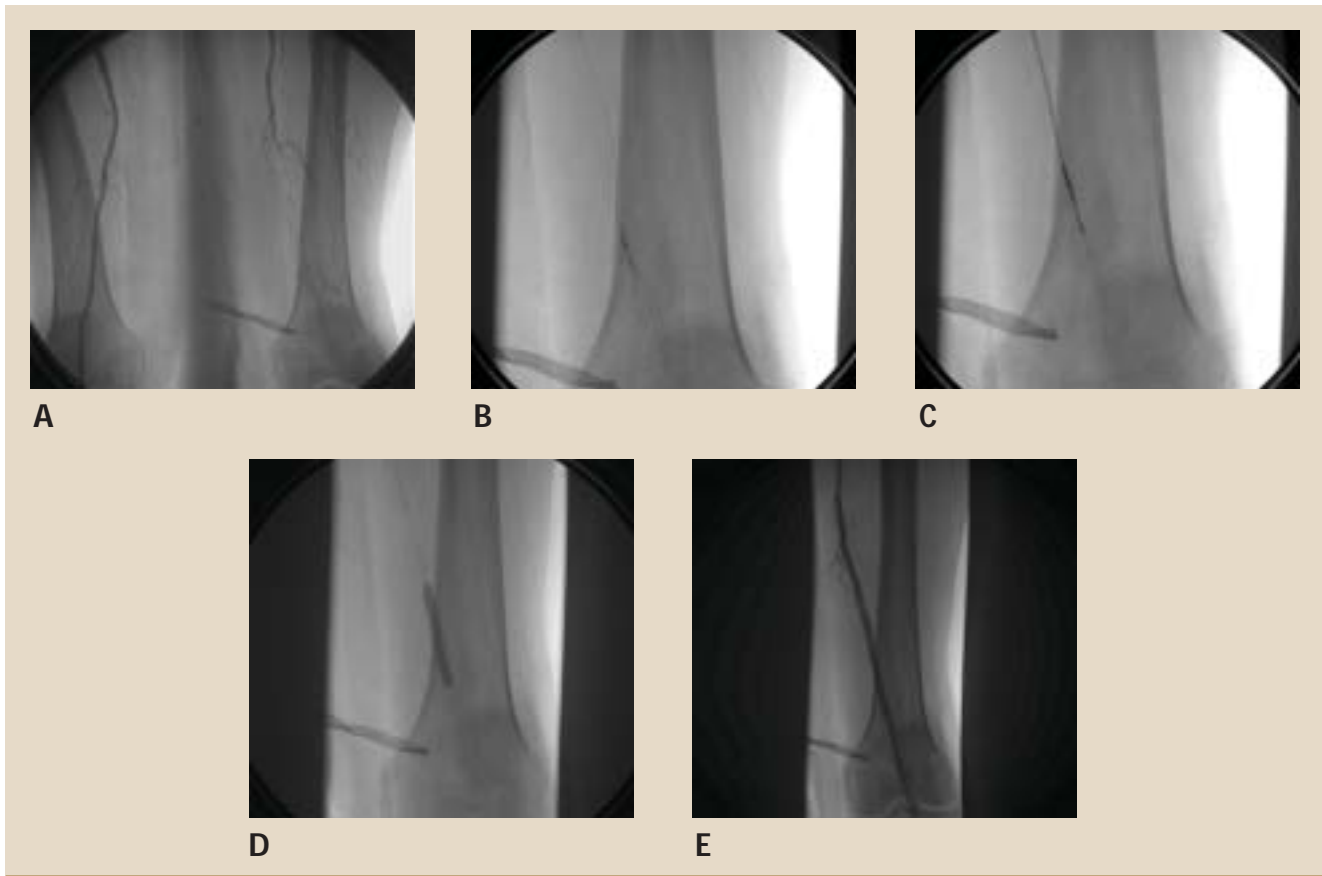
While the decision to intervene is typically based on the specifics of the individual patient, the following principles are noteworthy to help guide the practice of infrapopliteal PTA:

- Proximal lesions (aortoiliac or femoropopliteal) should always be fixed first when possible
- Surgical bypass grafting is an excellent initial treatment for critical limb ischemia when severe multilevel (including crural) disease is present, and must be pursued whenever possible
- Despite the high incidence of restenosis, temporarily restoring flow to one infrapopliteal artery allows delivery of sufficient nutrients to heal ischemic ulcers and, occasionally, ease rest pain symptoms
- IC alone is rarely a qualifying indication for infrapopliteal PTA except in special situations.

### ■ CATHETER-BASED THROMBOLYSIS

Thrombolytic therapy may lead to total or partial resolution of arterial thrombus in patients presenting with acute limb ischemia. Such rapid restoration of flow to the ischemic limb enhances long-term patency and frequently uncovers underlying stenotic lesions that may be amenable to simultaneous revascularization using endovascular techniques.

Three randomized, controlled, multicenter trials that compared thrombolysis to open surgical revascularization supported a role for catheter-based thrombolysis and underscored the importance of careful patient selection as a critical step in avoiding hemorrhagic complications.<sup>18–20</sup> The incidence of such complications in one review ranged from 1% for hemorrhagic stroke to 5% for major hemorrhage and 15% for minor hemorrhage.<sup>21</sup>



**FIGURE 1.** Percutaneous recanalization of an occluded left superficial femoral artery (SFA) in a patient with severe, lifestyle-limiting intermittent claudication. The resting ankle-brachial index on the left side was 0.64, which dropped to 0.43 with exercise. Angiography (A) showed a completely occluded long segment of the left SFA. The wire was purposefully passed into the subintimal part of the vessel (B). A Pioneer™ catheter (Medtronic, Minneapolis, MN) was placed in the subintimal space over the wire (C) and, with intravascular ultrasonographic guidance, the true lumen of the distal SFA was entered with a needle and a second wire was passed through that. Balloon angioplasty was performed with a 5 mm x 40 mm balloon (D), and overlapping 7 mm x 120 mm and 7 mm x 40 mm nitinol self-expanding stents were placed (E), producing an excellent angiographic result. Historically, this sort of lesion was treated conservatively or, if the symptoms were disabling, with open surgery. With current endovascular technology, percutaneous revascularization is often possible.

The ACC/AHA guidelines on PAD recommend catheter-based thrombolysis as an effective and beneficial initial treatment for acute limb ischemia<sup>2</sup> (Rutherford categories I and IIa, ie, patients in whom the limb is not immediately threatened or is salvageable if promptly treated; see previous article by Lyden and Joseph), and it is commonly used for treatment of bypass graft thrombosis.

#### ■ SURGICAL REVASCULARIZATION PROCEDURES

Surgical revascularization of occlusive PAD has been the conventional strategy for lower extremity revascularization since placement of the first synthetic vascular bypass graft in 1952.<sup>22</sup> The two surgical techniques commonly offered are bypass grafting and endarterectomy. While bypass grafting is favored in cases of distal, multi-

level, or diffuse occlusive disease, endarterectomy is an excellent option for lesions localized to the aortoiliac, common femoral, or profunda arteries. Dual procedures, using both endarterectomy (of diseased proximal segments) and bypass grafting (of occluded distal vessel), are occasionally offered to severely affected patients.

Autogenous vein grafts (using the patient's own veins) are preferred for infrainguinal bypass grafting, whereas synthetic grafts have shown excellent patency rates when used for aortofemoral bypass grafting.<sup>23</sup> The saphenous vein grafts are the most commonly used autologous grafts, but the cephalic and basilic veins can also be used if needed. Reversed vein grafts are created by disconnecting, reversing (so that forward blood flow is not obstructed by the vein valves), and reconnecting the autologous vein to bypass the dis-

eased arterial segment. In situ vein grafts are formed by leaving the native vein in place, disrupting the vein valves using a surgical instrument (to prevent blood flow impediment), and ligating the perforator veins to avert the formation of arteriovenous fistulas. An apparent mismatch in the size of the reversed vein graft and the native artery (usually at the distal anastomotic site) is not uncommon with in situ vein grafts. It can lead to increased Doppler velocities, which may be interpreted as graft anastomotic stenosis. This is an important distinction that all physicians caring for these patients need to be aware of to avoid misinterpretation of future graft duplex testing.

When distal bypass grafting is the procedure of choice, the surgeon should make every attempt to use a native vein, given the superior long-term patency of native veins (70% to 80% at 5 years) compared with prosthetic grafts of the infrapopliteal vessels.<sup>24-27</sup>

#### ■ PERIOPERATIVE AND LONG-TERM CARE OF THE VASCULAR SURGERY PATIENT

Patients undergoing noncardiac vascular surgery are at high risk for serious perioperative complications such as cardiac death, nonfatal myocardial infarction, stroke, wound or graft infection, atheroembolization, and peripheral nerve injury.

Although preoperative cardiovascular risk stratification should be emphasized, recent data suggest that preoperative coronary revascularization in this population is not always justified. The Coronary Artery Revascularization Prophylaxis (CARP) trial explored this issue in 510 patients with known, stable coronary artery disease who were scheduled for elective peripheral vascular surgery (33% for abdominal aortic aneurysm repair and 67% for infrainguinal bypass).<sup>28</sup> The patients were randomized to coronary artery revascularization (coronary artery bypass grafting in 41% and percutaneous coronary intervention in 59%) or no revascularization before the planned surgery. Outcomes were similar between the groups in terms of postoperative mortality and acute myocardial infarction at 30 days, left ventricular ejection fraction at 3 months, and survival after a median follow-up of 2.7 years. Furthermore, undergoing coronary revascularization delayed vascular surgery significantly, with a median interval of 54 days between randomization and vascular surgery in the coronary revascularization group compared with 18 days in the control group.

The authors concluded that coronary revascularization before elective vascular surgery is not indicated for patients with stable cardiac symptoms.<sup>28</sup> Elective preoperative cardiac catheterization before elective

vascular surgery, however, should be pursued when a preoperative evaluation suggests unstable cardiac symptoms or advanced cardiac disease (such as severe left main or three-vessel coronary artery disease [CAD], multivessel CAD with severe left ventricular dysfunction, or severe aortic stenosis).

#### Benefits from perioperative beta-blockers, statins

Perioperative use of beta-blockers significantly reduces the risk of cardiovascular events and mortality associated with noncardiac vascular surgery and improves the patency of autogenous infrainguinal bypass grafts.<sup>29,30</sup>

Benefits from perioperative statin therapy in patients undergoing vascular surgery have also been reported recently, including significant reductions in perioperative mortality and in adverse cardiovascular events.<sup>31,32</sup> Statins also appear to improve the patency rates of autogenous infrainguinal bypass grafts.<sup>33</sup>

Our practice is to start all patients on adequate beta-blockade (to a target heart rate of less than 60 beats per minute) and add a statin (for those not already receiving one) before the vascular surgical procedure, and to continue these agents postoperatively if tolerated. The preoperative clearance visit is a convenient opportunity to initiate such medications.

#### Close follow-up needed to ensure lasting benefit

Following invasive therapy, the vascular patient should receive ongoing care and close follow-up. Surveillance vascular studies (such as serial arterial/graft duplex scans and resting/exercise ankle-brachial index measurement) are necessary to evaluate the continued patency of the segment or segments that were intervened upon. These studies, together with the symptoms reported by the patient at rest and with exertion, are important tools to help the vascular specialist decide on the need, proper timing, and best strategy for future interventions.

Additionally, implementing strict global cardiovascular risk-reduction strategies—including stringent risk-factor modification, exercise, and a healthy diet—is key to ensuring a successful and lasting outcome from the interventional procedure. Lifelong antiplatelet therapy (aspirin 325 mg/day or clopidogrel 75 mg/day, or both for select individuals [see table on page S31 of this supplement]), a supervised exercise/walking program, blood pressure control to less than 140/90 mm Hg, and control of low-density lipoprotein cholesterol to less than 100 mg/dL (with statins and other lipid-lowering agents), together with adequate diabetes control and complete smoking cessation, are all critical lifesaving and limb-saving measures following peripheral revascularization.

## REFERENCES

1. Dormandy JA, Rutherford RB. Management of peripheral arterial disease (PAD). TASC Working Group. TransAtlantic Inter-Society Consensus (TASC). *J Vasc Surg* 2000; 31(1 Pt 2):S1–S296.
2. Hirsch AT, Haskal ZJ, Hertzner NR, et al. ACC/AHA 2005 practice guidelines for the management of patients with peripheral arterial disease (lower extremity, renal, mesenteric, and abdominal aortic): a collaborative report from the American Association for Vascular Surgery/Society for Vascular Surgery, Society for Cardiovascular Angiography and Interventions, Society for Vascular Medicine and Biology, Society of Interventional Radiology, and the ACC/AHA Task Force on Practice Guidelines (Writing Committee to Develop Guidelines for the Management of Patients With Peripheral Arterial Disease). *Circulation* 2006; 113:e463–e654.
3. Dotter CT, Judkins MP. Transluminal treatment of arteriosclerotic obstruction. Description of a new technique and a preliminary report of its application. *Circulation* 1964; 30:654–670.
4. Feinglass J, Brown JL, LoSasso A, et al. Rates of lower-extremity amputation and arterial reconstruction in the United States, 1979 to 1996. *Am J Public Health* 1999; 89:1222–1227.
5. Tunis SR, Bass EB, Steinberg EP. The use of angioplasty, bypass surgery, and amputation in the management of peripheral vascular disease. *N Engl J Med* 1991; 325:556–562.
6. Krajcer Z, Howell MH. Update on endovascular treatment of peripheral vascular disease: new tools, techniques, and indications. *Tex Heart Inst J* 2000; 27:369–385.
7. Murray JG, Apherop LA, Wilkins RA. Long-segment ( $\geq 10$  cm) femoropopliteal angioplasty: improved technical success and long-term patency. *Radiology* 1995; 195:158–162.
8. Matsi PJ, Manninen HI, Vanninen RL, et al. Femoropopliteal angioplasty in patients with claudication: primary and secondary patency in 140 limbs with 1–3-year follow-up. *Radiology* 1994; 191:727–733.
9. Capek P, McLean GK, Berkowitz HD. Femoropopliteal angioplasty. Factors influencing long-term success. *Circulation* 1991; 83:170–180.
10. Ring EJ, Freiman DB, McLean GK, Schwarz W. Percutaneous recanalization of common iliac artery occlusions: an unacceptable complication rate? *AJR Am J Roentgenol* 1982; 139:587–589.
11. Colapinto RE, Stronell RD, Johnston WK. Transluminal angioplasty of complete iliac obstructions. *AJR Am J Roentgenol* 1986; 146:859–862.
12. Schurmann K, Mahnken A, Meyer J, et al. Long-term results 10 years after iliac arterial stent placement. *Radiology* 2002; 224:731–738.
13. Bosch JL, Hunink MG. Meta-analysis of the results of percutaneous transluminal angioplasty and stent placement for aortoiliac occlusive disease. *Radiology* 1997; 204:87–96.
14. Perler BA, Williams GM. Does donor iliac artery percutaneous transluminal angioplasty or stent placement influence the results of femorofemoral bypass? Analysis of 70 consecutive cases with long-term follow-up. *J Vasc Surg* 1996; 24:363–369; discussion 369–370.
15. White CJ. Non-surgical treatment of patients with peripheral vascular disease. *Br Med Bull* 2001; 59:173–192.
16. Martin EC. Transcatheter therapies in peripheral and noncoronary vascular disease. Introduction. *Circulation* 1991; 83(2 Suppl):I1–I5.
17. Greenberg D, Rosenfield K, Garcia LA, et al. In-hospital costs of self-expanding nitinol stent implantation versus balloon angioplasty in the femoropopliteal artery (the VascoCoil Trial). *J Vasc Interv Radiol* 2004; 15:1065–1069.
18. Ouriel K, Shortell CK, DeWeese JA, et al. A comparison of thrombolytic therapy with operative revascularization in the initial treatment of acute peripheral arterial ischemia. *J Vasc Surg* 1994; 19:1021–1030.
19. The STILE Investigators. Results of a prospective randomized trial evaluating surgery versus thrombolysis for ischemia of the lower extremity. The STILE trial. *Ann Surg* 1994; 220:251–266; discussion 266–268.
20. Ouriel K, Veith FJ, Sasahara AA. A comparison of recombinant urokinase with vascular surgery as initial treatment for acute arterial occlusion of the legs. Thrombolysis or Peripheral Arterial Surgery (TOPAS) Investigators. *N Engl J Med* 1998; 338:1105–1111.
21. Berridge DC, Makin GS, Hopkinson BR. Local low dose intra-arterial thrombolytic therapy: the risk of stroke or major haemorrhage. *Br J Surg* 1989; 76:1230–1233.
22. Voorhees AB Jr, Jaretzki A III, Blakemore AH. The use of tubes constructed from vinyon “N” cloth in bridging arterial defects. *Ann Surg* 1952; 135:332–336.
23. Veith FJ, Gupta SK, Ascer E, et al. Six-year prospective multicenter randomized comparison of autologous saphenous vein and expanded polytetrafluoroethylene grafts in infrainguinal arterial reconstructions. *J Vasc Surg* 1986; 3:104–114.
24. Taylor LM Jr, Edwards JM, Porter JM. Present status of reversed vein bypass grafting: five-year results of a modern series. *J Vasc Surg* 1990; 11:193–205; discussion 205–206.
25. Belkin M, Knox J, Donaldson MC, et al. Infrainguinal arterial reconstruction with nonreversed greater saphenous vein. *J Vasc Surg* 1996; 24:957–962.
26. Ouriel K. Peripheral arterial disease. *Lancet* 2001; 358:1257–1264.
27. Albers M, Romiti M, Brochado-Neto FC, Pereira CA. Meta-analysis of alternate autologous vein bypass grafts to infrapopliteal arteries. *J Vasc Surg* 2005; 42:449–455.
28. McFalls EO, Ward HB, Moritz TE, et al. Coronary-artery revascularization before elective major vascular surgery. *N Engl J Med* 2004; 351:2795–2804.
29. Poldermans D, Boersma E, Bax JJ, et al. The effect of bisoprolol on perioperative mortality and myocardial infarction in high-risk patients undergoing vascular surgery. Dutch Echocardiographic Cardiac Risk Evaluation Applying Stress Echocardiography Study Group. *N Engl J Med* 1999; 341:1789–1794.
30. Brady AR, Gibbs JS, Greenhalgh RM, et al. Perioperative beta-blockade (POBBLE) for patients undergoing infrarenal vascular surgery: results of a randomized double-blind controlled trial. *J Vasc Surg* 2005; 41:602–609.
31. Poldermans D, Bax JJ, Kertai MD, et al. Statins are associated with a reduced incidence of perioperative mortality in patients undergoing major noncardiac vascular surgery. *Circulation* 2003; 107:1848–1851.
32. Durazzo AE, Machado FS, Ikeoka DT, et al. Reduction in cardiovascular events after vascular surgery with atorvastatin: a randomized trial. *J Vasc Surg* 2004; 39:967–975; discussion 975–976.
33. Abbruzzese TA, Havens J, Belkin M, et al. Statin therapy is associated with improved patency of autogenous infrainguinal bypass grafts. *J Vasc Surg* 2004; 39:1178–1185.

*Address:* Amjad AlMahameed, MD, Division of Cardiology, Beth Israel Deaconess Medical Center, Cardiology-W/Baker 4, One Deaconess Road, Boston, MA 02215; aalmaham@bidmc.harvard.edu.