

**ILA TAMASKAR, MD**

Department of Hematology and Medical Oncology, Taussig Cancer Center, Cleveland Clinic

**ENA SEGOTA, MD**

Department of Hematology and Medical Oncology, Taussig Cancer Center, Cleveland Clinic

**MATT KALAYCIO, MD**

Department of Hematology and Medical Oncology, Taussig Cancer Center, Cleveland Clinic

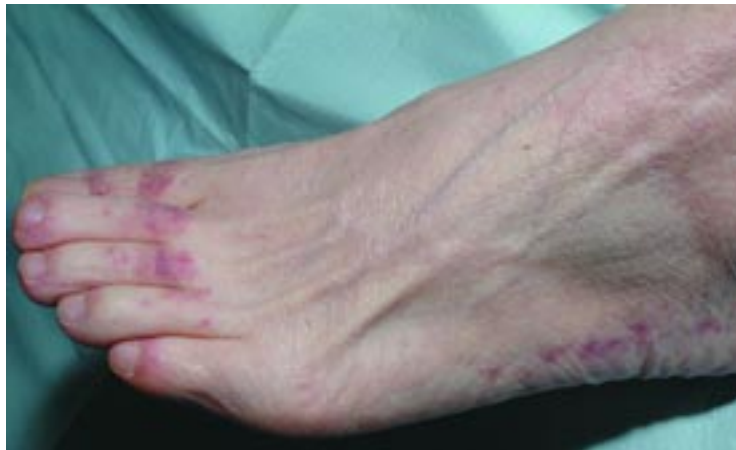**JAROSLAW MACIEJEWSKI, MD, PhD**

Department of Hematology and Medical Oncology, Taussig Cancer Center, Cleveland Clinic



# The Clinical Picture

## A woman with aplastic anemia and a rash



**FIGURE 1**

**A** 52-YEAR-OLD WOMAN developed severe aplastic anemia 1 month after treatment with interferon (eg, Pegasys, Peg-Intron) and ribavirin (eg, Rebetol) for hepatitis C infection. She was admitted to the hospital for treatment with equine antithymocyte globulin (Atgam) 40 mg/kg/day (for 4 days) and methylprednisolone (Solu-Medrol) 120 mg intravenously daily.

While in the hospital, she developed neutropenic fever, and empiric antibiotic coverage was started with piperacillin-tazobactam (Zosyn) and gentamicin (Garamycin). In addition, because she had a history of recurrent genital herpes, she was started on valacyclovir (Valtrex).

The fever persisted, and on the 4th day amphotericin B (Amphocin, Fungizone) was started. Blood cultures remained negative. Erythema developed around her Hickman catheter exit site, for which vancomycin (Vancocin) was added on the 9th day of fever.

The following day, she reported itching on the top of her head, and a rash was noted on her chest, abdomen, and extremities (**FIGURE 1**). The vancomycin was stopped because of the possibility of a drug reaction. The rash and itching persisted, and her piperacillin-tazobactam and gentamicin were changed to imipenem-cilastatin (Primaxin) and ciprofloxacin (Cipro). A skin biopsy was performed.

**Q: Based on the patient's history, which is the most likely diagnosis?**

- Antibiotic-induced rash
- Dermatomyositis
- Serum sickness
- Kaposi sarcoma
- Septic emboli

**A:** Serum sickness is the most likely diagnosis. However, at first, the patient's physicians thought she had an antibiotic-induced rash that did not seem to improve with a change in her antibiotic regimen.

Once the clinical picture and histopathologic findings on skin biopsy were thought to be consistent with serum sickness, she was treated with increasing doses of prednisolone. Her fever abated, and her antibiotic coverage was changed back to gentamicin and ciprofloxacin.

In spite of this double coverage against gram-negative organisms, on the 18th day after admission the patient suddenly developed symptoms of septic shock. Blood cultures grew *Pseudomonas* and *Enterococcus* species.

Despite intensive care, her condition deteriorated and she died.

### ■ SERUM SICKNESS: AN IMMUNE COMPLEX DISEASE

Serum sickness reaction is a type III immune complex disease. Classically, it is caused by receiving a protein antigen from a nonhuman species, leading to immunization and formation of antigen-antibody or immune complexes. The immune complexes may form in the circulation and then be deposited in tissues, or they form in situ in the involved tissues. Once they accumulate in parenchymal tissues, the immune complexes provoke an inflammatory response.

Equine antithymocyte globulin is a preparation of antibodies obtained from the serum of horses that have been immunized with human lymphocytes. Antithymocyte globulin inhibits the cell-mediated immune response either by altering T-cell function or by eliminating antigen-reactive cells thought to be involved in the pathogenesis of aplastic anemia. It can provoke a systemic immune reaction 4 to 7 days after injection, manifesting as serum sickness.

Several other drugs can produce similar responses. These include murine and chimeric monoclonal antibodies such as infliximab (Remicade) and rituximab (Rituxan).

In addition, some nonprotein drugs can act like haptens, binding to albumin and causing immune-complex deposition and serum-sickness-like reactions. Examples are antibiotics such as cefaclor (Ceclor), penicillin, and trimethoprim-sulfamethoxazole (eg, Bactrim).

#### Clinical features

Clinical evidence of serum sickness develops in almost all patients who receive antithymocyte globulin without concomitant prophylactic steroids.

**Rash** is often the earliest clinical feature, although fever may precede the rash in 1% to 20% of cases. Urticaria occurs in more than 90% of cases.

The rash usually starts in the anterior lower trunk, groin, periumbilical, or axillary regions and spreads to involve the back, upper trunk, and extremities. In the extremities, the

rash appears as a characteristic serpiginous erythematous eruption at the junction of the palmar or plantar skin on the dorsolateral surface of the hands, feet, fingers, and toes, as it did in our patient. If the provoking drug was given subcutaneously or intramuscularly, the rash often starts in the region around the injection site.

The rash generally lasts a few days to 2 weeks. Ulcers, secondary infection, or scarring does not occur.

Less common skin eruptions include erythema simplex, morbilliform rashes, scarlatiniform rashes, erythema multiforme, petechial rashes, and rubelliform rashes along with palmar erythema, livedo reticularis, and periungual hemorrhages. In contrast to Stevens-Johnson syndrome, serum sickness does not affect mucous membranes.

Our patient had pruritic, coalescing, erythematous macules and papules involving the neck, trunk, toes, and upper thighs, forming patches and plaques of circinate arrangement with no mucosal involvement.

**Fever and malaise** develop 1 to 2 weeks after receiving the offending agent.

**Other symptoms** include lymphadenopathy, arthralgias, arthritis, generalized edema, myalgias, and gastrointestinal symptoms (eg, bloating, abdominal cramps, nausea, and diarrhea). Rarely, there is evidence of myocarditis, pericarditis, pleuritis, nephritis, and neurologic complications such as brachial plexus and peripheral neuritis, Guillain-Barré syndrome, optic neuritis, cranial nerve palsies, and encephalomyelitis.

#### Histology

The histologic features of the classic rash of serum sickness vary. Some patients may have leukocytoclastic vasculitis with neutrophilic involvement and fibrinoid necrosis of small vessels. In contrast, skin biopsies from patients who develop serum sickness from equine antithymocyte globulin for bone marrow failure show mild perivascular infiltrates consisting of lymphocytes and histiocytes.

Our patient's skin biopsy revealed a superficial perivascular and interstitial lymphohistiocytic infiltrate associated with vacuolar changes at the dermoepidermal junction consistent with an antithymocyte globulin-induced serum sickness.

**Serum sickness can develop 4 to 7 days after exposure to a nonhuman protein**



## Treatment

The offending agent should be withdrawn if possible.


Antihistamines can be used for patients with pruritus, mild rash, and low-grade fever.

Nonsteroidal anti-inflammatory drugs and analgesics are used to treat arthralgias.

Patients with higher fever, severe arthritis and arthralgias, or more extensive rashes can receive short courses of corticosteroids.

If the patient is neutropenic, fever should not be attributed solely to serum sickness. These patients should receive parenteral antibiotics active against gram-negative bacteria for at least 48 hours or until the fever resolves and blood cultures are negative. If the patient appears clinically ill or if the fever is prolonged, antifungal agents, antiviral agents, or both should also be considered. Even with this approach, many patients with low granulocyte counts succumb to overwhelming infections.

## ■ SUGGESTED READING

**Naguwa SM, Nelson BL.** Human serum sickness. *Clin Rev Allergy* 1985; 3:117–126. 

**Nigen S, Knowles SR, Shear NH.** Drug eruptions: approaching the diagnosis of drug-induced skin diseases. *J Drugs Dermatol* 2003; 2:278–299.

---

**ADDRESS:** Ila Tamaskar, MD, Department of Hematology and Medical Oncology, Taussig Cancer Center, R35, Cleveland Clinic, 9500 Euclid Avenue, Cleveland, OH 44195; e-mail [tamasai@ccf.org](mailto:tamasai@ccf.org).