



The Clinical Picture

A middle-aged man with progressive neurologic deficits and bilateral leg lesions

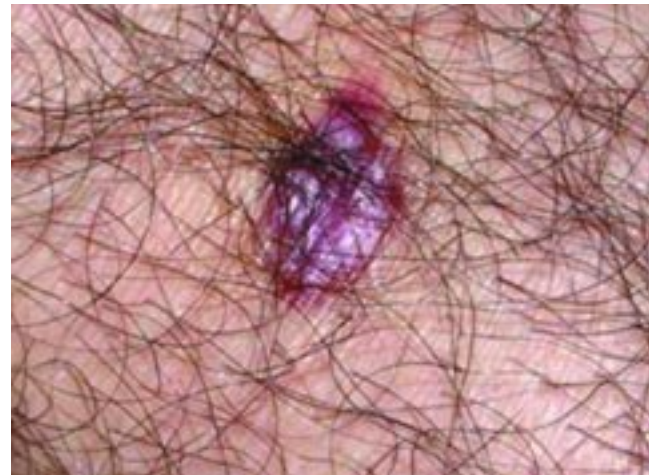
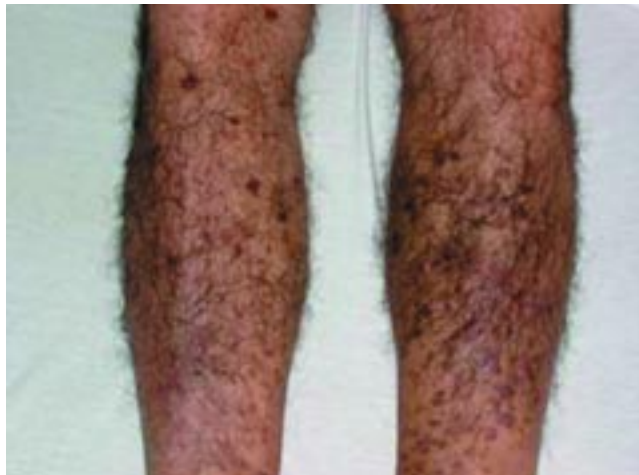
FIGURE 1

A 51-YEAR-OLD RIGHT-HANDED MAN is referred to a hospital from an outpatient clinic. He has severe dysarthria and dysphagia. His symptoms were mild when they began 1 month ago—he initially noted difficulty saying the “R” sound—and have rapidly progressed to the point that his speech is severely impaired and he cannot swallow either liquids or solids.

Over the past week, he developed progressive left hemiparesis involving his leg more than his arm.

He can walk but notes a clear difference between his two sides. He has no other neurologic symptoms.

He recently had otitis media, which was treated with antibiotics. He does not drink, smoke, or use illegal drugs. He emigrated from Croatia 10 years ago.

Physical examination

The patient is thin and in no apparent distress.

He is cognitively intact, with intact language but severe dysarthria. Cranial nerve examination reveals only difficulty with coordinated movement of the tongue. Motor examination reveals Medical Research Council (MRC) grade 4/5 strength in the left upper and lower extremities, somewhat weaker in extension of the arm and flexion of the leg. His gait is impaired due to left lower-extremity weakness. Finger-to-nose, heel-to-shin, and rapid alternating movements are intact.

Skin lesions exist on both lower legs (FIGURE 1). He says they have been present for several years, are painless, and have never been diagnosed.

Q: What are the lesions and how do they affect the differential diagnosis?

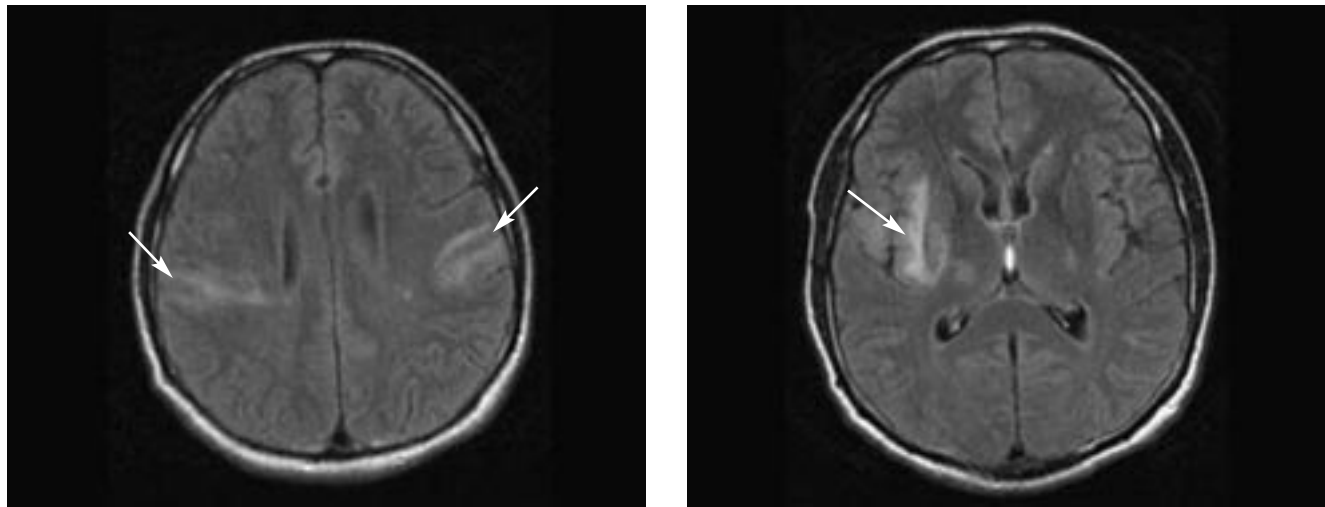


FIGURE 2. Magnetic resonance images with fluid-attenuated inversion recovery (FLAIR) showing bilateral regions of hyperintensity (arrows).

A: The lesions are characteristic of Kaposi sarcoma, a condition associated with suppression of the immune system. If they are Kaposi sarcoma, a likely cause of his neurologic symptoms is a central nervous system condition associated with immune system failure, eg:

- Progressive multifocal leukoencephalopathy (PML)
- Disseminated cytomegalovirus encephalitis
- Toxoplasmosis
- Cryptococcal meningitis
- Primary central nervous system lymphoma.

Human immunodeficiency virus (HIV) is high on the list as a primary cause of central nervous system dysfunction and as a cause of immune suppression leading to skin and central nervous system involvement. Neurologic disease is present in about 39% to 70% of patients with symptomatic HIV infection¹ and is the presenting complaint in 7% to 20%.

■ CASE CONTINUED

Skin biopsy of the lesion confirms Kaposi sarcoma.

Magnetic resonance imaging (MRI) of the brain shows bilateral regions of hyperintensity on fluid-attenuated inversion recovery (FLAIR) sequencing (**FIGURE 2**) and T2-weighted images, involving primarily the white matter. These do not enhance with

gadolinium contrast administration. There are no areas of significantly restricted diffusion, which would suggest stroke.

Subacute stroke may produce a similar appearance on MRI, but the clinical history of progressive neurologic deficit and its multifocal nature argue against this diagnosis. Multiple sclerosis would be consistent with two discrete and seemingly unrelated episodes of neurologic deficit, but one would expect to see more involvement of the periventricular white matter and not see lesions in the insular cortex. Also, actively demyelinating plaques typically enhance after contrast is given.

The lack of contrast enhancement also argues against toxoplasmosis (which typically causes ring-enhancing lesions), lymphoma, or metastatic tumor. In cryptococcal meningitis, MRI studies often appear normal or may show mild ventricular dilatation, a contrast-enhancing parenchymal mass, or nonenhancing cystic lesions in the basal ganglia.

Areas of hyperintensity on T2 and FLAIR imaging that do not enhance with contrast and are not associated with a mass in a patient with HIV suggest either PML, HIV encephalitis, cytomegalovirus encephalitis, or a primary central nervous system lymphoma. However, HIV encephalitis and cytomegalovirus encephalitis usually have more diffuse involvement and more cerebral atrophy. The predominance of disease in the white matter argues for PML.^{2,3}

HIV is high on the list of causes of immune suppression and central nervous system dysfunction

Laboratory tests

- White blood cell count $3.13 \times 10^9/\text{L}$ (normal 4.5–11.0)
- Platelet count $93 \times 10^9/\text{L}$ (normal 150–450)
- HIV test positive
- CD4 count 68 cells/ μL (normal 533–1,674)
- Cerebrospinal fluid analysis by polymerase chain reaction (PCR) detects JC virus.

■ PML AND AIDS

PML is a demyelinating disease of the central nervous system caused by the reactivation of a latent JC virus (named for the initials of the first patient identified) infection in a patient who is immunocompromised.⁴ The multifocal nature of PML leads to a variety of presenting signs and symptoms. Common symptoms include focal or generalized weakness (50%–63%), gait disturbance (32%–43%), cognitive dysfunction (29%–55%), speech disturbance (21%–50%), seizures (5%–23%),⁵ and visual disturbances (30%–50%), including homonymous hemianopsia and cortical blindness.

PML was first described in 1958, associated with suppressed cellular immunity, most commonly in lymphoproliferative disorders.⁶ It is more common in patients with acquired immunodeficiency syndrome (AIDS) than in those who are immunocompromised from other causes.

PML was found in 2% to 4% of patients with AIDS in the 1980s, although estimates of the incidence of PML as the AIDS-defining illness in the era before highly active antiretroviral therapy (HAART) varied with the population studied and were reported as high as 27%.⁷ It continues to be found in 2% to 4% of patients with AIDS, usually appearing when the CD4 count falls below 100 cells/ μL .

The relationship between the JC virus, HIV, and the immune system appears to be more complex than simple immunocompromise. Experimental evidence suggests that JC virus transcription is up-regulated in glial cells by the HIV Tat protein via cross-transregulation. The reduction in cytotoxic T cells and disruption of the blood-brain barrier (via migration into the brain of JC virus-infected B cells) may also contribute.

Testing for JC virus

Primary JC virus infection occurs during childhood and is asymptomatic. Anti-JC immunoglobulin can be detected in more than 80% of adults, indicating that the JC virus is nearly ubiquitous.

JC virus can be found in cerebrospinal fluid by PCR, which is 70% to 100% sensitive and 92% to 100% specific for detecting it.⁸ Testing in other body fluids is less reliable.

Most authorities consider that JC virus can be confidently diagnosed in an immunocompromised patient who has the characteristic clinical course, typical MRI findings, and JC virus detected in the cerebrospinal fluid. However, a negative PCR does not exclude the diagnosis, and in such cases, a brain biopsy may establish the diagnosis.

HAART prolongs survival in PML

For the most part, HAART stabilizes and even causes regression of AIDS-associated PML.

In the pre-HAART era, patients with PML survived for a mean of only 2 to 4 months, and only 17% survived for 6 months. While HAART does not specifically target the JC virus, treating HIV infection, particularly with regimens that include a protease inhibitor, increases survival. Berenguer et al⁹ found that 64% of patients receiving HAART survived for a median of 2.2 years after the diagnosis of PML. Unfortunately, treatment success is not universal, and HAART does not prolong survival in patients with a high JC viral load.

Several drugs are being investigated to specifically target the JC virus. In one observational study, patients treated with cidofovir (active against papovaviruses and cytomegalovirus) had improved neurologic outcome and survival, although a recent pilot study failed to confirm this.¹⁰

■ CASE FOLLOW-UP

Our patient survived his hospitalization and rehabilitation. HAART was initiated, and he has continued follow-up with an infectious disease specialist. At last follow-up, his neurologic status had improved moderately, although it had not returned to normal.

PML is seen in 2%–4% of patients with AIDS, usually with CD4 counts < 100



■ REFERENCES

1. **Skiest DJ.** Focal neurological disease in patients with acquired immunodeficiency syndrome. *Clin Infect Dis* 2002; 34:103–115.
2. **Sibtain NA, Chinn RJS.** Imaging of the central nervous system in HIV infection. *Imaging* 2002; 14:48–59.
3. **Thurnher MM, Thurnher SA, Schindler E.** CNS involvement in AIDS: spectrum of CT and MR findings. *Eur Radiol* 1997; 7:1091–1097.
4. **Safak M, Khalili K.** An overview: human polyomavirus JC virus and its associated disorders. *J Neurovirol* 2003; 9(suppl 1): 3–9.
5. **Collazos J.** Opportunistic infections of the CNS in patients with AIDS: diagnosis and management. *CNS Drugs* 2003; 17:869–887.
6. **Astrom KE, Mancall EL, Richardson EP Jr.** Progressive multifocal leukoencephalopathy: a hitherto unrecognized complication of chronic lymphatic leukaemia and Hodgkin's disease. *Brain* 1958; 81:93–111.
7. **Berger JR, Pall L, Lanska D, Whiteman M.** Progressive multifocal leukoencephalopathy in patients with HIV infection. *J Neurovirol* 1998; 4:59–68.
8. **Mamidi A, DeSimone JA, Pomerantz RJ.** Central nervous system infections in individuals with HIV-1 infection. *J Neurovirol* 2002; 8:158–167.
9. **Berenguer J, Miralles P, Arrizabalaga J, et al; GESIDA 11/99 Study Group.** Clinical course and prognostic factors of progressive multifocal leukoencephalopathy in patients treated with highly active antiretroviral therapy. *Clin Infect Dis* 2003; 36:1047–1052.
10. **Marra CM, Rajicic N, Barker DE, et al; Adult AIDS Clinical Trials Group 363 Team.** A pilot study of cidofovir for progressive multifocal leukoencephalopathy in AIDS. *AIDS* 2002; 16:1791–1797.

.....
ADDRESS: Stephen Samples, MD, Department of Neurology,
T33, The Cleveland Clinic Foundation, 9500 Euclid Avenue,
Cleveland, OH 44195.