

**THEODORE ROSEN, MD\***

Professor of Dermatology, Department of Dermatology, Baylor College of Medicine; Chief, Dermatology Service, Michael E. DeBakey VA Medical Center; Houston, TX

# Sexually transmitted diseases 2006: A dermatologist's view

## ■ ABSTRACT

Despite the downturn in the incidence of many sexually transmitted diseases (STDs), some—particularly genital herpes and genital warts—are epidemic, and syphilis is seeing a resurgence. This article covers how to recognize, diagnose, and manage common STDs and how their presentation and treatment differ in patients with human immunodeficiency virus (HIV) infection.

## ■ KEY POINTS

About half of all Americans acquire at least one STD in their lifetime.

Syphilis is increasing in incidence in men who have sex with men.

About one fifth of American adults—regardless of socioeconomic status—have genital herpes simplex virus (HSV-2), although most are unaware of it. Suppressive therapy is important to prevent transmission, which usually occurs during asymptomatic periods.

About 15% of sexually active adult Americans are infected with human papillomavirus (HPV), which causes genital warts and can be oncogenic. Immunomodulators can effectively treat it, and vaccines will likely be available soon.

HIV co-infection makes many STDs have an abnormal presentation and require more aggressive treatment.

Condoms are not completely protective against STDs. Counseling abstinence is worth a try.

**S**EXUALLY TRANSMITTED DISEASES (STDs) are on the rise: teens are starting sexual activity earlier, senior citizens are staying sexually active longer, and the Internet makes finding partners easy. Some people now regard HIV infection as “manageable” and have become lax about taking precautions.

This article reviews the cutaneous manifestations of common STDs and discusses their often different presentations in patients already infected with human immunodeficiency virus (HIV). Diagnosis, treatment, and prevention strategies are also covered.

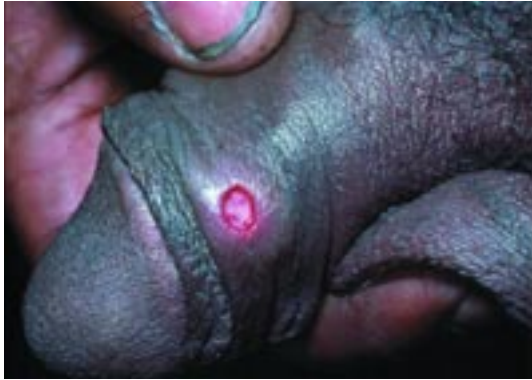## ■ A WORLDWIDE HEALTH PROBLEM

According to the World Health Organization, about 100 million acts of sexual intercourse take place worldwide daily, resulting in 910,000 conceptions and 350,000 new cases of STDs. Whether such numbers—extrapolated from surveys—are absolutely accurate is less important than the concept that STDs are a tremendous public health problem worldwide.

In the United States, about one third of adults have sex twice a week, one third have sex twice a month, and one third have sex twice a year. Those in the first group rate themselves in surveys as happier than those in the last group.

But the consequences of a lot of sexual activity are high rates of STDs. The US Centers for Disease Control and Prevention estimate that there were 19 million cases of

\*The author has indicated that he is on the speakers bureaus of the GlaxoSmithKline and 3M Pharmaceuticals corporations. Medical Grand Rounds articles are based on edited transcripts from Division of Medicine Grand Rounds presentations at Cleveland Clinic. They are approved by the author but are not peer-reviewed.



**FIGURE 1.** A classic syphilis lesion.

STDs in 2005, with 50% of Americans acquiring at least one by age 35. An estimated 20% of children have had sexual intercourse by age 14, and 25% of teenagers acquire an STD before high school graduation, regardless of their socioeconomic status.

While half of all STD cases are in the 15-to-24 age group, the incidence of such diseases has also increased recently in the geriatric population. Drugs that counter erectile dysfunction (ie, sildenafil, vardenafil, and tadalafil) have enabled senior citizens to continue having sexual activity.

Finding anonymous sexual partners—and acquiring STDs—has been facilitated in recent years by the widespread use of the Internet.

The estimated total economic cost of STDs in the United States is \$15.5 billion annually.

#### ■ THE HIV EPIDEMIC IS NOT OVER

Despite public health efforts and better treatment, a large reservoir of active HIV infection still exists. Every day there are about 16,000 new cases and 8,000 deaths worldwide. Rates of HIV in the United States have been stable, with an estimated 40,000 new cases annually and a total prevalence of about 1 million. Of people infected with HIV in this country, about 25% are being treated with highly active antiretroviral therapy (HAART), 25% have been diagnosed but are not being treated because of lack of access or money, and about half are unaware that they are infected. For example, a 2005 survey of about 1,700 men who have sex with men found that about one

quarter tested positive for HIV. Only about half of the men who tested positive already knew they were infected. Those with unrecognized infections were most often members of minority groups.<sup>1</sup>

There has been a demographic shift in disease incidence: when the epidemic began, the largest group acquiring the disease consisted of homosexual white men, and now the greatest increase in incidence is among heterosexual women from minority groups. Fortunately, antenatal testing seems to be an effective strategy, and the incidence of HIV infection in children has decreased.

#### ■ SYPHILIS IS SLOWLY INCREASING AGAIN

From 1990 to 2003, the annual incidence of syphilis dropped from more than 135,000 cases to fewer than 35,000. But numbers are slowly creeping up again, a trend attributed to men who have sex with men letting their guard down while viewing HIV infection as treatable. The two diseases are interrelated: any genital erosion or ulceration facilitates the acquisition and transmission of HIV.

The states with the highest rates of syphilis are mostly in the deep South, but certain urban areas, such as San Francisco, Atlanta, Baltimore, Columbus, Detroit, Albuquerque, Chicago, and large Texas cities are centers of high incidence.

#### Syphilis lesions and disease course

A “textbook” syphilis lesion is a solitary, painless, indurated ulcer on the genitals (FIGURE 1). But the lesion can also look much worse and can appear on the lip, tongue, and even on the uvula from oral-genital contact.

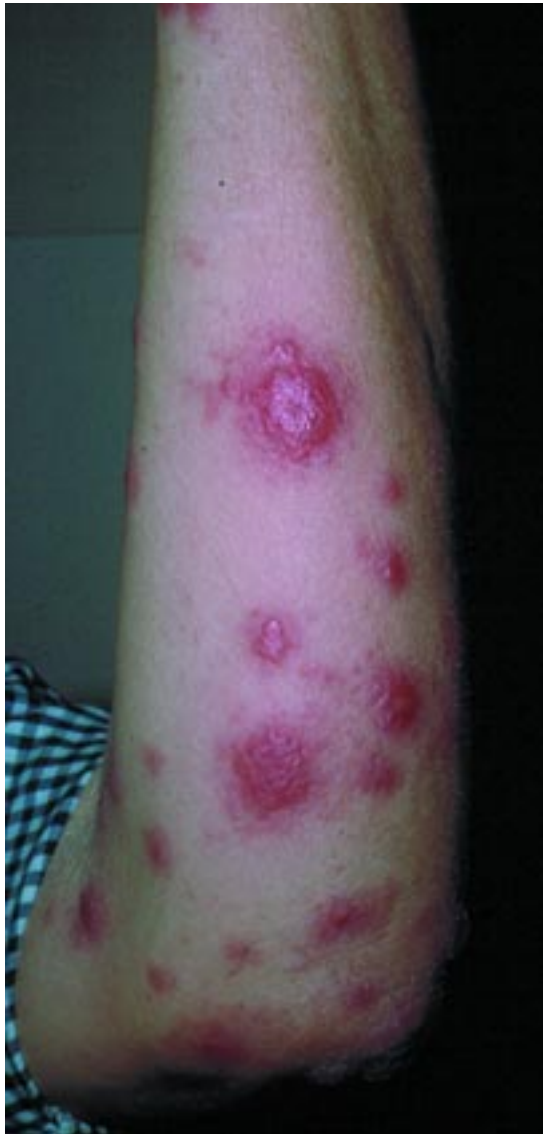The normal course of syphilis is a sequence starting with a primary chancre. Six to 8 weeks after the chancre heals, secondary syphilis develops, with some combination of rashes on the palms, soles, and body, mucous patches in the mouth, and patchy hair loss. Tertiary syphilis occurs some 3 to 15 years later and involves the central nervous system and other organs.

#### Syphilis and HIV

Patients who are already infected with HIV may have unusual presentations of syphilis.

**Now the greatest increase in HIV incidence is in heterosexual women from minority groups**

**Patients with HIV may have unusual presentations of syphilis**



**FIGURE 2.** Secondary rash of syphilis in a patient with human immunodeficiency virus infection.

The secondary rash can resemble cutaneous lymphoma or psoriasis, with unusual indurated plaques and nodules (FIGURE 2). Simultaneous appearance of the primary chancre and the secondary rash is an almost certain indication that HIV is also present. The eyes or central nervous system may become involved earlier than normally occurs in patients with syphilis alone.

Co-infection with HIV may also cause serologic tests to be falsely negative and for relapse to occur despite adequate therapy.<sup>2</sup>

### Treatment of syphilis

The preferred treatment is still benzathine penicillin, given in a single intramuscular injection. For those with severe penicillin allergy, multidose regimens involving erythromycin, doxycycline, and tetracycline are available.

Single-dose regimens are preferred from a public health standpoint: one can ensure that the patient leaves the office sufficiently treated. Unfortunately, two experimental single-dose regimens, oral azithromycin and intramuscular ceftriaxone, have not proven effective.<sup>3,4</sup>

### ■ GENITAL HERPES: THE MOST COMMON STD

Genital herpes is the single most prevalent STD in the United States and is increasing by about 1 million new infections per year. About 45 million—more than 20% of Americans older than 12 years—are now estimated to be infected.<sup>5</sup>

The disease cuts across all regions and socioeconomic groups. Leone et al<sup>6</sup> conducted a cross-sectional study with about 5,400 subjects aged 18 to 59 years presenting at affluent, suburban primary care clinics in six US cities and found that 25.5% were seropositive for herpes simplex virus (HSV-2). Geographic region, marital status, employment status, and income did not correlate with infection rate. Of those who tested positive, only 12% already knew they were infected.

Cherpes et al,<sup>7</sup> in a study of more than 1,200 women in the Pittsburgh area, found smoking to be an independent risk factor for HSV-2 infection. A nicotine byproduct concentrates in genital secretions and suppresses T cells, making it easier to acquire the viruses that cause herpes as well as external genital warts.

### Clinical manifestations of herpes

Classic genital herpes manifests as an intact group of painful blisters on a red base. Usually, one sees blisters that have ruptured and crusted. The essential characteristic is a group of lesions.

Painful urination can be a symptom of herpes. Studies in Europe have found that

TABLE 1

**Treatments for genital herpes**

DRUG	DOSAGE		
	FIRST EPISODE (7 DAYS)	SUBSEQUENT EPISODES (5 DAYS)	CHRONIC SUPPRESSION
Acyclovir	400 mg three times a day	400 mg twice a day	400 mg twice a day
Valacyclovir	1,000 mg twice a day	500 mg twice a day	500 mg daily
Famciclovir	250 mg twice a day	125 mg twice a day	250 mg twice a day

12% of cases of apparent urethritis are caused by intraurethral herpes.

**Diagnostic testing for herpes**

If a patient presents with an active lesion, the lesion should be swabbed and cultured. If, on the other hand, a patient presents with no active lesions but describes having recurring lesions, a blood test for HSV-2 should be done. Although a positive test does not prove that herpes is the cause of the lesions, a negative test indicates that other less common diseases, such as Behçet disease, erythema multiforme, or other blistering diseases, must be considered.

New blood tests for herpes are now available. These enzyme-linked immunosorbent assays (ELISAs) are comparable to Western blot assays in sensitivity and specificity and can distinguish exposure to HSV-2 from exposure to HSV-1. These tests may not be able to help a patient sort out which sexual partner transmitted the infection, however: seroconversion after exposure to the virus may take as long as 6 months, and immunoglobulin G (IgG) and IgM antibodies cannot help distinguish a new from an old infection with herpes as they can for many other viruses.<sup>8,9</sup>

To order these new tests, it may not be adequate to request “herpes serology” or “herpes blood test”: a request code separate from the standard one used by the laboratory may be required. The tests cost about \$70, and insurance coverage varies. Insurance is more likely to pay if one uses the diagnostic code indicating “exposure to venereal disease.”

**Preventing herpes transmission**

In a study of 42 women and 11 men who had no symptoms of herpes but were found to be

seropositive for HSV-2,<sup>9</sup> after 1 year of detailed counseling about the signs and symptoms of genital herpes, as well as frequent swabs of genital skin to detect viral shedding, 46 of the 53 learned to recognize when they were having outbreaks. Interestingly, 44 subjects shed virus even when their skin appeared normal.

By culture, asymptomatic shedding apparently occurs on up to 2% of days in men and up to 8% of days in women. But by polymerase chain reaction (PCR) testing, shedding has been found to occur on 28% of days.<sup>10,11</sup>

Mertz et al<sup>12</sup> studied 214 couples in which only one partner had genital herpes. After a median time of nearly 1 year, transmission occurred in 10% of the couples, with 70% of transmitted events apparently occurring during periods of asymptomatic viral shedding.

A patient who has a positive blood test should be regarded as having the disease and being able to transmit it, regardless of whether he or she has had recognizable symptoms. Although there are regimens to treat the first episode, treating in an episodic fashion does not address the key issue that most transmission occurs during asymptomatic periods. Patients who are willing to undergo chronic antiviral suppressive therapy should be encouraged to do so (TABLE 1).

Corey et al,<sup>13</sup> in a landmark study, followed nearly 1,500 couples in which only one partner had genital herpes. Subjects with herpes were randomized to receive valacyclovir 500 mg once daily or placebo for 8 months. Suppressive therapy resulted in 75% fewer cases of overt disease and 73% fewer days of viral shedding. Overall transmission (including evidence of infection by seroconversion) occurred in 1.9% of those taking suppressive

**New ELISA tests for herpes are now available**

treatment vs 3.6% of those taking placebo ( $P = .04$ ).

Valacyclovir is now approved for suppression therapy by the US Food and Drug Administration (FDA). Similar studies have not been done to prove suppression efficacy for suppressive doses of acyclovir or famciclovir, although I believe the outcomes would be the same.

### HSV and immunocompromise

In patients who are immunocompromised, one or multiple painful erosions teeming with organisms may be present almost constantly (FIGURE 3). Herpes outbreaks in patients with HIV result in a dramatic increase in HIV viral load for about 30 to 45 days, and HAART becomes less effective. Preliminary unpublished data of current studies indicate that maximally suppressing the herpes virus can enhance HAART, resulting in a lower viral load and a higher T-cell count.

The antiviral drugs normally used for herpes suppression—acyclovir, valacyclovir, and famciclovir—may not work in immunocompromised patients because they must be activated by a viral enzyme that may be missing in the subtypes of virus most often infecting such individuals.

The antiviral drugs normally used for herpes suppression—acyclovir, valacyclovir, and famciclovir—may not work in immunocompromised patients because they must be activated by a viral enzyme that may be missing in the subtypes of virus most often infecting such individuals.

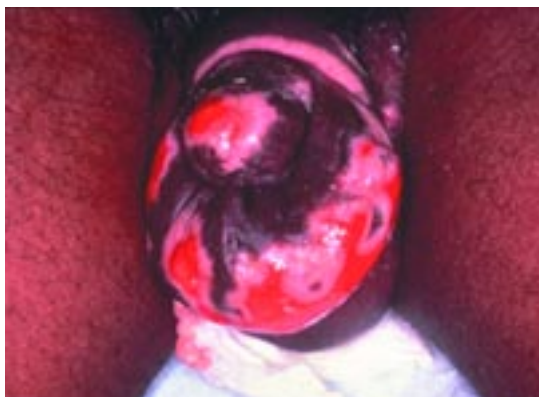For patients with acyclovir-resistant herpes, several options are available:

- Foscarnet 40 to 60 mg/kg every 8 hours
- Vidarabine 10 mg/kg/day
- Cidofovir 3 to 5 mg/kg every 2 weeks.

**Cidofovir topical ointment** (1%–3%) is effective but very expensive and not covered by insurance.

**Eye drops.** Surprisingly, the very easy-to-apply and inexpensive trifluorothymidine 1% (Viroptic) ophthalmic solution, dripped on lesions 4 to 6 times a day, is effective in about one quarter to one third of cases, and is a good first choice for treating acyclovir-resistant herpes. The antiviral ingredient does not need to be activated by the missing enzyme. Interestingly, when herpes recurs after this treatment, it is often an acyclovir-sensitive strain that can be managed with the standard antiviral drugs.

A large variety of alternative medicines for herpes outbreaks are popular and are tout-



**FIGURE 3.** Herpes simplex virus lesion in a patient with human immunodeficiency virus infection.

ed on the Internet but have not been proven effective. These include aloe, echinacea, lysine, zinc, and honey.

### ■ IMIQUIMOD IS EFFECTIVE FOR GENITAL WARTS

About 15% of the US population is infected with human papillomavirus (HPV): about 1% have overt external genital warts, another 3% to 4% have warts detectable under magnification, and another 10% have disease detectable by PCR testing.<sup>14</sup>

The newest treatment for HPV is imiquimod (Aldara), an immune response modifier. Instead of directly killing the virus, it enhances a person's immune system by revving up interferon, interleukin-12, tumor necrosis factor-alpha, and chemokines, which stimulate T cells to migrate to the site and destroy the virus.

When imiquimod is used as directed as monotherapy (applied at bedtime 3 days a week), from 70% to 100% of women are cleared of external genital warts after 12 to 16 weeks, but only about one third to one half of men are.<sup>15</sup> The discrepancy in effectiveness between men and women is attributed to the fact that the receptors to this drug are encoded on the X chromosome.

Warts recur infrequently after treatment with immune-enhancing drugs, and repeat treatment is often effective. Buck et al,<sup>16</sup> in a study of 449 women who had total clearance of anogenital warts after 16 weeks of treatment with imiquimod, found that warts

**Most herpes transmission occurs during asymptomatic periods**

TABLE 2

### Ivermectin treatment for pubic lice or scabies

DOSAGE	COMMENTS
<b>For pubic lice</b> Two 250- $\mu$ g/kg doses	Give 1 to 2 weeks apart
<b>For scabies</b> Single 3-mg dose	For children weighing 15–24 kg
Single 6-mg dose	For children weighing 25–35 kg
Two 250- $\mu$ g/kg doses	For those weighing > 35 kg; give 1 to 2 weeks apart

recurred in 15%. Of those women, 75% experienced total clearance again after a second 16-week treatment course. Patients who are successfully retreated almost never have a recurrence because the drug causes the immune memory against HPV to be up-regulated.

The need for this drug to treat HPV may soon be obsolete: vaccines against HPV, which appear to be essentially 100% effective, are currently in the late phases of clinical trials and should be available this year. The vaccines being tested are bivalent, containing HPV 16 and HPV 18 (the oncogenic strains), and quadrivalent, which also includes HPV 6 and HPV 11, the common causes of genital warts. There is certain to be a debate on vaccinating teenagers before they become sexually active, but I feel it is important to do so.

#### HPV and HIV

Patients with HIV have a lower response to immune-enhancing drugs because their immune system is less functional. In addition to drugs, they need to be treated with physically destructive techniques such as burning, cutting, freezing, or laser.<sup>17</sup>

Warts also frequently occur in the anal canal of men who have sex with men, so we routinely perform Papanicolaou smears from the anal canal in men with HIV. Cytological changes indicate that squamous cell carcinoma in situ and invasive carcinoma may be present. If the Pap smear is positive but there are no visible lesions, we apply imiquimod to the normal-appearing skin until we see significant ero-

sion. It is uncomfortable for the patient, but I believe it prevents squamous cell carcinoma from developing.

#### ■ MOLLUSCUM CONTAGIOSUM

Molluscum contagiosum is a nuisance disease that is characterized by small bumps with central indentations on the genitals, suprapubic area, and upper inner thighs.

The virus responsible is persistent because it induces infected cells to synthesize proteins that interfere with the immune response against it. Immune-enhancing drugs are effective because they counter the proteins, exposing the virus to attack. Imiquimod, applied three to five times a week, clears 85% to 90% of cases of genital molluscum.<sup>18,19</sup>

#### ■ AVOID LINDANE FOR TREATING PUBIC LICE

Also called crabs, pubic lice were once routinely treated with the pesticide Lindane (gamma hexachlorocyclohexane). Several years ago the FDA issued a warning that Lindane has been associated with serious central nervous system side effects, including seizures and death, even when used as directed.

Adverse effects of Lindane are strongly associated with repeat applications or ingestion instead of topical use. It is especially dangerous in the very young or elderly, those weighing less than 50 kg, or those who abuse alcohol or take medications that lower the seizure threshold, such as antipsychotic drugs, systemic steroids, quinolone antibiotics, anti-malarial drugs, or benzodiazepines.

I recommend that Lindane be avoided completely unless no other choice exists. Several less dangerous treatments are now available:

**Pilocarpine gel**, an ophthalmologic drug used to treat glaucoma, is a neurotoxin for pubic lice. Treatment is topical application applied nightly for 7 days.<sup>20</sup> It is an expensive option if a wide area needs to be covered.

**Ivermectin** is used to treat certain worm infections both in dogs and in humans. Although no rigorous study has been performed for its use in treating pubic lice, anecdotal evidence indicates it is effective (TABLE

**Acyclovir, valacyclovir, and famciclovir may not work in immunocompromised patients**



2).<sup>21</sup> It is a neurotoxin and should be used only in people with an intact blood-brain barrier, so it is contraindicated for patients with a shunt or who have had brain surgery.

### ■ SCABIES

Scabies is characterized by itchy bumps on the genitals, wrists, inner digital webs of the hand, and in women on the areola. The rash and itching take about 6 weeks to appear from the time of exposure. Scabies is traditionally thought of as a disease of children and young adults, but cases in the elderly are now increasingly seen.<sup>22,23</sup>

**Permethrin** is the drug of choice.

**Sulfur** is effective but smells bad.

**Ivermectin** is also said to be effective against scabies. Although it is not approved by the FDA for this use, it is accepted as a first-line therapy for scabies by the Centers for Disease Control and Prevention.<sup>24</sup> Because it is a neurotoxin, it should not be used for young children, those weighing less than 15 kg, or adults who may not have an intact blood-brain barrier (TABLE 2).

Immunocompromised patients with scabies develop thick, hyperkeratotic lesions known as crusted or Norwegian scabies. Although the invading parasite itself is not dangerous, the deep fissures that tend to develop make patients vulnerable to bacterial invasion and sepsis. This form of scabies requires complicated prolonged treatment, consisting of a topical keratolytic like salicylic acid, a topical anti-mite agent like permethrin, plus two or three cycles of an oral agent like ivermectin.

### ■ SCLEROSING LYMPHANGITIS

Sclerosing lymphangitis is actually inflammation of the lymphatics entering the coronal sulcus (running between the shaft and the glans of the penis). The condition is usually caused by excessive sexual activity over a short period of time and resolves spontaneously by abstaining from sex.<sup>25</sup>

### ■ LEISHMANIASIS

Some cases of leishmaniasis—transmitted by sand fly bites—have been seen in soldiers

coming back from Iraq. The pathogenic parasite can be transmitted to any exposed area of skin, including the genitalia and surrounding region. The resultant ulcerative lesion strongly resembles an STD, a potential diagnostic error in caring for military or civilian personnel returning from the Middle East. The strains have been sensitive to fluconazole 200 mg per day for 6 weeks.

### ■ MINOR STDs

In the last decade, the incidence of some minor STDs in the United States has dropped substantially and these STDs have become extremely rare. From 1990 to 2003, reported cases of chancroid fell from more than 4,000 to 54, granuloma inguinale from nearly 100 to fewer than 10, and lymphogranuloma venereum from 277 to fewer than 25. A very minor outbreak of lymphogranuloma venereum occurred in San Francisco among men who have sex with men.

#### Chancroid

The most prevalent of these rare STDs is chancroid: most cases occur in New York City, Houston, and rural South Carolina. Chancroid is the most important genital ulcer disease in countries with a prevalence of HIV over 8%.<sup>26</sup>

The causative organism, *Haemophilus ducreyi*, is difficult to culture and requires a special agar and growth conditions. The laboratory must be informed that this organism is suspected.<sup>27</sup>

Clinically, there are multiple lesions that are usually painful and do not have the clean-based appearance typical of syphilis lesions. Lymphadenopathy may be prominent, and lymph nodes may form buboes and rupture.

*H ducreyi* produces a so-called cytolethal distending toxin that causes infected cells to distend and burst. When enough cells burst, a hole develops in the skin. Efforts are now under way to design neutralizing antibodies or an immunologic vaccine directed against the toxin.<sup>28,29</sup>

**Treatments** are:

- Erythromycin 500 mg 3 or 4 times a day for 7 days
- Azithromycin 1.0 g as a single oral dose

**Oral sex  
should  
not be  
considered  
safe sex**

- Ceftriaxone 250 mg as a single intramuscular dose
- Ciprofloxacin 500 mg twice a day for 3 days.

### ■ GENITAL BITES


Genital bites, either as part of sexual foreplay or as deliberate malicious acts, can result in very painful infections that can be extremely destructive within less than 48 hours. The causative organism is usually *Eikenella corrodens*, a normal part of the human oral flora. It is treated with large doses of combined amoxicillin and clavulanic acid (Augmentin) 1 to 1.5 g/day over 10 to 14 days.<sup>30,31</sup>

### ■ PREVENTION OF STDs

Abstinence, while not popular, is a reasonable choice for some people and should be encouraged for those who would consider it.

Oral sex should not be considered a “safe”

sexual act: recent studies have found that people with oral squamous cell carcinoma have more frequent oral sex, on average, than do matched controls. Oral squamous cell carcinoma is most often caused by oncogenic HPV strains that were probably acquired from oro-genital contact.<sup>32</sup>

Condoms are not foolproof protection against STDs. They break about 2% of the time and slip off about as often, either partially or completely. Lubricants, including vegetable oil and mineral oil, as well as products that prevent yeast infections and itching, are destructive to latex. The damage may not be visible, but the interstices between the latex fibers may enlarge enough to allow organisms to get through.<sup>33–37</sup> Nonlatex condoms are less effective as contraceptives and have a 2.5 to 5 times greater breakage rate than do latex condoms.<sup>38</sup> In addition, condoms do not provide full coverage and are often not used until genital contact has been made. 

### ■ REFERENCES

1. Sifakis S, Flynn CP, Metsch L, et al. HIV prevalence, unrecognized infection and HIV testing among men who have sex with men—five U.S. cities, June 2004–April 2005. *MMWR* 2005; 54:597–601.
2. Hutchinson CM, Hook EW 3rd, Shepherd M, Verley J, Rompalo AM. Altered clinical presentation of early syphilis in patients with human immunodeficiency virus infection. *Ann Intern Med* 1994; 121:94–100.
3. Hook EW 3rd, Peeling RW. Syphilis control—a continuing challenge. *N Engl J Med* 2004; 351:122–124.
4. Smith NH, Musher DM, Huang DB, et al. Response of HIV-infected patients with asymptomatic syphilis to intensive intramuscular therapy with ceftriaxone or procaine penicillin. *Int J STD AIDS* 2004; 15:328–332.
5. Fleming DT, McQuillan GM, Johnson RE, et al. Herpes simplex virus type 2 in the United States, 1976 to 1994. *N Engl J Med* 1997; 337:1105–1111.
6. Leone P, Fleming DT, Gilsenan AW, Li L, Justus S. Seroprevalence of herpes simplex virus-2 in suburban primary care offices in the United States. *Sex Transm Dis* 2004; 31:311–316.
7. Chernes TL, Meyn LA, Krohn MA, Hillier SL. Risk factors for infection with herpes simplex virus type 2: role of smoking, douching, uncircumcised males, and vaginal flora. *Sex Transm Dis* 2003; 30:405–410.
8. Leone P. Type-specific serologic testing for herpes simplex virus-2. *Curr Infect Dis Rep* 2003; 5:159–165.
9. Wald A, Ashley-Morrow R. Serological testing for herpes simplex virus (HSV)-1 and HSV-2 infection. *Clin Infect Dis* 2002; 35(suppl 2):S173–S182.
10. Wald A, Zeh J, Selke S, Ashley RL, Corey L. Virologic characteristics of subclinical and symptomatic genital herpes infections. *N Engl J Med* 1995; 333:770–775.
11. Wald A, Corey L, Cone R, Hobson A, Davis G, Zeh J. Frequent genital herpes simplex virus 2 shedding in immunocompetent women. Effect of acyclovir treatment. *J Clin Invest* 1997; 99:1092–1097.
12. Mertz GJ, Benedetti J, Ashley R, Selke SA, Corey L. Risk factors for the sexual transmission of genital herpes. *Ann Intern Med* 1992; 116:197–202.
13. Corey L, Wald A, Patel R, et al; Valacyclovir HSV Transmission Study Group. Once-daily valacyclovir to reduce the risk of transmission of genital herpes. *N Engl J Med* 2004; 350:11–20.
14. Koutsky L. Epidemiology of genital human papillomavirus infection. *Am J Med* 1997; 102(5A):3–8.
15. Arican O, Guneri F, Bilgic K, Karaoglu A. Topical imiquimod 5% cream in external anogenital warts: a randomized, double-blind, placebo-controlled study. *J Dermatol* 2004; 31:627–631.
16. Buck HW, Fortier M, Knudsen J, Paavonen J. Imiquimod 5% cream in the treatment of anogenital warts in female patients. *Int J Gynaecol Obstet* 2002; 77:231–238.
17. Cusini M, Salmasso F, Zerboni R, et al. 5% Imiquimod cream for external anogenital warts in HIV-infected patients under HAART therapy. *Int J STD AIDS* 2004; 15:17–20.
18. Liota E, Smith KJ, Buckley R, Menon P, Skelton H. Imiquimod therapy for molluscum contagiosum. *J Cutan Med Surg* 2000; 4:76–82.
19. Hengge UR, Esser S, Schultewolter T, et al. Self-administered topical 5% imiquimod for the treatment of common warts and molluscum contagiosum. *Br J Dermatol* 2000; 143:1026–1031.
20. Kumar N, Dong B, Jenkins C. Pubic lice effectively treated with Pilogel. *Eye* 2003; 17:538–539.
21. Burkhart CG, Burkhart CN. Oral ivermectin for *Phthirus pubis*. *J Am Acad Dermatol* 2004; 51:1037–1038.
22. Gimenez Garcia R, de la Lama Lopez-Areal J, Avellaneda Martinez C. Scabies in the elderly. *J Eur Acad Dermatol Venereol* 2004; 18:105–107.
23. Laube S. Skin infections and ageing. *Ageing Res Rev* 2004; 3:69–89.
24. Centers for Disease Control and Prevention. Sexually transmitted diseases treatment guidelines 2002. *MMWR Recomm Rep* 2002; 51(RR-6):1–78.
25. Rosen T, Hwang H. Sclerosing lymphangitis of the penis. *J Am Acad Dermatol* 2003; 49:916–918.
26. Steen R. Eradicating chancroid. *Bull World Health Organ* 2001; 79:818–826. Epub 2001 Oct 23.
27. Joseph AK, Rosen T. Laboratory techniques used in the diagnosis of chancroid, granuloma inguinale, and lymphogranuloma venereum. *Dermatol Clin* 1994; 12:1–8.
28. Wising C, Azem J, Zetterberg M, Svensson LA, Ahlman K, Lagergard





- T. Induction of apoptosis/necrosis in various human cell lineages by *Haemophilus ducreyi* cytolethal distending toxin. *Toxicon* 2005; 45:767–776.
29. **Wising C, Molne L, Jonsson IM, Ahlman K, Lagergard T.** The cytolethal distending toxin of *Haemophilus ducreyi* aggravates dermal lesions in a rabbit model of chancroid. *Microbes Infect* 2005; 7:867–874.
  30. **Rosen T, Conrad N.** Genital ulcer caused by human bite to the penis. *Sex Transm Dis* 1999; 26:527–530.
  31. **Rosen T.** Penile ulcer from traumatic orogenital contact. *Dermatol Online J* 2005; 11:18.
  32. **Smith EM, Ritchhie EM, Summerrill KF, et al.** Age, sexual behavior, and human papillomavirus infection in oral cavity and oropharyngeal cancers. *Int J Cancer* 2004; 108:766–772.
  33. **Albert AE, Warner DL, Hatcher RA, Trussell J, Bennett C.** Condom use among female commercial sex workers in Nevada's legal brothels. *Am J Public Health* 1995; 85:1514–1520.
  34. **Steiner MJ, Cates W Jr, Warner L.** The real problem with male condoms is nonuse. *Sex Transm Dis* 1999; 26:459–462.
  35. **Rosen AD, Rosen T.** Study of condom integrity after brief exposure to over-the-counter vaginal preparations. *South Med J* 1999; 92:305–307.
  36. **Callahan M, Mauck C, Taylor D, Frezieres R, Walsh T, Martens M.** Comparative evaluation of three Tactylon(TM) condoms and a latex condom during vaginal intercourse: breakage and slippage. *Contraception* 2000; 61:205–215.
  37. **Walsh TL, Frezieres RG, Peacock K, et al.** Effectiveness of the male latex condom: combined results for three popular condom brands used as controls in randomized clinical trials. *Contraception* 2004; 70:407–413.
  38. **Gallo MF, Grimes DA, Schulz KF.** Nonlatex vs. latex male condoms for contraception: a systematic review of randomized controlled trials. *Contraception* 2003; 68:319–326.

### ■ SUGGESTED READING

- Chilukuri S, Rosen T.** Management of acyclovir-resistant herpes simplex virus. *Dermatol Clin* 2003; 21:311–320.
- Rosen T.** Update on genital lesions. *JAMA* 2003; 290:1001–1005.
- Rosen T, Brown TJ.** Cutaneous manifestations of sexually transmitted diseases. *Med Clin North Am* 1998; 82:1081–1104, vi.
- Rosen T, Brown TJ.** Genital ulcers. Evaluation and treatment. *Dermatol Clin* 1998; 16:673–685, x.

.....  
**ADDRESS:** Theodore Rosen, MD, Professor of Dermatology,  
 2815 Plumb, Houston, TX 77005; e-mail rosen@bcm.edu.