

**MARK G. RABBAT, MD**Department of Internal Medicine,  
Cleveland Clinic**ANTHONY A. BAVRY, MD, MPH\***Department of Cardiovascular Medicine,  
Cleveland Clinic**DEEPAK L. BHATT, MD†**Associate professor of medicine, Cleveland  
Clinic Lerner College of Medicine; associate  
director, Cleveland Clinic Cardiovascular  
Coordinating Center; staff, Cardiac,  
Peripheral, and Carotid Intervention,  
Department of Cardiovascular Medicine,  
Cleveland Clinic**STEPHEN G. ELLIS, MD‡**Professor of medicine, Cleveland Clinic  
Lerner College of Medicine; head, Section  
of Invasive Cardiology, Department of  
Cardiovascular Medicine, Cleveland Clinic

# Understanding and minimizing late thrombosis of drug-eluting stents

## ■ ABSTRACT

Although the safety profiles of drug-eluting stents are similar to those of bare metal stents in the short term, concern has arisen about their potential for late thrombosis (occurring > 30 days after implantation). Stent thrombosis is rare but potentially devastating and can result in ST-segment elevation myocardial infarction or death. The aim of this article is to review the incidence, predictors, pathology, and prevention of late thrombosis of drug-eluting stents.

## ■ KEY POINTS

Drug-eluting stents carry a higher risk of late stent thrombosis compared with bare metal stents, although the absolute risk remains small—less than 1% in most published series with follow-up of 9 to 48 months.

When it occurs, stent thrombosis can result in myocardial infarction in 60% to 70% of cases and death in 45%.

Complete termination of dual antiplatelet therapy with aspirin plus clopidogrel (Plavix) after stent implantation can result in late stent thrombosis. The proper duration of this therapy is unclear; however, at least 12 months of uninterrupted therapy is currently recommended.

A bare metal stent should be considered in patients at low risk for restenosis, those with bleeding conditions, those who will need surgery soon, or those at high risk of thrombosis.

\*Dr. Bavry has received honoraria from Genesis.

†Dr. Bhatt has served as a consultant to AstraZeneca, Bristol-Myers Squibb, Centocor, Daiichi-Sankyo, Eisai, Eli Lilly, GlaxoSmithKline, Millennium, Paringenix, PDL, Sanofi-Aventis, Schering-Plough, and The Medicines Company.

‡Dr. Ellis has served as a consultant to Cordis, Boston Scientific, and Abbott, and receives research support from Cordis and Medtronic.

**T**HE PAST FEW MONTHS have seen great concern—in both the medical literature and the lay press—about the risk of late stent thrombosis in patients who have received a drug-eluting stent. Though data are limited and late stent thrombosis is rare, the risk is real, and it is greater with drug-eluting stents than with bare metal stents.

To reduce the risk of thrombosis in drug-eluting stents, it may be important to use these devices more selectively, assessing patients' risk of restenosis, their risk of bleeding, their need for surgery in the future, and the risk of late stent thrombosis.

As for how long patients with drug-eluting stents should receive dual antiplatelet therapy, ie, aspirin plus clopidogrel (Plavix), we should consider giving it for longer than the 3 to 6 months currently recommended, though there are few data to guide us at this time. At our institution, we routinely treat for 12 to 24 months after stent implantation, and in some high-risk cases we will employ indefinite dual antiplatelet therapy.

Finally, special care must be taken in patients who must undergo surgery while they are receiving antiplatelet therapy after receiving a drug-eluting stent.

## ■ THE EVOLUTION OF ANGIOPLASTY AND STENTING

The use of coronary stents has increased dramatically in the last decade, primarily because of their ability to reduce the restenosis that was common in balloon angioplasty alone.

In the 1980s, balloon angioplasty without stents led to restenosis in 15% to 60% of patients, depending on comorbidities, vessel

TABLE 1

## Data on late thrombosis with drug-eluting stents

STUDY	DESIGN	NO. OF PATIENTS	TIME OF EVENTS (MONTHS)*	INCIDENCE (%)		FOLLOW-UP (MONTHS)*	ANTIPLATELET THERAPY AT TIME OF EVENT†
				DES	BMS		
McFadden et al <sup>14</sup>	Case series	4	12	N/A	N/A	N/A	100% late termination
Bavry et al <sup>15</sup>	Meta-analysis	6,675	15.5 (SES) 18 (PES)	0.50	0	12–48	Uncertain
Ellis et al <sup>16</sup>	Meta-analysis	3,445	17	0.50†	0.06†	≥ 12	62.5% premature termination 37.5% late termination
Moreno et al <sup>17</sup>	Meta-analysis	5,030	Uncertain	0.20	0.20	12	Uncertain
Ong et al <sup>18</sup>	Observational	2,006	9.5	0.35	N/A	18 (mean)	12.5% premature termination 25% late termination
Kuchulakanti et al <sup>19</sup>	Observational	2,974	5.1±3.3 (mean)	0.30	N/A	N/A	50% on aspirin monotherapy
Park et al <sup>20</sup>	Observational	1,911	6.1	0.60	N/A	19.4	36% of patients still on dual anti-platelet therapy
Rodriguez et al <sup>21</sup>	Observational	225	7.2	1.80	N/A	18.3±8.8 (mean)	25% premature termination 75% late termination
Iakovou et al <sup>12</sup>	Observational	2,229	1.9	0.70	N/A	9	Uncertain

DES = drug-eluting stent, BMS = bare metal stent, SES = sirolimus-eluting stent, PES = paclitaxel-eluting stent, N/A = not applicable

\*Time of thrombotic events and clinical follow-up represent median values unless otherwise stated.

†Incidence of late stent thrombosis from 6 months to 3 years.

‡Premature termination: occurring < 6 months after implantation for paclitaxel stents or < 3 months for sirolimus stents.

Late termination: occurring > 6 months after implantation.

size, and lesion complexity.<sup>1–4</sup> Bare metal coronary stents, gradually adopted in the early 1990s, reduced the risk of target lesion revascularization to approximately 12% to 16%.<sup>1,2</sup>

And restenosis is hardly benign: in 1,186 consecutive cases of bare metal stent restenosis, 9.5% of patients presented with myocardial infarction.<sup>5</sup>

Then came drug-eluting stents, which revolutionized the practice of interventional cardiology. These stents slowly release anti-growth factors from a polymer coating over several months to prevent restenosis. Two models are available, one of them using the immunosuppressant sirolimus (Cypher; Cordis Corp., Miami Lakes, FL) and the other using the anticancer drug paclitaxel (Taxus; Boston Scientific Corp., Natick, MA).

Two pivotal trials of drug-eluting stents in patients at low or medium risk undergoing elective percutaneous intervention found rates of revascularization in target lesions of 3% to 4%—a 75% relative reduction in restenosis compared with bare metal stents.<sup>6,7</sup> Now, more

than 85% of percutaneous coronary interventions in the United States are performed with drug-eluting stents.<sup>8</sup> More than 6 million of the devices have been placed worldwide.<sup>9</sup>

But a number of reports of late stent thrombosis have raised concerns about drug-eluting stents. Late thrombotic events are very rare with bare metal stents, although they occur in more than 5% of patients after brachytherapy.<sup>10,11</sup> Stent thrombosis is serious, as it is often manifested by acute myocardial infarction or death. In an observational study of 2,229 patients, 29 developed stent thrombosis, of whom 13 (45%) died, while most of the rest suffered nonfatal myocardial infarction.<sup>12</sup>

#### ■ CLASSIFYING AND DEFINING STENT THROMBOSIS

Stent thrombosis can be classified according to how long after placement it occurs, ie:

- Acute (within 24 hours)
- Subacute (2 to 30 days)

- Late (30 days to 1 year)
- Very late (after 1 year).

The Academic Research Consortium<sup>13</sup> recently proposed a new standard definition of stent thrombosis:

- Definite or confirmed event (presenting as an acute coronary syndrome with angiographic or pathologic confirmation of stent thrombosis)
- Probable event (unexplained death within 30 days or target vessel myocardial infarction without angiographic confirmation of stent thrombosis)
- Possible event (any unexplained death after 30 days).

Termination of dual antiplatelet therapy is also classified (somewhat arbitrarily) as:

- Premature (stopped less than 6 months after placement of a paclitaxel stent or 3 months after a sirolimus stent), or
- Late (stopped more than 6 months after the stent was implanted).

## ■ HOW COMMON IS STENT THROMBOSIS?

Numerous studies have attempted to define the incidence of late drug-eluting stent thrombosis (TABLE 1).<sup>12,14–21</sup> Meta-analyses that we and others performed in 2005 found no difference in the incidence of stent thrombosis with either sirolimus-eluting or paclitaxel-eluting stents compared with bare metal stents during intermediate follow-up of 6 to 12 months.<sup>17,22,23</sup> The overall incidence of stent thrombosis was less than 1% for both bare metal stents and drug-eluting stents in these analyses.

However, more recent studies suggest that drug-eluting stents increase the risk of late stent thrombosis. A meta-analysis of 14 clinical trials with longer follow-up noted that the incidence of very late thrombosis of drug-eluting stents (occurring > 1 year after the index procedure) was 0.5%, with no events reported with bare metal stents.<sup>15</sup> These findings were confirmed by another analysis of the four principal randomized trials of paclitaxel stents, in which the incidence of late stent thrombosis (> 6 months after the index procedure) was 0.5% higher with paclitaxel-eluting stents than with bare metal stents.<sup>16</sup> Importantly, this did not translate into an increase in death or myocardial infarction in the paclitaxel-

**TABLE 2**

## Risk factors for late thrombosis with drug-eluting stents

Bifurcation lesion, or crossing arterial branch points  
Greater total stent length  
Heightened platelet reactivity  
In-stent restenosis  
Left ventricular dysfunction  
Localized hypersensitivity vasculitis  
Penetration of necrotic core  
Plaque disruption in non-stented segment  
Renal failure  
Resistance to antiplatelet drugs (possibly)

eluting stent population. These data suggest that although drug-eluting stents reduce the risk of acute coronary syndromes due to stent restenosis, they may also slightly increase the risk of late thrombotic events.<sup>5,24,25</sup>

Our current knowledge is limited in that most of the randomized trials excluded patients at high risk, whereas in clinical practice, patients receive drug-eluting stents in a variety of high-risk clinical situations—including acute myocardial infarction—and anatomic locations such as in long lesions or at bifurcations. In addition, long-term follow-up has not been universally reported, and the risk of thrombosis with dual antiplatelet therapy longer than 3 to 6 months is unknown. Therefore, the reported incidence of late drug-eluting stent thrombosis in the original trials may be an underestimate of their “real-world” incidence.

## ■ WHAT IS THE MECHANISM OF LATE STENT THROMBOSIS?

Early stent thrombosis is often related to mechanical aspects of revascularization such as an unrecognized dissection, small final lumen diameter, and persistently slow flow.<sup>26,27</sup> Our understanding of predictors of late stent thrombosis is evolving, but this phenomenon appears to be multifactorial (TABLE 2).

Virmani et al<sup>28</sup> were the first to draw attention to an association between localized hypersensitivity vasculitis and drug-eluting stents. Later, Nebeker and colleagues<sup>29</sup> (the same team) reviewed 262 cases of hypersensi-

**The reported incidence of late drug-eluting stent thrombosis may be an underestimate**

tivity-like reactions associated with drug-eluting stents reported from April 2003 to December 2004. They reported that 17 of these cases were “probably or certainly” related to the stents (possibly to the polymer coating), and that 4 of the 17 cases involved late stent thrombosis and death as far out as 18 months after implantation, with intrastent eosinophilic inflammation and lack of intimal healing at autopsy.

Joner et al<sup>30</sup> performed autopsies in 40 consecutive patients who died after receiving drug-eluting stents. Even 4 years after the stents were implanted, there were still fibrin deposits in the vessel wall, and the endothelium had not completely grown back. Partial endothelialization and a fibrin-rich milieu are potent thrombogenic stimuli. In contrast, and consistent with previous studies, patients who received bare metal stents showed greater arterial healing and near-complete endothelialization by 3 to 4 months after deployment.<sup>31,32</sup> These results have been confirmed in living patients undergoing angiography.<sup>33</sup>

Additionally, drug-eluting stents may have long-term adverse effects on local endothelium-dependent vasomotor responses, contributing to the risk of late stent thrombosis.<sup>34</sup>

Thrombosis may have worse consequences with drug-eluting stents than with bare metal stents, as the former have various inhibitory effects on the production of cytokines, growth factors, and chemotactic proteins, which may impair collateral function.<sup>35,36</sup> If collateral regression has occurred, this phenomenon can lead to more serious cardiac events.<sup>37</sup>

#### ■ RISK FACTORS FOR LATE STENT THROMBOSIS

**Longer stent coverage.**<sup>17,26,30</sup> Most drug-eluting stents are implanted to cover the entire lesion, because letting the ends of the stent fall in diseased segments has been associated with edge dissection and restenosis. Consequently, longer stents are being implanted, or multiple stents are being overlapped end to end.<sup>26,38</sup>

**Renal failure**<sup>12,39</sup> with microvascular and metabolic abnormalities may increase the risk of stent thrombosis, as increased platelet-

derived microparticles with procoagulant activity are released from activated platelets.<sup>39</sup>

#### **Left ventricular dysfunction.**<sup>12</sup>

**Properties of the artery.** Stenting at bifurcations and in-stent restenosis lesions, plaque disruption near the stented segment, and penetration of a necrotic lipid-rich core with extensive plaque prolapse are consistent predictors of late stent thrombosis.<sup>19,30,31</sup>

**Resistance to antiplatelet therapy** may increase the risk of early and, potentially, late drug-eluting stent thrombosis.<sup>40</sup> Four percent to 30% of patients do not respond adequately to clopidogrel on in vitro testing, and 5% to 45% do not respond adequately to aspirin.<sup>41,42</sup> Wenaweser et al<sup>40</sup> reported that 11 (48%) of 23 patients with stent thrombosis had an impaired response to aspirin (defined as > 20% platelet aggregation with 0.5 mg/mL arachidonic acid) compared with 32% of patients without stent thrombosis.

However, there is no universally accepted test for antiplatelet resistance, and therefore its prevalence varies among studies.<sup>43</sup> Currently, there is no agreement as to the role that antiplatelet resistance may play in late stent thrombosis.

#### ■ NOT ALL PATIENTS NEED A DRUG-ELUTING STENT

Not all patients need or should receive a drug-eluting stent. Several factors should be considered, such as the patient's risk of restenosis, his or her risk of bleeding, and the risk of late stent thrombosis (TABLE 3). Patients in whom a bare metal stent should be considered include the following:

**Those with a very low risk of restenosis,** who likely have little to gain from a drug-eluting stent.<sup>44,45</sup> Ellis et al<sup>46</sup> determined that the risk of needing revascularization within 9 months is low (4%–10%) if a bare metal stent is implanted in a native vessel, the lesion is de novo, the artery has a reference diameter of at least 3.5 mm, the lesion length is less than 5 mm, the patient does not have diabetes, and the lesion is not ostial.

**Patients with a bleeding condition** such as active peptic ulcer disease necessitating blood transfusions, who should not receive antiplatelet drugs long-term.

#### Correction



Patients who require coronary revascularization before undergoing a surgical procedure, who will need to interrupt their antiplatelet drugs before surgery. A bare metal stent will not necessitate prolonged, uninterrupted dual antiplatelet therapy. Additionally, in some stable patients it may be prudent to proceed with the surgical procedure without first performing revascularization.<sup>47</sup>

Patients at risk for late drug-eluting stent thrombosis include those with multiple additional risk factors or who are likely to be noncompliant with antiplatelet therapy.

### ■ HOW LONG TO CONTINUE DUAL ANTIPLATELET THERAPY?

Currently, stent manufacturers recommend that patients receive dual antiplatelet therapy for at least 4 weeks to prevent stent thrombosis with bare metal stents, 3 months with sirolimus-eluting stents, and 6 months with paclitaxel-eluting stents. The latter two treatment durations are based on the landmark clinical trials of drug-eluting stents.<sup>6,7</sup> However, on the basis of clinical trials of bare metal stents and brachytherapy, many clinicians routinely give dual antiplatelet therapy for at least 12 months.<sup>48–50</sup> At our institution, we routinely treat for 12 to 24 months after drug-eluting stent implantation, and in some high-risk cases we will employ indefinite dual antiplatelet therapy.

Stopping therapy prematurely is clearly harmful, as it has been associated with a more than 50-fold increased risk of stent thrombosis.<sup>12,51</sup>

If dual antiplatelet therapy must be stopped prematurely because the patient needs to undergo surgery, a bridging strategy with tirofiban (Aggrastat) or etifibatide (Integrilin),<sup>52</sup> which are intravenous glycoprotein IIb/IIIa inhibitors, with or without anticoagulant therapy with either unfractionated heparin or a low-molecular-weight heparin might be considered (FIGURE 1). A glycoprotein IIb/IIIa inhibitor is favored over anticoagulation, since dual antiplatelet therapy with aspirin and ticlopidine (Ticlid; another antiplatelet agent) is more effective in lowering rates of stent thrombosis than are aspirin and warfarin.<sup>53</sup> The optimal regimen and tim-

TABLE 3

### Who needs a drug-eluting stent, and who does not? Four hypothetical cases

#### CASE 1

A 66-year-old woman with a worsening chest pain syndrome and a history of hypertension, hyperlipidemia, and osteoarthritis underwent a preoperative stress test because she will undergo a right knee replacement in 1 month. The stress test was markedly positive, and on cardiac catheterization she was found to have severe disease of the mid-left anterior descending artery.

**Recommendation:** bare metal stent.

**Reason:** upcoming surgery in 1 month.

#### CASE 2

A 59-year-old man with a history of hyperlipidemia and 40-pack-year history of smoking underwent an exercise stress test for exertional angina. The stress test was positive, and he underwent cardiac catheterization demonstrating severe right coronary artery focal disease in a large, 4-mm vessel. He is not diabetic and has normal renal function.

**Recommendation:** bare metal stent.

**Reason:** low risk for restenosis (nondiabetic, focal lesion, large-diameter artery).

#### CASE 3

A 48-year-old man with a history of substance abuse (cocaine, heroin, and amphetamines), end-stage renal disease on hemodialysis, left ventricular dysfunction, and recent subdural hematoma (3 months ago) underwent cardiac catheterization for unstable angina. He was found to have a mid-circumflex artery lesion. He does not comply well with his current regimen.

**Recommendation:** bare metal stent.

**Reason:** high risk for bleeding (recent subdural hematoma); increased risk of late drug-eluting stent thrombosis (renal failure, noncompliance with medications, left ventricular dysfunction).

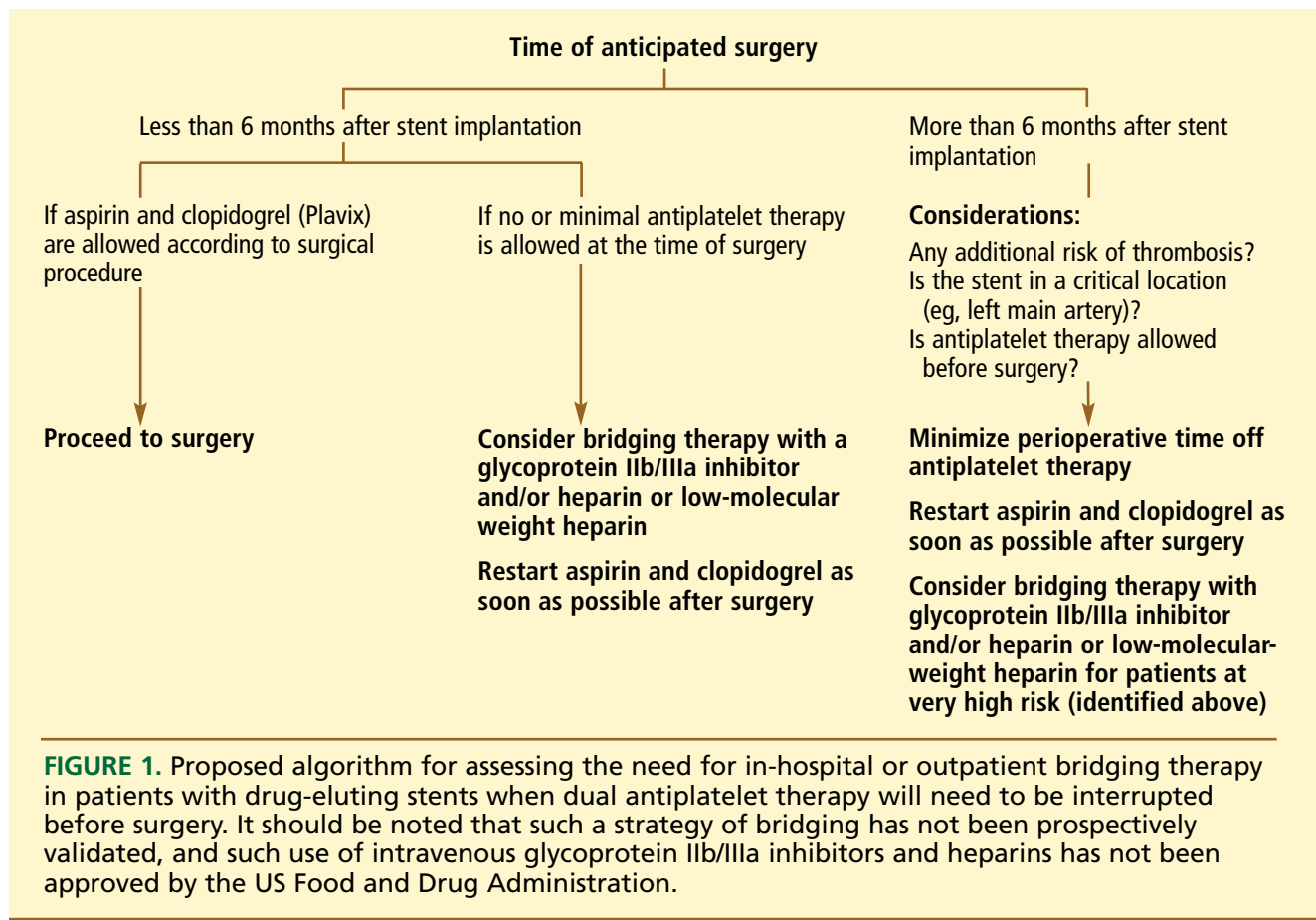
#### CASE 4

A 63-year-old woman with a history of diabetes, hypertension, and fibromyalgia presented to the emergency department with chest pain. A stress test was positive in the right coronary artery distribution, and left heart catheterization showed a small-diameter diffuse lesion in the right coronary artery. Her ventricular function is normal and she has no anticipated surgeries in the future.

**Recommendation:** drug-eluting stent.

**Reason:** high risk for restenosis (diabetes, diffuse lesion, small diameter), low risk for late drug-eluting stent thrombosis (no renal failure, nonbifurcating lesion, normal ventricular function).





ing of in-hospital or outpatient bridging requires further study, as there is currently no evidence to support its efficacy. A future bridging strategy may involve the use of the investigational intravenous adenosine diphosphate receptor antagonist cangrelor.

Some patients stop taking their medication on their own. A recent prospective study found that patients who prematurely stopped taking their clopidogrel were older, less likely to have completed high school or be married, more likely to avoid health care because of cost, and more likely to have had cardiovascular disease or anemia at presentation.<sup>54</sup> In fact, one out of eight patients stopped taking clopidogrel within 30 days of receiving a drug-eluting stent. These patients had a significantly higher risk of death during the next 11 months (7.5% vs 0.7%). Better patient education about the importance of dual antiplatelet therapy is vital to prevent late thrombosis in drug-eluting stents.

Debate has arisen regarding the proper duration of dual antiplatelet therapy beyond 6 to 12 months. Many cases of late stent thrombosis have been reported following late cessation of antiplatelet therapy. McFadden et al<sup>14</sup> reported four angiographically confirmed cases of drug-eluting stent thrombosis that occurred 335 to 442 days after implantation. In all four patients, antiplatelet therapy had been stopped less than 2 weeks before the event because they were scheduled for a surgical procedure. Two of the four patients also had bare metal stents that did not develop stent thrombosis.

While many surgeons ask that antiplatelet therapy be completely stopped before a scheduled procedure, some operations such as coronary artery bypass grafting and cataract surgery can safely be performed with the patient on aspirin therapy.<sup>55–58</sup> Therefore, managing antiplatelet therapy around surgical procedures involves weighing the risk of precipitating stent thrombosis (or native coronary

thrombosis) by stopping antiplatelet therapy vs increasing the risk of surgical bleeding by continuing the antiplatelet therapy. To balance these risks, the surgeon and cardiologist need to communicate during the perioperative period (FIGURE 1).

In a recent study of 1,911 consecutive patients with drug-eluting stents, one third of the cases of late stent thrombosis occurred while patients remained on dual antiplatelet therapy.<sup>20</sup> For patients who have survived an episode of late stent thrombosis while on dual antiplatelet therapy, triple antiplatelet therapy with aspirin, clopidogrel, and cilostazol (Pletal) may be an option to consider.<sup>59</sup> Certainly, one should ascertain if the patient really has been compliant with dual antiplatelet therapy.

## ■ WHAT WE RECOMMEND

Thrombotic events are rare after percutaneous intervention, but when they occur, they can kill. Recent findings of late drug-eluting stent thrombosis are of great concern, as these devices appear to increase the risk of late stent thrombosis compared with bare metal stents.

Careful management that involves the cardiologist is warranted in patients who receive drug-eluting stents, as stopping dual antiplatelet therapy can result in late stent thrombosis. At Cleveland Clinic, we usually treat with clopidogrel and aspirin for at least 12 to 24 months and aspirin indefinitely.

In-hospital or outpatient bridging with intravenous antiplatelet agents with or with-

out anticoagulant agents can be considered for some patients with a drug-eluting stent who must undergo a surgical operation that requires stopping dual antiplatelet therapy prematurely, though this approach needs to be prospectively validated.

For patients who have survived an episode of late stent thrombosis while on dual antiplatelet therapy, assuming that the initial procedure was technically adequate with respect to stent sizing and deployment (which can only be confirmed by intravascular ultrasonography), triple antiplatelet therapy may be considered.<sup>59</sup>

Many questions are yet to be answered. What is the proper duration of dual antiplatelet therapy after implantation of a drug-eluting stent? Which patients are at risk for late thrombosis?

Bare metal stents may be preferable in patients who do not take medications reliably, cannot afford clopidogrel, have a bleeding propensity, or may require a surgical procedure in the near future. A drug-eluting stent should be considered in patients at high risk for restenosis and without additional risk for late thrombosis. The advantage of drug-eluting stents (elimination of restenosis) must be weighed against the possible need for lifetime dual antiplatelet therapy.

The ultimate solution to these problems may require new generations of drug-coated stents or the development of bioabsorbable stents that remain in place only long enough to interdict the process of restenosis.

## ■ REFERENCES

1. Fischman DL, Leon MB, Baim DS, et al. A randomized comparison of coronary-stent placement and balloon angioplasty in the treatment of coronary artery disease. Stent Restenosis Study Investigators. *N Engl J Med* 1994; 331:496–501.
2. Serruys PW, de Jaegere P, Kiemeneij F, et al. A comparison of balloon-expandable-stent implantation with balloon angioplasty in patients with coronary artery disease. Benestent Study Group. *N Engl J Med* 1994; 331:489–495.
3. Babapulle MN, Eisenberg MJ. Coated stents for the prevention of restenosis: part I. *Circulation* 2002; 106:2734–2740.
4. Greenberg D, Bakhai A, Cohen DJ. Can we afford to eliminate restenosis? Can we afford not to? *J Am Coll Cardiol* 2004; 43:513–518.
5. Chen MS, John JM, Chew DP, Lee DS, Ellis SG, Bhatt DL. Bare metal stent restenosis is not a benign clinical entity. *Am Heart J* 2006; 151:1260–1264.
6. Stone GW, Ellis SG, Cox DA, et al. A polymer-based, paclitaxel-eluting stent in patients with coronary artery disease. *N Engl J Med* 2004; 350:221–231.
7. Moses JW, Leon MB, Popma JJ, et al. Sirolimus-eluting stents versus standard stents in patients with stenosis in a native coronary artery. *N Engl J Med* 2003; 349:1315–1323.
8. Kandzari DE, Roe MT, Ohman EM, et al. Frequency, predictors, and out-
- comes of drug-eluting stent utilization in patients with high-risk non-ST-segment elevation acute coronary syndromes. *Am J Cardiol* 2005; 96:750–755.
9. Shuchman M. Trading restenosis for thrombosis? New questions about drug-eluting stents. *N Engl J Med* 2006; 355:1949–1952.
10. Costa MA, Sabate M, van der Giessen WJ, et al. Late coronary occlusion after intracoronary brachytherapy. *Circulation* 1999; 100:789–792.
11. Waksman R, Bhargava B, Mintz GS, et al. Late total occlusion after intracoronary brachytherapy for patients with in-stent restenosis. *J Am Coll Cardiol* 2000; 36:65–68.
12. Iakovou I, Schmidt T, Bonizzi E, et al. Incidence, predictors, and outcome of thrombosis after successful implantation of drug-eluting stents. *JAMA* 2005; 293:2126–2130.
13. New proposed standard stent-thrombosis definition. Issued October 25, 2006. Available at: <http://www.theheart.org/article/749305.do>. Accessed November 14, 2006.
14. McFadden EP, Stabile E, Regar E, et al. Late thrombosis in drug-eluting coronary stents after discontinuation of antiplatelet therapy. *Lancet* 2004; 364:1519–1521.
15. Bavry AA, Kumbhani DJ, Helton TJ, Borek PP, Mood GR, Bhatt DL. Late thrombosis of drug eluting stents: a meta-analysis of randomized clinical



- trials. *Am J Med* 2006; 119:1056–1061.
16. Ellis SG, Colombo A, Grube E, et al. Stent thrombosis with the polymeric paclitaxel drug-eluting stent: incidence, timing, and correlates. A TAXUS II, IV, V, and VI meta-analysis of 3445 patients followed up to three years. *J Am Coll Cardiol*. In press.
  17. Moreno R, Fernandez C, Hernandez R, et al. Drug-eluting stent thrombosis: results from a pooled analysis including 10 randomized studies. *J Am Coll Cardiol* 2005; 45:954–959.
  18. Ong AT, McFadden EP, Regar E, de Jaegere PP, van Domburg RT, Serruys PW. Late angiographic stent thrombosis (LAST) events with drug-eluting stents. *J Am Coll Cardiol* 2005; 45:2088–2092.
  19. Kuchulakanti PK, Chu WW, Torguson R, et al. Correlates and long-term outcomes of angiographically proven stent thrombosis with sirolimus- and paclitaxel-eluting stents. *Circulation* 2006; 113:1108–1113.
  20. Park DW, Park SW, Park KH, et al. Frequency of and risk factors for stent thrombosis after drug-eluting stent implantation during long-term follow-up. *Am J Cardiol* 2006; 98:352–356.
  21. Rodriguez AE, Mieres J, Fernandez-Pereira C, et al. Coronary stent thrombosis in the current drug-eluting stent era: insights from the ERACI III trial. *J Am Coll Cardiol* 2006; 47:205–207.
  22. Bavry AA, Kumbhani DJ, Helton TJ, Bhatt DL. What is the risk of stent thrombosis associated with the use of paclitaxel-eluting stents for percutaneous coronary intervention?: a meta-analysis. *J Am Coll Cardiol* 2005; 45:941–946.
  23. Bavry AA, Kumbhani DJ, Helton TJ, Bhatt DL. Risk of thrombosis with the use of sirolimus-eluting stents for percutaneous coronary intervention (from registry and clinical trial data). *Am J Cardiol* 2005; 95:1469–1472.
  24. Roiron C, Sanchez P, Bouzamondo A, Lechat P, Montalescot G. Drug eluting stents: an updated meta-analysis of randomized controlled trials. *Heart* 2006; 92:641–649.
  25. Nayak AK, Kawamura A, Nesto RW, et al. Myocardial infarction as a presentation of clinical in-stent restenosis. *Circ J* 2006; 70:1026–1029.
  26. Cutlip DE, Baim DS, Ho KK, et al. Stent thrombosis in the modern era: a pooled analysis of multicenter coronary stent clinical trials. *Circulation* 2001; 103:1967–1971.
  27. Moussa I, Di Mario C, Reimers B, Akiyama T, Tobis J, Colombo A. Subacute stent thrombosis in the era of intravascular ultrasound-guided coronary stenting without anticoagulation: frequency, predictors and clinical outcome. *J Am Coll Cardiol* 1997; 29:6–12.
  28. Virmani R, Guagliumi G, Farb A, et al. Localized hypersensitivity and late coronary thrombosis secondary to a sirolimus-eluting stent: should we be cautious? *Circulation* 2004; 109:701–705.
  29. Nebeker JR, Virmani R, Bennett CL, et al. Hypersensitivity cases associated with drug-eluting coronary stents: a review of available cases from the Research on Adverse Drug Events and Reports (RADAR) project. *J Am Coll Cardiol* 2006; 47:175–181.
  30. Joner M, Finn AV, Farb A, et al. Pathology of drug-eluting stents in humans: delayed healing and late thrombotic risk. *J Am Coll Cardiol* 2006; 48:193–202.
  31. Farb A, Burke AP, Kolodgie FD, Virmani R. Pathological mechanisms of fatal late coronary stent thrombosis in humans. *Circulation* 2003; 108:1701–1706.
  32. Grewe PH, Deneke T, Machraoui A, Barmeyer J, Muller KM. Acute and chronic tissue response to coronary stent implantation: pathologic findings in human specimen. *J Am Coll Cardiol* 2000; 35:157–163.
  33. Kotani J, Awata M, Nanto S, et al. Incomplete neointimal coverage of sirolimus-eluting stents: angioscopic findings. *J Am Coll Cardiol* 2006; 47:2108–2111.
  34. Hofma SH, van der Giessen WJ, van Dalen BM, et al. Indication of long-term endothelial dysfunction after sirolimus-eluting stent implantation. *Eur Heart J* 2006; 27:166–170.
  35. Meier P, Zbinden R, Togni M, et al. Coronary collateral function long after drug-eluting stent implantation. *J Am Coll Cardiol* 2007; 49:15–20.
  36. Kern MJ. Attenuated coronary collateral function after drug-eluting stent implantation. A new downside of drug-eluting stents? *J Am Coll Cardiol* 2007; 49:21–22.
  37. Zimarino M, Ausiello A, Contegiacomo G, et al. Rapid decline of collateral circulation increases susceptibility to myocardial ischemia: the trade-off of successful percutaneous recanalization of chronic total occlusions. *J Am Coll Cardiol* 2006; 48:59–65.
  38. Cheneau E, Leborgne L, Mintz GS, et al. Predictors of subacute stent thrombosis: results of a systematic intravascular ultrasound study. *Circulation* 2003; 108:43–47.
  39. Ando M, Iwata A, Ozeki Y, Tsuchiya K, Akiba T, Nihei H. Circulating platelet-derived microparticles with procoagulant activity may be a potential cause of thrombosis in uremic patients. *Kidney Int* 2002; 62:1757–1763.
  40. Wenaweser P, Dorffler-Melly J, Imboden K, et al. Stent thrombosis is associated with an impaired response to antiplatelet therapy. *J Am Coll Cardiol* 2005; 45:1748–1752.
  41. Gum PA, Kottke-Marchant K, Welsh PA, White J, Topol EJ. A prospective, blinded determination of the natural history of aspirin resistance among stable patients with cardiovascular disease. *J Am Coll Cardiol* 2003; 41:961–965.
  42. Bhatt DL. Aspirin resistance: more than just a laboratory curiosity. *J Am Coll Cardiol* 2004; 43:1127–1129.
  43. Wang TH, Bhatt DL, Topol EJ. Aspirin and clopidogrel resistance: an emerging clinical entity. *Eur Heart J* 2006; 27:647–654.
  44. Kandzari DE, Tuttle RH, Zidar JP, Jollis JG. Temporal trends in target vessel revascularization in clinical practice: long-term outcomes following coronary stenting from the Duke Database for Cardiovascular Disease. *J Invasive Cardiol* 2006; 18:398–402.
  45. Bavry AA, Bhatt DL. Bare metal stents: no longer passe? *J Invasive Cardiol* 2006; 18:403–404.
  46. Ellis SG, Bajzer CT, Bhatt DL, et al. Real-world bare metal stenting: identification of patients at low or very low risk of 9-month coronary revascularization. *Catheter Cardiovasc Intervent* 2004; 63:135–140.
  47. McFalls EO, Ward HB, Moritz TE, et al. Coronary-artery revascularization before elective major vascular surgery. *N Engl J Med* 2004; 351:2795–2804.
  48. Mehta SR, Yusuf S, Peters RJ, et al. Effects of pretreatment with clopidogrel and aspirin followed by long-term therapy in patients undergoing percutaneous coronary intervention: the PCI-CURE study. *Lancet* 2001; 358:527–533.
  49. Steinhubl SR, Berger PB, Mann JT, et al. Early and sustained dual oral antiplatelet therapy following percutaneous coronary intervention: a randomized controlled trial. *JAMA* 2002; 288:2411–2420.
  50. Waksman R, Ajani AE, Pinnow E, et al. Twelve versus six months of clopidogrel to reduce major cardiac events in patients undergoing gamma-radiation therapy for in-stent restenosis: Washington Radiation for In-Stent restenosis Trial (WRIST) 12 versus WRIST PLUS. *Circulation* 2002; 106:776–778.
  51. Jeremias A, Sylvia B, Bridges J, et al. Stent thrombosis after successful sirolimus-eluting stent implantation. *Circulation* 2004; 109:1930–1932.
  52. Bhatt DL, Topol EJ. Glycoprotein inhibitors and fibrinolysis in myocardial infarction. *JAMA* 2000; 284:3124–3125.
  53. Leon MB, Baim DS, Popma JJ, et al. A clinical trial comparing three antithrombotic-drug regimens after coronary-artery stenting. Stent Anticoagulation Restenosis Study Investigators. *N Engl J Med* 1998; 339:1665–1671.
  54. Spertus JA, Kettelkamp R, Vance C, et al. Prevalence, predictors, and outcomes of premature discontinuation of thienopyridine therapy after drug-eluting stent placement: results from the PREMIER registry. *Circulation* 2006; 113:2803–2809.
  55. Mangano DT. Aspirin and mortality from coronary bypass surgery. *N Engl J Med* 2002; 347:1309–1317.
  56. Dacey LJ, Munoz JJ, Johnson ER, et al. Effect of preoperative aspirin use on mortality in coronary artery bypass grafting patients. *Ann Thorac Surg* 2000; 70:1986–1990.
  57. Katz J, Feldman MA, Bass EB, et al. Risks and benefits of anticoagulant and antiplatelet medication use before cataract surgery. *Ophthalmology* 2003; 110:1784–1788.
  58. Merritt JC, Bhatt DL. The efficacy and safety of perioperative antiplatelet therapy. *J Thromb Thrombolysis* 2004; 17:21–27.
  59. Lee SW, Park SW, Hong MK, et al. Triple versus dual antiplatelet therapy after coronary stenting: impact on stent thrombosis. *J Am Coll Cardiol* 2005; 46:1833–1837.

ADDRESS: Stephen G. Ellis, MD, Department of Cardiovascular Medicine, F25, Cleveland Clinic, 9500 Euclid Avenue, Cleveland, OH 44195; e-mail ellis@ccf.org.