

**MARTIN A. SAMUELS, MD, DSc (hon), FAAN, MACP\***

Neurologist-in-Chief and Chairman  
Department of Neurology  
Brigham and Women's Hospital  
Professor of Neurology  
Harvard Medical School  
Boston, MA

## 'Voodoo' death revisited: The modern lessons of neurocardiology†

In 1942, Walter Bradford Cannon published a remarkable paper entitled "'Voodoo' Death,"<sup>1</sup> in which he recounted anecdotal experiences, largely from the anthropology literature, of death from fright. These events, drawn from widely disparate parts of the world, had several features in common. They were all induced by an absolute belief that an external force, such as a wizard or medicine man, could, at will, cause demise and that the victim himself had no power to alter this course. This perceived lack of control over a powerful external force is the *sine qua non* for all the cases recounted by Cannon, who postulated that death was caused "by a lasting and intense action of the sympathico-adrenal system." Cannon believed that this phenomenon was limited to soot, that they feel themselves bewildered strangers in a hostile world. Instead of knowledge, they have fertile and unrestricted imaginations which fill their environment with all manner of evil spirits capable of affecting their lives disastrously."

Over the years since Cannon's observations, evidence has accumulated to support his concept that "voodoo" death is, in fact, a real phenomenon, but far from being limited to ancient peoples, may be a basic biologic principle that provides an important clue to understanding the phenomenon of sudden death in modern society as well as providing a window into the world of neurovisceral disease. George Engel collected 160 accounts from the lay press of sudden death that were attributed to disruptive life events.<sup>2</sup> He found that such events could be divided into eight categories: (1) the impact of the collapse or death of a close person; (2) during acute grief; (3) on threat of loss of a close person; (4) during mourning or on an anniversary; (5) on loss of status or self-esteem; (6)

personal danger or threat of injury; (7) after danger is over; and (8) reunion, triumph, or happy ending. Common to all is that they involve events impossible for the victim to ignore and to which the response is overwhelming excitement, giving up, or both.

In 1957, Carl Richter reported on a series of experiments aimed at elucidating the mechanism of Cannon's "voodoo" death.<sup>3</sup> Richter studied the length of time domesticated rats could swim at various water temperatures and found that at a water temperature of 93° these rats could swim for 60 to 80 minutes. However, if the animal's whiskers were trimmed, it would invariably drown within a few minutes. When carrying out similar experiments with fierce, wild rats, Richter noted that a number of factors contributed to the tendency for sudden death, the most important of which were the restraint involved in holding the animals and confinement in the glass swimming jar with no chance of escape. Trimming the rats' whiskers, which destroys possibly their most important proprioceptive mechanism, contributed to the tendency for early demise. In the case of the calm domesticated animals in which restraint and confinement were apparently not significant stressors, shaving the whiskers rendered these animals as fearful as wild rats with a corresponding tendency for sudden death. Electrocardiograms taken during the process showed a bradycardia developing prior to death, and adrenalectomy did not protect the animals. Furthermore, atropine protected some of the animals and cholinergic drugs led to an even more rapid demise. All this was taken as evidence that overactivity of the sympathetic nervous system was not the cause of the death but rather that death was caused by increased vagal tone.

We now know that the apparently opposite conclusions of Cannon and Richter are not mutually exclusive but rather that a generalized autonomic storm, occurring as a result of a life-threatening stressor, will have both sympathetic and parasympathetic effects. The apparent predominance of one over the other depends on the parameter measured (eg, heart rate,

\* Dr. Samuels reported that he has no financial relationships that pose a potential conflict of interest with this article.

† This article is adapted from "Introduction to Neurocardiology" by Martin A. Samuels, chapter 43 in: Mathias CJ, Bannister R, eds. *Autonomic Failure: A Textbook of Clinical Disorders of the Autonomic Nervous System*, 4th ed; 1999:421–427, by permission of Oxford University Press ([www.oup.co.uk](http://www.oup.co.uk)).

blood pressure) and the timing of the observations in relation to the stressor (eg, early events tend to be dominated by sympathetic effects, whereas late events tend to be dominated by parasympathetic effects).

In human beings, one of the easily accessible windows into autonomic activity is the electrocardiogram (ECG). Edwin Byer and colleagues reported six patients whose ECGs showed large upright T waves and long QT intervals.<sup>4</sup> Two of these patients had hypertensive encephalopathy, one had a brainstem stroke with neurogenic pulmonary edema, one had an intracerebral hemorrhage, one had a postpartum ischemic stroke possibly related to toxemia, and one had no history except a blood pressure of 210/110 mm Hg. Based on experimental results of cooling or warming the endocardial surface of the dog's left ventricle, Byer et al concluded that these ECG changes were due to subendocardial ischemia.

Levine reported on several disorders other than ischemic heart disease that could produce ECG changes reminiscent of coronary disease.<sup>5</sup> Among the reported cases was that of a 69-year-old woman who was admitted and remained in coma. Her admission ECG showed deeply inverted T waves in the anterior and lateral precordial leads. An ECG 2 days later showed ST-segment elevation with less deeply inverted T waves, a pattern suggestive of myocardial infarction. However, at autopsy a ruptured berry aneurysm was found and no evidence of myocardial infarction or pericarditis was noted. Levine did not propose a specific mechanism but referred to experimental work on the production of cardiac arrhythmias by basal ganglia stimulation and ST and T-wave changes induced by injecting caffeine into the cerebral ventricle.

Burch et al reported on 17 patients who were said to have "cerebrovascular accidents" (ie, strokes).<sup>6</sup> In 14 of the 17, hemorrhage was demonstrated by lumbar puncture. It is not possible to determine which of these patients had hemorrhagic infarction, intracerebral hemorrhage, and subarachnoid hemorrhage, and no data about the territory of the strokes are available. The essential features of the ECG abnormalities were:

- (1) Long QT intervals in all patients
- (2) Large, usually inverted, T waves in all patients
- (3) U waves in 11 of the 17 patients.

Cropp and Manning reported on the details of the ECG abnormalities in 29 patients with subarachnoid hemorrhage.<sup>7</sup> Twenty-two of these patients survived. Two of those who died had no postmortem examination, leaving five in whom autopsies confirmed the presence of a ruptured cerebral aneurysm. In three of these five, the heart and coronary arteries were said to

be normal, but the details of the pathological examination are not revealed. The point is made that ECG changes seen in the context of neurologic disease do not represent ischemic heart disease but are merely a manifestation of autonomic dysregulation, possibly emanating from a lesion affecting the cortical representation of the autonomic nervous system. The authors argued that Brodmann area 13 on the orbital surface of the frontal lobe and area 24 on the anterior cingulate gyrus were the cortical centers for cardiovascular control.

In contrast to this rather inconclusive clinical data, there is clear evidence that cardiac lesions can be produced as the result of nervous system disease. The concept of visceral organ dysfunction occurring as a result of neurologic stimuli can be traced to Pavlov, who may have introduced the concept of a neurogenic dystrophy. Selye, a student of Pavlov, described an electrolyte-steroid cardiopathy with necroses, referred to as ESCN.<sup>8</sup> His view was that this cardiac lesion was common and often described using different names in the world's literature. He argued that this lesion was distinct from the coagulation necrosis that occurred as a result of ischemic disease, but could exist in the same heart. Selye felt that certain steroids and other hormones created a predisposition for the development of ESCN, but that other factors were required for ESCN to develop. The most effective conditioning steroid was 2-alpha-methyl-9-alpha-chlorocortisol. Among the factors that led to ESCN in steroid-sensitized animals were certain electrolytes (eg, NaH<sub>2</sub>PO<sub>4</sub>), various hormones (eg, vasopressin, adrenaline, insulin, thyroxine), certain vitamins (eg, dihydrotachysterol), cardiac glycosides, surgical interventions (eg, cardiac reperfusion after ischemia), and psychic or nervous stimuli (eg, restraint, fright). The cardiac lesions could not be prevented with adrenalectomy, suggesting that the process, if related to autonomic hyperactivity, must exert its influence by direct neural connection to the heart rather than by a blood-borne route.

Cardiac lesions may be produced in rats by pre-treating with either 2-alpha-methyl-9-alpha-fluorohydrocortisone (fluorocortisol), dihydrotachysterol (calciferol), or thyroxine and then restraining the animals on a board for 15 hours or by using cold stress.<sup>9</sup> Agents that act by inhibition of the catecholamine-mobilizing reflex arc at the hypothalamic level (eg, chlorpromazine) or by blockade of only the circulating, but not the neurogenic, intramyocardial catecholamines (eg, dibenamine) were the least effective in protecting cardiac muscle, whereas those drugs that act by ganglionic blockade (eg, mecamylamine) or by direct intramyocardial catecholamine depletion (eg, reserpine) were

the most effective. Furthermore, it is clear that blood catecholamine levels are often normal but that identical ECG findings are seen with high systemic catecholamines. These clinical and pharmacologic data support the concept that the cardiac necrosis is due to catecholamine toxicity and that catecholamines released directly into the heart via neural connections are much more toxic than those reaching the heart via the bloodstream, though clearly the two routes could be additive in the intact, nonadrenalectomized animal. Intracoronary infusions of epinephrine reproduce the characteristic ECG pattern of neurocardiac disease that is reminiscent of subendocardial ischemia, though no ischemic lesion can be found in the hearts of dogs sacrificed after several months of infusions.<sup>10</sup> In the years that followed, numerous reports emanated from around the world documenting the production of cardiac repolarization abnormalities in the context of various neurologic catastrophes and proposing that this was due to an autonomic storm. It seemed likely that the connection between neuropsychiatric illness and the visceral organs would be provided by the autonomic nervous system.

Melville et al produced ECG changes and myocardial necrosis by stimulating the hypothalamus of cats.<sup>11</sup> With anterior hypothalamic stimulation, parasympathetic responses occurred, with bradycardia predominating. Lateral hypothalamic stimulation produced tachycardia and ST-segment depressions. With intense bilateral and repeated lateral stimulation, persistent, irreversible ECG changes occurred and postmortem examination revealed a stereotyped cardiac lesion characterized by intense cytoplasmic eosinophilia with loss of cross-striations and some hemorrhage. The coronary arteries were normal without occlusion. Although Melville et al referred to this lesion as "infarction," it is probably best to reserve that term for coagulative necrosis caused by ischemia. This lesion is probably identical to Selye's ESCN and would now be called coagulative myocytolysis, myofibrillar degeneration, or contraction band necrosis. More recently, Oppenheimer and Cechetto have mapped the chronotropic organizational structure in the rat insular cortex, demonstrating that sympathetic innervation arises from a more rostral part of the posterior insula than does parasympathetic innervation.<sup>12</sup>

Despite the fact that myocardial damage could definitely be produced in animals, there was little recognition that this actually occurred in human beings with acute neurologic or psychiatric illness until the mid-1960s, when Koskelo et al reported on three patients with ECG changes due to subarachnoid hemorrhage

who were noted on postmortem examination to have several small subendocardial petechial hemorrhages.<sup>13</sup> Connor reported focal myocytolysis in 8% of 231 autopsies, with the highest incidence seen in patients dying of intracranial hemorrhages.<sup>14</sup> The lesion reported by Connor conforms to the descriptions of Selye's ESCN or what might now be called myofibrillar degeneration, coagulative myocytolysis, or contraction band necrosis. Connor pointed out that previous pathologic reports probably overlooked the lesion because it was multifocal, with each individual focus being quite small, requiring extensive tissue sampling. It is clear now that even Connor underestimated the prevalence of the lesion and that serial sections are required to rigorously exclude its presence.

Greenshoot and Reichenbach reported on three new patients with subarachnoid hemorrhage and a review of six prior patients from the same medical center.<sup>15</sup> All nine of these patients had cardiac lesions of varying degrees of severity, ranging from eosinophilia with preservation of cross-striations to transformation of the myocardial cell cytoplasm into dense eosinophilic transverse bands with intervening granularity, sometimes with endocardial hemorrhages. Both the ECG abnormalities and the cardiac pathology could be reproduced in cats given mesencephalic reticular formation stimulation. Adrenalectomy did not protect the hearts, supporting the contention that the ECG changes and cardiac lesion are due to direct intracardiac release of catecholamines.

Hawkins and Clower injected blood intracranially into mice, thereby producing the characteristic myocardial lesions.<sup>16</sup> The number of lesions could be reduced but not obliterated by pretreatment with adrenalectomy and the use of either atropine or reserpine, which suggested that the lesions were attributable in part to sympathetic overactivity (humorally reaching the myocardium from the adrenal and by direct release into the muscle by intracardiac nerves) and in part to parasympathetic overactivity. This supports the concept that the cause is an autonomic storm with both divisions contributing to the pathogenesis.

Jacob et al experimentally produced subarachnoid hemorrhage in dogs and carefully studied the sequential hemodynamic and ultrastructural changes that occurred.<sup>17</sup> The hemodynamic changes occurred in four stages and directly paralleled the effects seen with intravenous norepinephrine injections. These stages were:

- (1) Dramatic rise in systemic blood pressure
- (2) Extreme sinus tachycardia with various arrhythmias (eg, nodal or ventricular tachycardia, bradycardia, atrioventricular block, ventricular

premature beats, ventricular tachycardia, ventricular fibrillation with sudden death), all of which could be suppressed by bilateral vagotomy or orbital frontal resection

(3) Rise in left ventricular pressure parallel to rise in systemic pressure

(4) Up to twofold increase in coronary blood flow.

Ultrastructurally, a series of three stereotyped events occurred that could be imitated exactly with norepinephrine injections. These were:

(1) Migration of intramitochondrial granules containing  $\text{Ca}^{2+}$  to the periphery of the mitochondria

(2) Disappearance of these granules

(3) Myofilament disintegration at the I bands while the density of the I band was increased in the intact sarcomeres.<sup>17</sup>

Partially successful efforts to modify the development of neurocardiac lesions were made by using reserpine pretreatment in mice subjected to simulated intracranial hemorrhage<sup>18</sup> and by Hunt and Gore, who pretreated a group of rats with propranolol and then attempted to produce cardiac lesions with intracranial blood injections.<sup>19</sup> Lesions were found in none of the control animals, in 21 of the 46 untreated rats, and in only 4 of the 22 treated rats.<sup>19</sup> This suggested that neurologic influences via catecholamines may be partly responsible for cardiac cell death due to ischemic causes.

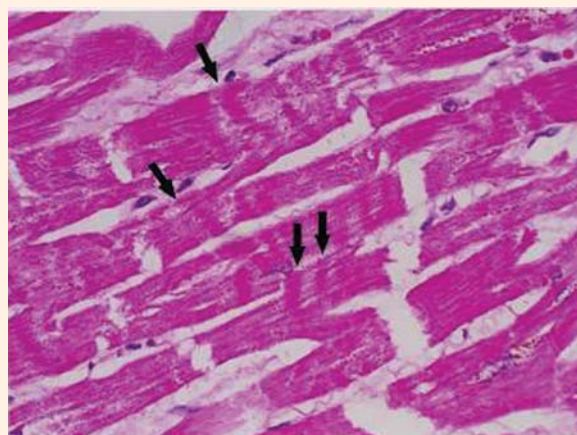
The phenomenology of the various types of myocardial cell death was finally clarified by Baroldi, who pointed out that there were three main patterns of myocardial necrosis:

(1) Coagulation necrosis, the fundamental lesion of infarction, in which the cell loses its capacity to contract and dies in the atonic state with no myofibrillar damage

(2) Colliquative myocytolysis, in which edematous vacuolization with dissolution of myofibrils without hypercontraction occurs in the low-output syndromes

(3) Coagulative myocytolysis, in which the cell dies in a hypercontracted state, with early myofibrillar damage and anomalous irregular cross-band formations.<sup>20</sup>

Coagulative myocytolysis is seen in reperfused areas around regions of coagulation necrosis in transplanted hearts, in "stone hearts," in sudden unexpected and accidental death, and in hearts exposed to toxic levels of catecholamines, such as in patients with pheochromocytoma. This is probably the major lesion described by Selye as ESCN and is clearly the lesion seen in animals and people suffering acute neurologic or psychiatric catastrophes. Although coagu-



**FIGURE 1.** The neurocardiac lesion: contraction band necrosis (arrows), also known as myofibrillar degeneration or coagulative myocytolysis.

lative myocytolysis is probably the preferred term, the terms myofibrillar degeneration and contraction band necrosis are commonly used in the literature. This lesion tends to calcify early and to have a multifocal subendocardial predisposition (**Figure 1**).

It is likely that the subcellular mechanisms underlying the development of coagulative myocytolysis involve calcium entry. Zimmerman and Hulsmann reported that the perfusion of rat hearts with calcium-free media for short periods of time creates a situation such that upon readmission of calcium, there is a massive contracture followed by necrosis and enzyme release.<sup>21</sup> This phenomenon, known as the calcium paradox, can be imitated almost exactly with reoxygenation followed by hypoxemia and reperfusion following ischemia. The latter, called the oxygen paradox, has been linked to the calcium paradox by pathologic calcium entry.<sup>22</sup> This major ionic shift is probably the cause of the dramatic ECG changes seen in the context of neurologic catastrophe, a fact that could explain the phenomenon of sudden unexpected death (SUD) in multiple contexts.

Although SUD is now recognized as a medical problem of major epidemiologic importance, it has generally been assumed that neurologic disease rarely results in SUD. In fact, it has been traditionally taught that neurologic illnesses almost never cause sudden demise, with the only exceptions being the occasional patient who dies during an epileptic convulsion or rapidly in the context of a subarachnoid hemorrhage. Further, it has been assumed that the various SUD syndromes (eg, sudden death in middle-aged men; sudden infant death syndrome [SIDS]; sudden unexpected nocturnal death



syndrome; being frightened to death ["voodoo" death]; sudden death during a seizure; sudden death during natural catastrophe; sudden death associated with drug abuse; sudden death in wild and domestic animals; sudden death during asthma attacks; sudden death during the alcohol withdrawal syndrome; sudden death during grief after a major loss; sudden death during panic attacks; sudden death from mental stress; and sudden death during war) are entirely separate and have no unifying mechanism. For example, it is generally accepted that sudden death in middle-aged men is usually caused by a cardiac arrhythmia (ie, ventricular fibrillation) that results in functional cardiac arrest, while most work on SIDS focuses on respiratory failure.

However, the connection between the nervous system and the cardiopulmonary system provides the unifying link that allows a coherent explanation for most, if not all, of the forms of SUD. Powerful evidence from multiple disparate disciplines allows for a neurologic explanation for SUD.<sup>23</sup>

### ■ NEUROGENIC HEART DISEASE

#### Definition of neurogenic ECG changes

A wide variety of changes in the ECG is seen in the context of neurologic disease. Two major categories of change are regularly noted: (1) arrhythmias and (2) repolarization changes. It is likely that the increased tendency for life-threatening arrhythmias found in patients with acute neurologic disease is due to the repolarization change, which increases the vulnerable period during which an extrasystole would be likely to result in ventricular tachycardia and/or ventricular fibrillation. Thus, the essential and potentially most lethal features of the ECG that are known to change in the context of neurologic disease are the ST segment and T wave, reflecting abnormalities in repolarization. Most often, the changes are seen best in the anterolateral or inferolateral leads. If the ECG is read by pattern recognition by someone who is not aware of the clinical history, it will often be said to present subendocardial infarction or anterolateral ischemia. The ECG abnormalities usually improve, often dramatically, with death by brain criteria.

The phenomenon is not rare. In a series of 100 consecutive stroke patients, 90% showed abnormalities on the ECG, compared with 50% of a control population of 100 patients admitted for carcinoma of the colon.<sup>24</sup> This, of course, does not mean that 90% of stroke patients have neurogenic ECG changes. Obviously, stroke and coronary artery disease have common risk factors, so that many ECG abnormalities in stroke patients represent concomitant atherosclerotic coronary

disease. Nonetheless, a significant number of stroke patients have authentic neurogenic ECG changes.

#### Mechanism of production of neurogenic heart disease

**Catecholamine infusion.** Josué first showed that epinephrine infusions could cause cardiac hypertrophy.<sup>25</sup> This observation has been reproduced on many occasions, documenting that systemically administered catecholamines are associated not only with ECG changes reminiscent of widespread ischemia but with a characteristic pathologic picture in the cardiac muscle that is distinct from myocardial infarction. An identical picture may be found in human beings with chronically elevated catecholamines, as is seen with pheochromocytoma. Patients with stroke often have elevated systemic catecholamine levels, which may, in part, account for the high incidence of cardiac arrhythmias and ECG changes seen in these patients. On light microscopy, these changes range from increased eosinophilic staining with preservation of cross-striations to total transformation of the myocardial cell cytoplasm into dense eosinophilic transverse bands with intervening granularity. In severely injured areas, infiltration of the necrotic debris by mononuclear cells is often noted, sometimes with hemorrhage.

Ultrastructurally, the changes in cardiac muscle are even more widespread than they appear to be on light microscopy. Nearly every muscle cell shows some pathologic alteration, ranging from a granular appearance of the myofibrils to profound disruption of the cell architecture with relative preservation of ribosomes and mitochondria. Intracardiac nerves can be seen, identified by their external lamina, microtubules, neurofibrils, and the presence of intracytoplasmic vesicles. These nerves can sometimes be seen immediately adjacent to an area of myocardial cell damage. The pathologic changes in the cardiac muscle are usually less at a distance from the nerve, often returning completely to normal by a distance of 2 to 4  $\mu\text{m}$  away from the nerve ending.<sup>17</sup>

Myofibrillar degeneration (also known as coagulative myocytolysis and contraction band necrosis) is an easily recognizable form of cardiac injury, distinct in several major respects from coagulation necrosis, the major lesion of myocardial infarction.<sup>20,26</sup> In coagulation necrosis, the cells die in a relaxed state without prominent contraction bands. This is not visible by any method for many hours or even days. Calcification occurs only late and the lesion elicits a polymorphonuclear cell response. In stark contrast, in myofibrillar degeneration, the cells die in a hypercontracted state with prominent contraction bands

(Figure 1). The lesion is visible early, perhaps within minutes of its onset. It elicits a mononuclear cell response and may calcify almost immediately.<sup>26,27</sup>

**Stress plus or minus steroids.** A similar, if not identical, cardiac lesion can be produced using various models of “stress.” This concept was applied to the heart when Selye published his monograph, *The Chemical Prevention of Cardiac Necrosis*, in 1958.<sup>8</sup> He found that cardiac lesions probably identical to those described above could be produced regularly in animals that were pretreated with certain steroids, particularly 2-alpha-methyl-9-alpha-fluorohydrocortisone (fluorocortisol), and then subjected to various types of stress. Other hormones, such as dihydrotachysterol (calciferol) and thyroxine, could also sensitize animals for stress-induced myocardial lesions, but less potently than fluorocortisol. This so-called stress could be of multiple types, including restraint, surgery, bacteremia, vagotomy, toxins, and others. He believed that the “first mediator” in translating these widely disparate stimuli into a stereotyped cardiac lesion was the hypothalamus and that it, by its control over the autonomic nervous system, caused the release of certain agents that were toxic to the myocardial cell. Since Selye’s original work, similar experiments have been repeated in many different types of laboratory animals with comparable results. Although the administration of exogenous steroids facilitates the production of cardiac lesions, it is clear that stress alone can result in the production of morphologically identical lesions.

Whether a similar pathophysiology could ever be operable in human beings is, of course, of great interest. Many investigators have speculated on the role of “stress” in the pathogenesis of human cardiovascular disease and, in particular, on its relationship to the phenomenon of SUD. A few autopsies on patients who experienced sudden death have shown myofibrillar degeneration. Cebelin and Hirsch reported on a careful retrospective analysis of the hearts of 15 victims of physical assault who died as a direct result of the assault, but without sustaining internal injuries.<sup>28</sup> Eleven of the 15 individuals showed myofibrillar degeneration. Age-matched and cardiac disease-matched controls showed little or no evidence of this change. This appears to represent a human stress cardiomyopathy.<sup>28</sup> Whether or not such assaults can be considered murder has become an interesting legal correlate of the problem.

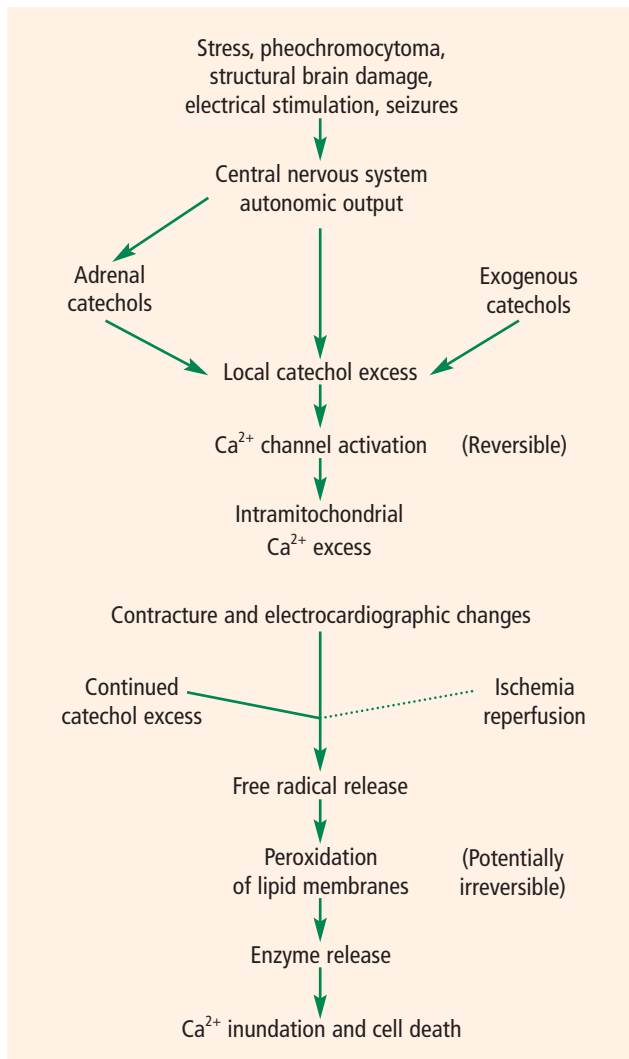
Since the myofibrillar degeneration is predominantly subendocardial, it may involve the cardiac conducting system, thus predisposing to cardiac arrhythmias. This lesion, combined with the propensity of catecholamines to produce arrhythmias even in a nor-

mal heart, may well raise the risk of a serious arrhythmia. This may be the major immediate mechanism of sudden death in many neurologic circumstances, such as subarachnoid hemorrhage, stroke, epilepsy, head trauma, psychological stress, and increased intracranial pressure. Even the arrhythmogenic nature of digitalis may be largely mediated by the central nervous system. Further evidence for this is the antiarrhythmic effect of sympathetic denervation of the heart for cardiac arrhythmias of many types.

Furthermore, it is known that the stress-induced myocardial lesions can be prevented by sympathetic blockade using many different classes of antiadrenergic agents, most notably ganglionic blockers such as mecamylamine and catecholamine-depleting agents such as reserpine.<sup>9</sup> This suggests that catecholamines, either released directly into the heart by sympathetic nerve terminals or reaching the heart through the bloodstream after release from the adrenal medulla, may be excitotoxic to myocardial cells.

Reversible left ventricular dysfunction affecting the apex out of proportion to the base is known to occur in human beings (predominantly older women) after emotional stress.<sup>29</sup> This so-called myocardial stunning may present with chest pain, ECG abnormalities, or frank heart failure (pulmonary edema) and is usually associated with a modest myocardial enzyme (troponin) leak. Endocardial biopsies show contraction bands, and plasma catecholamines are usually found to be elevated.<sup>30</sup> The four-chamber view of the echocardiogram or the ventriculogram characteristically shows a dilated apex and relatively uninvolved base, producing an appearance that is reminiscent of the Japanese octopus trapping pot (takotsubo), which has led this phenomenon to be named takotsubo-like cardiomyopathy.<sup>31</sup> Takotsubo-like cardiomyopathy is known to increase in frequency around the time of large-scale stressors, such as earthquakes.<sup>32</sup> It is likely that takotsubo-like cardiomyopathy represents the tip of an iceberg, below which lurks a much larger problem of neurally induced visceral organ damage, of which severe left ventricular apical ballooning is only one small, albeit dramatic, component.

**Nervous system stimulation.** Nervous system stimulation produces cardiac lesions histologically indistinguishable from those just described for stress- and catecholamine-induced cardiac damage. It has been known for a long while that stimulation of the hypothalamus can lead to autonomic cardiovascular disturbances, and many years ago, lesions in the heart and gastrointestinal tract had been produced using hypothalamic stimulation. It has been clearly demonstrated that stimula-



**FIGURE 2.** Cascade of events leading to neurocardiac damage.

tion of the lateral hypothalamus produces hypertension or ECG changes reminiscent of those seen in patients with central nervous system damage of various types. Furthermore, this effect on the blood pressure and ECG can be completely prevented by C2 spinal section and stellate ganglionectomy, but not by vagotomy, suggesting that the mechanism of the electrocardiographic changes is sympathetic rather than parasympathetic or humoral. Stimulation of the anterior hypothalamus produces bradycardia, an effect that can be blocked by vagotomy. Unilateral hypothalamic stimulation does not result in histologic evidence of myocardial damage by light microscopy, but bilateral prolonged stimulation regularly produces myofibrillar degeneration indistinguishable from that produced by catecholamine injections and stress, as previously described.<sup>11</sup>

Other methods of producing cardiac lesions of this type include stimulation of the limbic cortex, the mesencephalic reticular formation, the stellate ganglion, and regions known to elicit cardiac reflexes such as the aortic arch. Experimental intracerebral and subarachnoid hemorrhages can also result in cardiac contraction band lesions. These neurogenic cardiac lesions will occur even in an adrenalectomized animal, although they will be somewhat less pronounced.<sup>16</sup> This evidence argues strongly against an exclusively humoral mechanism in the intact organism. High levels of circulating catecholamines exaggerate the ECG findings and myocardial lesions, but high circulating catecholamine levels are not required for the production of pathologic changes. These ECG abnormalities and cardiac lesions are stereotyped and identical to those found in the stress and catecholamine models already outlined. They are not affected by vagotomy and are blocked by maneuvers that interfere with the action of the sympathetic limb of the autonomic nervous system, such as C2 spinal section, stellate ganglion blockade, and administration of antiadrenergic drugs such as propranolol.

It seems clear that the insula is the region of the cerebral cortex that most directly affects cardiac structure and function. There is a great deal of clinical evidence that insular diseases are the most likely to produce neurally induced cardiac changes, though the issue of lateral dominance of one insula over the other has not yet been completely settled.<sup>33-37</sup>

The histologic changes in the myocardium range from normal muscle on light microscopy to severely necrotic (but not ischemic) lesions with secondary mononuclear cell infiltration. The findings on ultrastructural examination are invariably more widespread, often involving nearly every muscle cell, even when the light microscopic appearance is unimpressive. The ECG findings undoubtedly reflect the total amount of muscle membrane affected by the pathophysiologic process. Thus, the ECG may be normal when the lesion is early and demonstrable only by electron microscopy. Conversely, the ECG may be grossly abnormal when only minimal findings are present by light microscopy, since the cardiac membrane abnormality responsible for the ECG changes may be reversible. Cardiac arrhythmias of many types may also be elicited by nervous system stimulation along the outflow of the sympathetic nervous system.

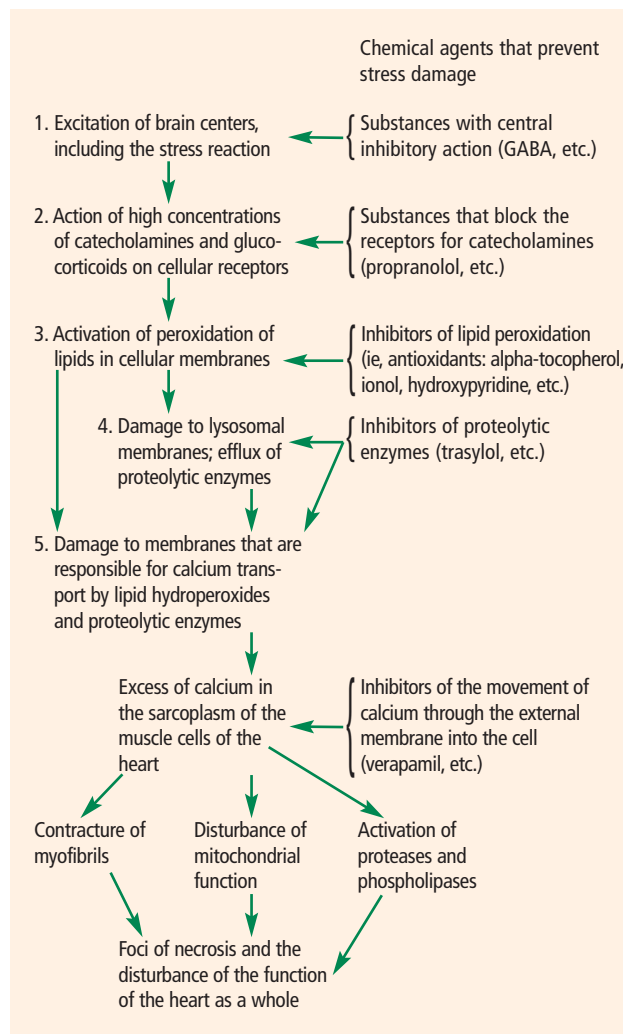
**Reperfusion.** The fourth, and last, model for the production of myofibrillar degeneration is reperfusion, as is commonly seen in patients dying after a period of time on a left ventricular assist pump for cardiac surgery. Similar lesions are seen in hearts that were reper-

fused using angioplasty or fibrinolytic therapy. The mechanism by which reperfusion of ischemic cardiac muscle produces myofibrillar degeneration involves entry of calcium after a period of relative deprivation.<sup>38</sup>

Sudden calcium influx by one of several possible mechanisms (eg, a period of calcium deficiency with loss of intracellular calcium, a period of anoxia followed by reoxygenation of the electron transport system, a period of ischemia followed by reperfusion, or opening of the receptor-operated calcium channels by excessive amounts of locally released norepinephrine) may be the final common pathway by which the irreversible contractures occur, leading to myofibrillar degeneration. Thus reperfusion-induced myocardial cell death may be a form of apoptosis (programmed cell death) analogous to that seen in the central nervous system wherein excitotoxicity with glutamate results in a similar, if not identical, series of events.<sup>39</sup>

The precise cellular mechanism for the ECG change and the histologic lesion may well reflect the effects of large volumes of norepinephrine released into the myocardium from sympathetic nerve terminals.<sup>40</sup> The fact that the cardiac necrosis is greatest near the nerve terminals in the endocardium and is progressively less severe as one samples muscle approaching the epicardium provides further evidence that catecholamine toxicity produces the lesion.<sup>15</sup> This locally released norepinephrine is known to stimulate synthesis of adenosine 3',5'-cyclic phosphate, which in turn results in the opening of the calcium channel with influx of calcium and efflux of potassium. This efflux of potassium could explain the peaked T waves (a hyperkalemic pattern) often seen early in the evolution of neurogenic ECG changes.<sup>17</sup> The actin and myosin filaments interact under the influence of calcium but do not relax unless the calcium channel closes. Continuously high levels of norepinephrine in the region may result in failure of the calcium channel to close, leading to cell death, and finally to leakage of enzymes out of the myocardial cell. Free radicals released as a result of reperfusion after ischemia or by the metabolism of catecholamines to the known toxic metabolite adrenochrome may contribute to cell membrane destruction, leading to leakage of cardiac enzymes into the blood.<sup>41,42</sup> Thus, the cardiac toxicity of locally released norepinephrine would represent a continuum ranging from a brief reversible burst of ECG abnormalities to a pattern resembling hyperkalemia and then, finally, to an irreversible failure of the muscle cell with permanent repolarization abnormalities, or even the occurrence of transmural cardiac necrosis with Q waves seen on the ECG.

Histologic changes would also represent a continuum



**FIGURE 3.** Therapeutic approaches aimed at preventing neurocardiac damage. GABA = gamma-aminobutyric acid.

ranging from complete reversibility in a normal heart through mild changes seen best with electron microscopy to severe myocardial cell necrosis with mononuclear cell infiltration and even hemorrhages. The level of cardiac enzymes released and the ECG changes would roughly correlate with the severity and extent of the pathologic process. This explanation, summarized in **Figure 2**, would tie together all the observations in the models discussed here (catecholamine infusion, stress plus or minus steroids, nervous system stimulation, and reperfusion).

## CONCLUSION

There is powerful evidence suggesting that overactivity of the sympathetic limb of the autonomic nervous system is the common phenomenon that links the



major cardiac and pulmonary pathologies seen in neurologic catastrophes. These profound effects on the heart and lungs may contribute in a major way to the mortality rates of many primarily neurologic conditions such as subarachnoid hemorrhage, status epilepticus, and head trauma. These phenomena may also be important in the pathogenesis of SUD in adults, sudden infant death, sudden death during asthma attacks, cocaine- and amphetamine-related deaths, and sudden death during the alcohol withdrawal syndrome, all of which may be linked by stress and catecholamine toxicity.

Investigations aimed at altering the natural history of these events using catecholamine receptor blockade, calcium channel blockers, free radical scavengers, and antioxidants are ongoing in many centers around the world and are summarized in **Figure 3**.

■ REFERENCES

1. Cannon WB. "Voodoo" death. *American Anthropologist* 1942; 44:169-181.
2. Engel G. Sudden and rapid death during psychological stress. *Ann Intern Med* 1971; 74:771-782.
3. Richter CP. On the phenomenon of sudden death in animals and man. *Psychosom Med* 1957; 19:191-198.
4. Byer E, Ashman R, Toth LA. Electrocardiogram with large upright T wave and long Q-T intervals. *Am Heart J* 1947; 33:796-801.
5. Levine HD. Non-specificity of the electrocardiogram associated with coronary heart disease. *Am J Med* 1953; 15:344-350.
6. Burch GE, Meyers R, Abildskov JA. A new electrocardiographic pattern observed in cerebrovascular accidents. *Circulation* 1954; 9:719-723.
7. Cropp GJ, Manning GW. Electrocardiographic changes simulating myocardial ischemia and infarction associated with spontaneous intracranial hemorrhage. *Circulation* 1960; 22:25-38.
8. Selye H. *The Chemical Prevention of Cardiac Necrosis*. New York, NY: Ronald Press; 1958.
9. Raab W, Stark E, MacMillan WH, Gigue WR. Sympathogenic origin and antiadrenergic prevention of stress-induced myocardial lesions. *Am J Cardiol* 1961; 8:203-211.
10. Barger AC, Herd JA, Liebowitz MR. Chronic catheterization of coronary artery induction of ECG pattern of myocardial ischemia by intracoronary epinephrine. *Proc Soc Exp Biol Med* 1961; 107:474-477.
11. Melville KI, Blum B, Shister HE, et al. Cardiac ischemic changes and arrhythmias induced by hypothalamic stimulation. *Am J Cardiol* 1963; 12:781-791.
12. Oppenheimer SM, Cechetto DF. Cardiac chronotropic organization of the rat insular cortex. *Brain Res* 1990; 533:66-72.
13. Koskelo P, Punsar S, Sipila W. Subendocardial haemorrhage and ECG changes in intracranial bleeding. *Br Med J* 1964; 1:1479-1483.
14. Connor RCR. Myocardial damage secondary to brain lesions. *Am Heart J* 1969; 78:145-148.
15. Greenshoot JH, Reichenbach DD. Cardiac injury and subarachnoid hemorrhage. *J Neurosurg* 1969; 30:521-531.
16. Hawkins WE, Clower BR. Myocardial damage after head trauma and simulated intracranial haemorrhage in mice: the role of the autonomic nervous system. *Cardiovasc Res* 1971; 5:524-529.
17. Jacob WA, Van Bogaert A, DeGroot-Lasseel MHA. Myocardial ultrastructural and haemodynamic reactions during experimental subarachnoid hemorrhage. *J Mol Cell Cardiol* 1972; 4:287-298.
18. McNair JL, Clower BR, Sanford RA. The effect of reserpine pretreatment on myocardial damage associated with simulated intracra-

19. Hunt D, Gore I. Myocardial lesions following experimental intracranial hemorrhage: prevention with propranolol. *Am Heart J* 1972; 83:232-236.
20. Baroldi F. Different morphological types of myocardial cell death in man. In: Fleckstein A, Rona G, eds. *Recent Advances in Studies in Cardiac Structure and Metabolism. Pathophysiology and Morphology of Myocardial Cell Alteration*. Baltimore, MD: University Park Press; 1975:385-397.
21. Zimmerman ANA, Hulsmann WC. Paradoxical influence of calcium ions on the permeability of the cell membranes of the isolated rat heart. *Nature* 1966; 211:616-647.
22. Hearse DJ, Humphrey SM, Bullock GR. The oxygen paradox and the calcium paradox: two facets of the same problem? *J Mol Cell Cardiol* 1978; 10:641-668.
23. Samuels MA. Neurally induced cardiac damage. *Neurol Clin* 1993; 11:273-292.
24. Dimant J, Grob D. Electrocardiographic changes and myocardial damage in patients with acute cerebrovascular accidents. *Stroke* 1977; 8:448-455.
25. Josué O. Hypertrophie cardiaque causée par l'adrenaline et la toxine typhique. *C R Soc Biol (Paris)* 1907; 63:285-287.
26. Karch SB, Billingham ME. Myocardial contraction bands revisited. *Hum Pathol* 1986; 17:9-13.
27. Rona G. Catecholamine cardiotoxicity. *J Mol Cell Cardiol* 1985; 17:291-306.
28. Cebelin M, Hirsch CS. Human stress cardiomyopathy. *Hum Pathol* 1980; 11:123-132.
29. Ako J, Krishnankutty S, Farouque O, Honda Y, Fitzgerald PJ. Transient left ventricular dysfunction under severe stress: brain-heart relationship revisited. *Am J Med* 2006; 19:10-17.
30. Wittstein IS, Thiemann DR, Lima JAC, et al. Neurohumoral features of myocardial stunning due to sudden emotional stress. *N Engl J Med* 2005; 352:539-548.
31. Kawai S, Suzuki H, Yamaguchi H, et al. Ampulla cardiomyopathy ("takotsubo" cardiomyopathy): reversible left ventricular dysfunction with ST segment elevation. *Jpn Circ J* 2000; 64:156-159.
32. Watanabe H, Kodama M, Okura Y, et al. Impact of earthquakes on Takotsubo cardiomyopathy [letter]. *JAMA* 2005; 294:305-307.
33. Laowattana S, Zeger SL, Lima JAC, Goodman SN, Wittstein IS, Oppenheimer SM. Left insular stroke is associated with adverse cardiac outcome. *Neurology* 2006; 66:477-483.
34. Ay H, Koroshetz WJ, Benner T, et al. Neuroanatomic correlates of stroke-related myocardial injury. *Neurology* 2006; 66:1325-1329.
35. Oppenheimer SM. Cerebrogenic cardiac arrhythmias: cortical lateralization and clinical significance. *Clin Auton Res* 2006; 16:6-11.
36. Cechetto DF, Saper CB. Evidence for a viscerotopic sensory representation in the cortex and thalamus in the rat. *J Comp Neurol* 1987; 262:27-45.
37. Tokgozoglul SL, Batur MK, Topcuoglu MA, Saribas O, Kes S, Oto A. Effects of stroke localization on cardiac autonomic balance and sudden death. *Stroke* 1999; 30:1307-1311.
38. Braunwald E, Kloner RA. Myocardial reperfusion: a double-edged sword? *J Clin Invest* 1985; 76:1713-1719.
39. Gottlieb R, Burleson KO, Kloner RA, et al. Reperfusion injury induces apoptosis in rabbit cardiomyocytes. *J Clin Invest* 1994; 94:1621-1628.
40. Eliot RS, Todd GL, Pieper GM, Clayton FC. Pathophysiology of catecholamine-mediated myocardial damage. *J S C Med Assoc* 1979; 75:513-518.
41. Meerson FZ. Pathogenesis and prophylaxis of cardiac lesions in stress. *Adv Myocardiol* 1983; 4:3-21.
42. Singal PK, Kapur N, Dhillon KS, Beamish RE, Dhalla NA. Role of free radicals in catecholamine-induced cardiomyopathy. *Can J Physiol Pharmacol* 1982; 60:1390-1397.

**Address:** Martin A. Samuels, MD, Neurologist-in-Chief, Department of Neurology, Brigham and Women's Hospital, 75 Francis Street, BB204, Boston, MA 02115; msamuels@partners.org.