

The painful shoulder: When to inject and when to refer

ABSTRACT

Physicians can usually diagnose the cause of shoulder pain by performing a focused history and physical examination and ordering anteroposterior and lateral radiographs. Treatment depends on the cause and can include physical therapy, injections of corticosteroids into the joint space or bursa, and surgery. This paper reviews the diagnosis and treatment of impingement syndrome, adhesive capsulitis, rotator cuff tears, and arthritis of the glenohumeral joint and acromioclavicular (AC) joint.

KEY POINTS

From the history and physical examination, the examiner should be able to determine whether the shoulder pain is from the AC joint, glenohumeral joint, or rotator cuff. A variety of physical maneuvers (discussed in this paper) can help pinpoint the cause.

Impingement syndrome and rotator cuff tears cause most of their pain when the arm is elevated.

Physical therapy is the mainstay of treatment for impingement syndrome. The response to a corticosteroid injection into the subacromial space for this problem is unpredictable. If the pain does not improve with 3 months of physical therapy and a subacromial corticosteroid injection, surgery can be considered.

If a patient has a rotator cuff tear that is amenable to surgical repair, generally no more than two subacromial injections are given, because these could potentially weaken the remaining tendon and worsen the outcome of rotator cuff repair.

MANY PHYSICIANS find shoulder pain difficult to sort out and treat. However, most cases can be diagnosed in a 5-minute history and physical examination and treated with a combination of physical therapy, injections, and time. Only in select cases is surgery required.

This article will review the five most common diagnoses responsible for shoulder pain, explain a simple method for making the correct diagnosis quickly, and review the treatment options for each diagnosis. I discuss approaches and rationale for corticosteroid injections into the shoulder area and when to refer patients to an orthopedic surgeon.

FINDING THE CAUSE OF PAIN IN THE SHOULDER

Shoulder pain is a common complaint in patients over age 40. The most common causes of chronic shoulder pain in this age group are:

- Impingement syndrome—the pathologic process whereby the rotator cuff is compressed against the acromion during arm elevation, causing bursitis, tendinitis, and eventually a rotator cuff tear
- Rotator cuff tears
- Adhesive capsulitis (also called frozen shoulder)—any painful loss of shoulder motion that cannot be attributed to a bony abnormality
- Arthritis of the glenohumeral joint and acromioclavicular (AC) joint.

Questions to ask the patient

The first step in determining the cause of a patient's shoulder pain is to take a thorough history, which should include time of onset of the

patient's symptoms and the relationship to any trauma or new strenuous activity that preceded the pain. From the history and physical, the examiner should be able to determine whether the shoulder pain is from the AC joint, the glenohumeral joint, or the rotator cuff.

When did the pain start? Most patients try to find a direct relationship between their pain and an obvious injury, but careful questioning can determine whether the pain started immediately after the trauma or if it developed several days later. This information can be important when distinguishing between adhesive capsulitis, which tends to have a more gradual onset, and a traumatic rotator cuff tear, which causes pain immediately.

Which activities particularly aggravate the pain, and which positions help relieve it? Impingement syndrome and rotator cuff tears cause most of their pain with overhead activities, while activities performed with the elbow at the side are less painful. AC joint arthritis causes pain when the arm is brought across the body, or during weightlifting activities such as the bench press and military press. Adhesive capsulitis and arthritis cause pain with all motions of the shoulder, particularly when reaching behind the back or attempting to reach overhead.

A common complaint of patients with any shoulder disorder is night pain, described by many as a steady ache that wakes them up in the middle of the night. Although this information may not be helpful in establishing a diagnosis, patients often appreciate the reassurance that night pain is common and will get better with treatment.

Where does it hurt? AC joint arthritis is painful on the top of the shoulder; other shoulder disorders can cause pain to radiate down to the middle of the arm. Rotator cuff tears and impingement syndrome cause pain on the front and side of the shoulder, and patients often grab the whole side of the shoulder when trying to describe where the pain is located.

Patients with arthritis have less-specific areas of pain, as do patients with adhesive capsulitis. The main generator of pain in these patients is movement at the extremes of motion in all directions, due to the stiffness in their shoulders. Patients may describe the pain

as radiating to the scapula and neck if the scapulothoracic motion is compensating for a loss in glenohumeral motion.

Also, many patients complain of pain that radiates down to the elbow and fingers in no dermatomal pattern, and they say that the hand or arm feels swollen at times. Although these general complaints do not help the physician in making a diagnosis, they should not be used as evidence of malingering or of nerve impingement until the common shoulder disorders are considered thoroughly. To illustrate this point, one study found that 34 patients diagnosed with both impingement syndrome and cervical neck pain had complete resolution of their neck pain after a subacromial injection.¹

Carpal tunnel syndrome or other entrapment neuropathies can coexist with shoulder disorders, however, and they should be investigated with the appropriate physical maneuvers (see below).

Physical examination

Range of motion. One can get an idea of whether the problem is in the rotator cuff or the glenohumeral joint by testing the patient's range of motion in three planes. If the opposite side is free of symptoms, the range of motion on the affected side should be compared with that on the normal side. If the patient cannot move his or her arm through its full active range of motion, then the examiner should assess for a difference between passive motion and active motion.

Glenohumeral problems will limit both active and passive painless motion in forward elevation, internal rotation, and external rotation. You can also measure abduction, but it does not help distinguish any functional clinical deficit with more precision than simply measuring how high the patient can elevate the arm above the shoulder. Impingement syndrome and rotator cuff tears will limit the patient's active motion, but the passive motion should not be much different than in the normal shoulder.

Pain can often inhibit full passive motion, so I recommend laying the patient supine when testing forward elevation or external rotation if these motions are abnormal in the sitting position. In this position, the patient is

Patients with rotator cuff tears or impingement often grab the whole side of the shoulder when describing where the pain is located

less likely to contract his or her shoulder muscles while the examiner moves the arm, thereby causing less pain.

Palpation. Tenderness of the rotator cuff insertion on the greater tuberosity is uncommon in adhesive capsulitis or arthritis, and therefore this sign can be a useful tool in establishing a diagnosis. Beware, however, of the patient who has tenderness throughout the shoulder in no particular anatomic distribution. This finding suggests a diagnosis unrelated to the shoulder, such as fibromyalgia; a more detailed examination looking for myofascial tender points should be done. Fibromyalgia does not cause isolated regional pain.

In many patients with a rotator cuff tear, palpation of the rotator cuff insertion while the humerus is gently rotated internally and externally can elicit crepitus.

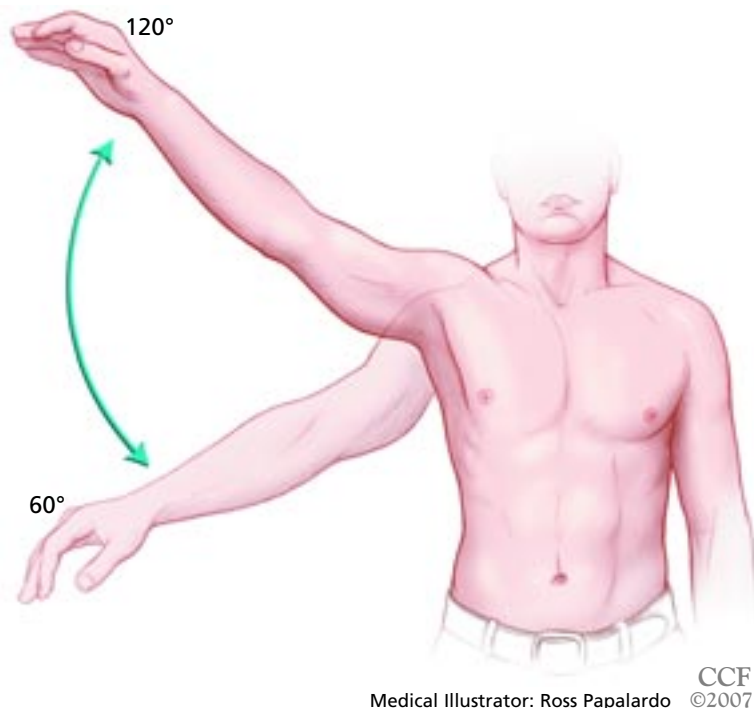
The painful arc sign may also be positive in a patient with a cuff tear. The patient is asked to elevate the arm in the scapular plane as high as possible and then return it to the side. The test is positive if the patient experiences pain or catching between 60 and 120 degrees (FIGURE 1).

The drop-arm sign is another useful test for rotator cuff tears. The examiner asks the patient to elevate the arm in the plane of the scapula fully and then return it to the side slowly. Alternatively, some authors suggest passive elevation of the arm and then ask the patient to lower it. If the patient drops the arm suddenly, this is considered a positive drop-arm sign.

The Neer impingement sign can be used to diagnose impingement syndrome or a rotator cuff tear.² While the patient is supine or sitting, the examiner passively elevates the arm above the patient's head. If this elicits pain in the front of the shoulder, then the patient has a positive impingement sign.

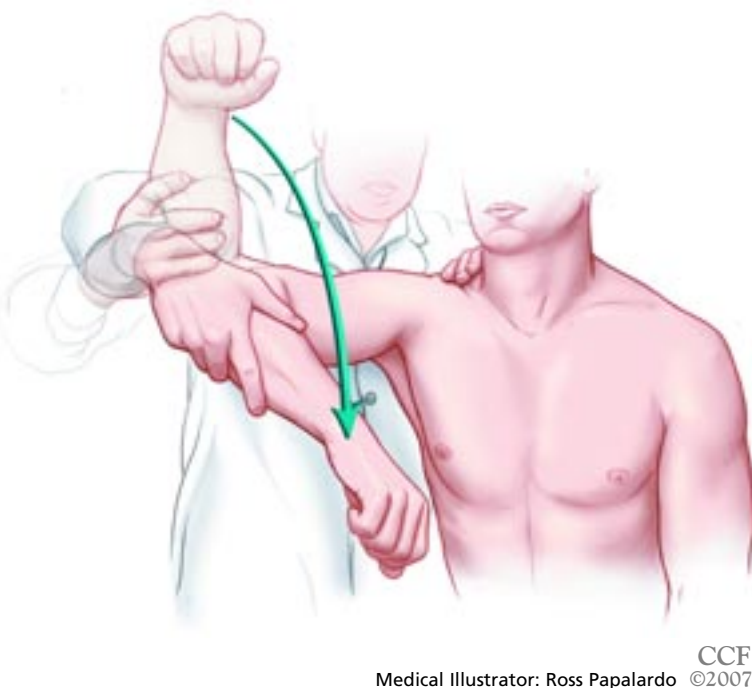
The Hawkins impingement sign is another method commonly used to diagnose impingement. The patient's arm is abducted 90 degrees in neutral rotation and then rotated between internal and neutral rotation. If the patient has pain with internal rotation, this is a positive Hawkins impingement sign (FIGURE 2).

Rotator cuff strength should be assessed to diagnose full-thickness, large rotator cuff tears. Partial-thickness tears or small full-



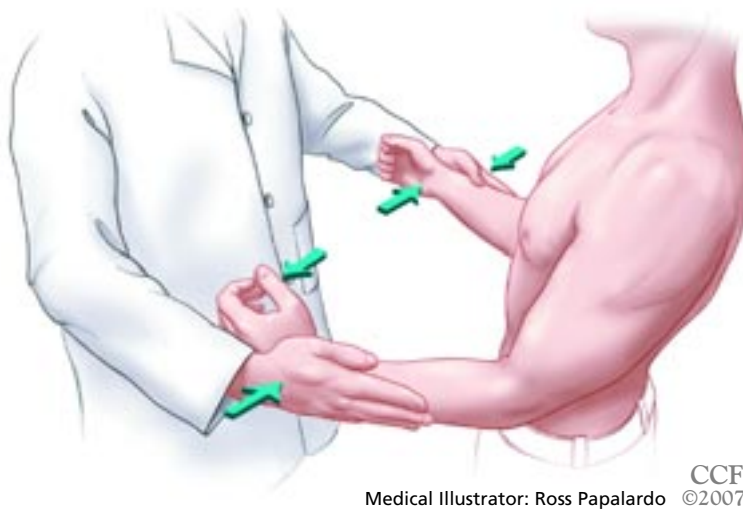
CCF
Medical Illustrator: Ross Papalardo ©2007

FIGURE 1. A painful arc sign is positive when the patient experiences pain during active forward flexion between 60 and 120 degrees.



CCF
Medical Illustrator: Ross Papalardo ©2007

FIGURE 2. The Hawkins impingement sign is positive if the patient's pain is reproduced when the arm is internally rotated while being kept abducted ninety degrees.



CCF
Medical Illustrator: Ross Papalardo ©2007

FIGURE 3. External rotation strength is tested bilaterally with the patient's arms at the side and elbows flexed ninety degrees.

thickness tears are unlikely to cause appreciable weakness on examination, or at least any weakness that the examiner can confidently say is not confounded by pain inhibition.

First, the patient's arm should be held at the side and passively externally rotated as far as possible. The patient is asked to hold the arm in that position. If he cannot, and the arm rotates towards his abdomen, then the patient has a positive lag sign, which is likely caused by a large supraspinatus and infraspinatus tear.

Next, both arms should then be held at the side in neutral rotation with the elbows bent 90 degrees. The patient is asked to externally rotate the arm against the examiner's hand, and the patient's external rotation strength is compared with that in the normal arm (FIGURE 3). Any difference that is not confounded by shoulder pain should be attributed to a rotator cuff tear.

According to a recent study on the accuracy of many different diagnostic clinical tests for impingement and rotator cuff tears, the Neer impingement sign was the best test for the diagnosis of bursitis or a partial rotator cuff tear.³ It had a sensitivity of 85.7%, a specificity of 49.2%, a positive predictive value of 20.9%, and a negative predictive value of 95.7%. More importantly, if the painful arc sign, drop-arm test, and external rotation strength test were abnormal, then the posttest probability of the patient having a rotator cuff tear was 91%.

Patients with a positive drop-arm test, painful arc sign, and external rotation weakness have a 91% chance of having a rotator cuff tear

Radiographs

Anteroposterior (AP) and axillary lateral radiographs of the shoulder should be obtained if the patient has any loss of motion, to distinguish between osteoarthritis and adhesive capsulitis.

Radiographs can confirm the diagnosis of AC joint arthritis; however, many patients have asymptomatic AC joint-space narrowing on radiography, so the clinician should not make this diagnosis by radiography alone.

Radiographs cannot be used to visualize the rotator cuff, but cyst formation in the greater tuberosity or superior migration of the humeral head in relation to the glenoid are both consistent with rotator cuff tears.⁴

Radiographs can also show osteophytes on the undersurface of the acromion, which are consistent with a diagnosis of impingement syndrome.

A magnetic resonance imaging scan should be obtained if the clinician suspects a rotator cuff tear or if the patient has persistent pain after a 3-month course of physical therapy.

Consider other conditions

At the end of the physical examination, the clinician should also consider other, less-common shoulder conditions and conditions not related to the shoulder as potential causes of the patient's shoulder pain.

Other causes of shoulder pain include:

- Fracture
- Chronic posterior dislocation
- Infection
- Calcific tendinitis
- Biceps tendinitis
- Fibromyalgia (in the setting of generalized pain)
- Instability.

Causes of referred shoulder pain include:

- Cervical disk disease
- Pancoast tumor
- Thoracic outlet syndrome
- Hepatic disease
- Diaphragmatic irritation.

■ DIAGNOSTIC (LIDOCAINE) INJECTIONS

Some patients may not have findings on the history and physical examination that are typical for any of the common diagnoses listed above. Patients who have a low tolerance to

Diagnosis and treatment algorithm for common causes of shoulder pain

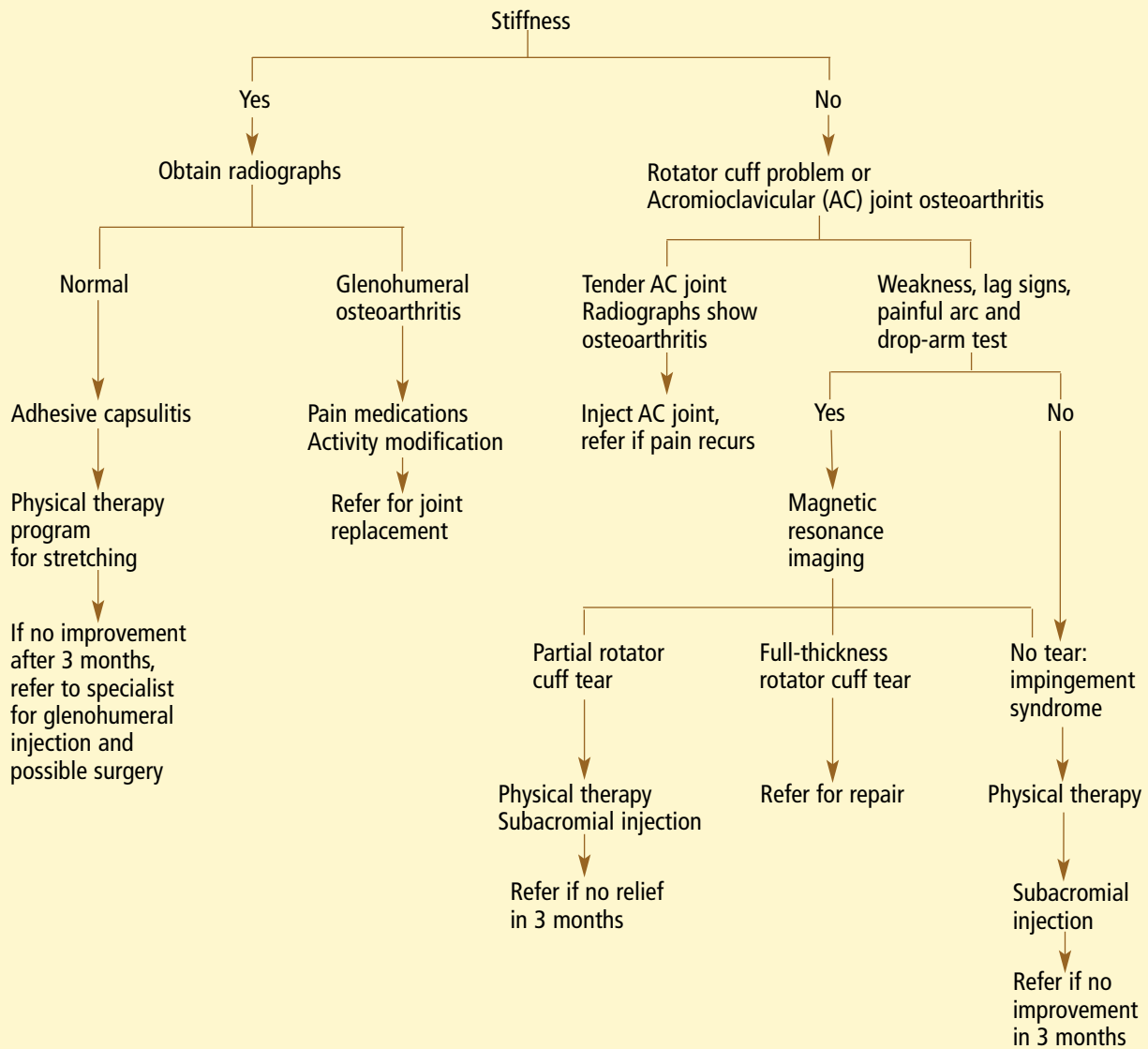


FIGURE 4.

pain and who resist most physical maneuvers because of their pain are difficult to treat because the examiner cannot distinguish between adhesive capsulitis and rotator cuff problems.

If the examiner can eliminate the patient's pain with a subacromial lidocaine injection, then passive range of motion and rotator cuff strength can be assessed more accurately. An injection in the subacromial bursa should eliminate the shoulder pain and allow for full motion of the shoulder if the

patient has a rotator cuff tear or impingement syndrome. Persistent stiffness after the injection is consistent with adhesive capsulitis. In addition, once pain is eliminated, a strength examination can be repeated to help distinguish between impingement syndrome and a rotator cuff tear. However, if the injection is placed into the deltoid muscle or rotator cuff tendon rather than the subacromial bursa, then the patient may not obtain pain relief.⁵

AC joint arthritis also frequently coexists with rotator cuff problems, and the diagnosis

is more difficult to rule out because radiographs often demonstrate severe disease in patients without symptoms. A selective injection in this small joint can help the examiner distinguish between the two conditions; however, this method can be misleading due to the high likelihood of anesthetizing the subacromial bursa during an AC joint injection. One study showed that the needle was placed correctly in the AC joint only 37% of the time.⁶

■ THERAPEUTIC (CORTICOSTEROID) INJECTIONS

An algorithm for the diagnosis and treatment of common causes of shoulder pain is shown in **FIGURE 4**.

Injections for impingement syndrome

The mainstay of treatment for impingement syndrome is a physical therapy program that focuses first on stretching exercises and then moves forward to a graduated strengthening program as pain permits. Most patients (54%–82%) respond to this treatment alone, though it may take 3 to 4 months for the pain to subside.^{7–10}

Different studies gave different results as to the benefit of subacromial injections of corticosteroids for impingement syndrome. One prospective, randomized double-blind study with 40 patients¹¹ found that 84% of patients who received steroid injections had less pain after 33 weeks of follow-up, compared with only 36% of patients who received placebo. In addition, 15 patients in the treatment group did not have an impingement sign at final follow-up, compared with only 4 patients in the control group. Another randomized controlled trial with 58 patients found increased forward flexion (148 degrees vs 133 degrees) 2 weeks after steroid injection, but none of the other subsequent outcome measurements were different after further follow-up.¹² Other studies had the same conflicting results.^{13–16}

One explanation for the difference in outcomes in these studies could be that subacromial injections are difficult to give: one study found that the needle was accurately placed in only 70% of injections.¹⁷

The addition of a subacromial steroid injection to the treatment program should be

tailored to each patient and to his or her expectations. As long as a subacromial injection is not relatively contraindicated (eg, in a patient who has diabetes or who has already received two injections; see **RISKS OF STEROID INJECTIONS**, below), this treatment can be offered at the initial visit or after 6 weeks of physical therapy if the patient's pain has not improved. Some patients find physical therapy too aggressive and pain-provoking, so a subacromial steroid injection can give the patient enough pain control to allow him or her to participate in physical therapy again. Subacromial injections, however, should not be considered as a substitute for a course of physical therapy.

If the patient does not respond to physical therapy and a subacromial injection after 3 months, then the patient should be referred to a specialist for consideration of subacromial decompression.

Injections for rotator cuff tears

If a patient has a rotator cuff tear that is amenable to surgical repair, no more than two subacromial injections should be given, because these could potentially weaken the remaining tendon and have a deleterious effect on the outcome of rotator cuff repair (see below).^{18,19} While there is little evidence to support corticosteroid injection for rotator cuff tears, the short-term pain relief may be sufficient to enable patients to participate in physical therapy.

A rotator cuff tear is considered irreparable if magnetic resonance imaging or computed tomography shows severe fatty atrophy of the muscles, or if a radiograph shows that the humeral head has migrated up to the acromion. This superior migration occurs after many months in which the torn rotator cuff muscles cannot balance the forces around the humeral head.

If the patient does not respond to 3 months of physical therapy and a subacromial injection, he or she should be referred to a specialist to discuss rotator cuff repair or debridement.

Rotator cuff tears do not heal without surgery, but physical therapy can turn a painful tear into a painless tear in 54% to 82% of cases.^{9,10} Studies have shown that many people over the age of 60 have asymptomatic rota-

Subacromial injections are not a substitute for physical therapy

tor cuff tears.^{20,21} Therefore, we offer physical therapy as an alternative to surgical repair.

The risk of treating a full-thickness rotator cuff repair with physical therapy is that the tear could become larger with time and retract in response to the unopposed muscle forces.²² More importantly, the rotator cuff muscle will become atrophied and infiltrated with fat over time, and these changes are irreversible. Therefore, if a patient is successfully treated with physical therapy but then develops recurrent shoulder pain from chronic rotator cuff rupture, he or she may no longer have the option of surgical repair because irreversible muscle changes have already occurred. A recent study in dogs suggested that these irreversible changes occur in as little as 6 weeks.

Other factors that contribute to the success or failure of rotator cuff repair include age, tendon quality, smoking, ability to participate in physical therapy after surgery, tear size, and muscle atrophy. Therefore, the treatment of each patient must be individualized on the basis of particular risk factors.

Injections for AC joint arthritis

Patients with AC joint osteoarthritis may benefit from a steroid injection into the AC joint, although according to one study, the pain relief is short-lived.²³ Physical therapy does not provide the same good results for symptomatic AC joint arthritis as it does for rotator cuff disease.²⁴ Surgery may be considered if activity modification or pain medication has failed to provide relief after a minimum of 3 months.

Injections for glenohumeral arthritis or adhesive capsulitis

Patients with glenohumeral arthritis or adhesive capsulitis may benefit from an intra-articular steroid injection, but these injections are technically difficult to accomplish accurately. One study showed the accuracy of intra-articular injections by experienced orthopedic surgeons to be less than 30%.²⁵ The use of ultrasonography or fluoroscopy improves the accuracy of intra-articular injections, and these methods are the standard of care for radiologists who give injections into the glenohumeral joint on a daily basis. Therefore, it is recommended that patients be referred to a

specialist who has experience performing intra-articular injections and has access to imaging in the office.^{26–28}

Other studies have shown little benefit from subacromial or intra-articular injections for the treatment of adhesive capsulitis.^{29,30}

■ RISKS OF STEROID INJECTIONS

Adverse effects of steroid injections are rare in the short term and include infection, anaphylaxis, vagal response, and, in patients with diabetes, high blood glucose levels.^{31–33}

The long-term effects—in particular, ruptured tendon—are more worrisome because they may be irreversible and may not be recognized until surgical repair is attempted. Basic science studies have shown that corticosteroid injections can weaken the tendons and cause histologic changes in the tendon including inflammation, focal necrosis, and fragmentation of collagen bundles.^{34,35} One intraoperative study found a correlation between softness of the rotator cuff tendon (making it unable to hold sutures) and the number of steroid injections given preoperatively, and a clinical study found a higher failure rate for rotator cuff repairs in patients who had more than three preoperative subacromial injections.^{18,19} Given these risks, I recommend giving no more than two injections in the shoulder.

Some clinicians avoid giving injections in patients with bleeding disorders because they fear causing a hemarthrosis or superficial hematoma, but a study by Thumboo et al³⁶ showed that the risk of bleeding complications from an injection in patients taking warfarin (Coumadin) is low.

■ HOW TO GIVE A SUBACROMIAL INJECTION

Injections can be given into the subacromial bursa from an anterior, lateral, or posterior approach in relation to the acromion. I prefer the posterior approach because the landmarks are more easily palpable and the space between the humeral head and the acromion is usually larger in the back of the shoulder (FIGURE 5).

First, palpate the posterolateral corner of

Rotator cuff tears do not heal without surgery, but physical therapy can turn a painful tear into a painless tear

How to give a subacromial injection

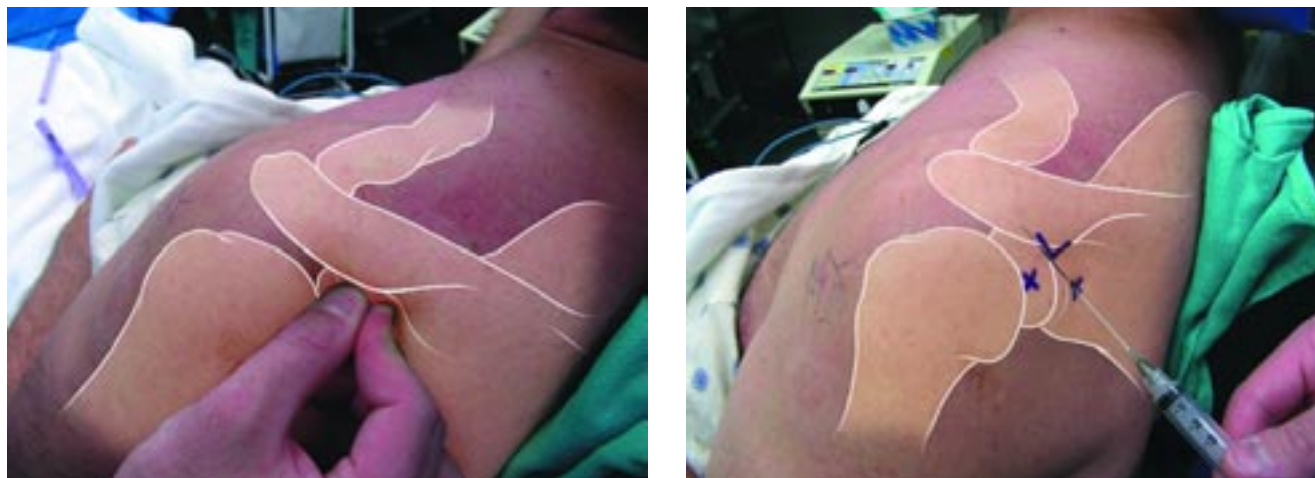


FIGURE 5. **Left**, the posterior corner of the acromion is the easiest landmark to palpate, and may be the only palpable landmark in large shoulders. It is easiest to feel using both the thumb and index finger. **Right**, the examiner can insert the needle directly inferior (shown with the X) to the corner of the acromion or slightly lateral to the acromion. Remember that the acromion slopes upward, so the examiner should aim the needle towards the top of the shoulder.

the acromion with the thumb and index finger. Make a mark 1 centimeter inferior to the bone with the Luer lock end of a needle or syringe that will remain after the skin is prepped with alcohol wipes. Clean the skin with alcohol wipes until the wipes are free of any visible debris.

Tell the patient to rest his or her forearm on the thigh and relax the deltoid muscle. Palpate the anterior lateral acromion with one finger and aim a 25-gauge needle towards that finger. If resistance is felt during the injection, pull the needle back slowly until the resistance decreases. Then inject 5 mL of a quick-acting anesthetic such as lidocaine to know in 2 minutes whether the injection relieves the patient's pain.

Keeping the needle in place, exchange the lidocaine syringe with a syringe filled with corticosteroid and inject 1 or 2 mL into the subacromial space. The amount of steroid to inject depends on the strength and potency of the suspension (TABLE 1). The corticosteroid can be mixed with the lidocaine in one syringe, but then subcutaneous injection of the mixture should be avoided, especially in dark-skinned patients, to prevent permanent skin depigmentation.

Be sure to counsel the patient about the

typical course of pain relief after the injection. The lidocaine will wear off in 1 to 2 hours and the pain will return, and sometimes the pain is more severe than before the injection. The patient needs to know that the steroid will take 3 to 4 days to take full effect and suppress the pain.

■ HOW TO GIVE AN AC JOINT INJECTION

The AC joint is technically more difficult to give injections into because the space is narrow in many patients with arthritis. The osteophytes around the joint are usually palpable. If not, find the soft spot where the clavicle and the spine of the scapula meet (FIGURE 6). Just anterior to the soft spot is the AC joint. Use a 25-gauge needle and inject lidocaine in the skin over the joint. Once the area is anesthetized, the needle can be moved until the AC joint is found without making the patient uncomfortable. The joint is much more superficial than the subacromial bursa, so the needle may be in the supraspinatus muscle if more than a centimeter of the needle is under the skin. Only 1 mL of steroid can be injected into this small space.

If the injection is being given for diagnos-

Corticosteroid injections take 3 to 4 days to take effect and relieve pain

TABLE 1

Corticosteroid suspensions used for shoulder injections

CORTICOSTEROID	CONCENTRATION	RECOMMENDED AMOUNT*
Betamethasone (Celestone Soluspan)	3 mg/mL	1.5–3 mg
Methylprednisolone acetate (Depo-Medrol)	40 mg/mL or 80 mg/mL	20–80 mg
Triamcinolone acetonide (Kenalog-40)	40 mg/mL	5–40 mg
Triamcinolone hexacetonide (Aristopan)	20 mg/mL	10–20 mg

*According to drug labels provided by the manufacturer.

We recommend giving no more than two subacromial steroid injections in patients with a repairable rotator cuff

tic purposes, careful attention should be paid to the depth of the injection, so as not to anesthetize the subacromial bursa below the AC joint. If the injection is for therapy, repositioning of the needle with multiple small injections in the joint and deep to the joint will ensure that all of the pathologic tissue is treated.

■ OUTCOMES OF SURGICAL MANAGEMENT

Surgery for impingement syndrome

Patients with impingement syndrome who do not respond to 3 months of physical therapy, subacromial steroid injection, and activity modification can consider surgical management.

Subacromial decompression can usually be done arthroscopically as an outpatient procedure. Eighty-three percent to 94% of patients who undergo the procedure experience good to excellent pain relief, and 75% are able to return to sports. The recovery time ranges from 3 to 4 months.^{37–40}

Most studies of the effectiveness of arthroscopic decompression have been limited by their lack of an adequate control group. Recently, the first randomized study comparing the effectiveness of physical therapy and surgery revealed a surprising result. Patients who underwent surgery did not have improved pain scores or function scores; in fact, they received more disability payments

over 1 year than the patients in the physical therapy group.⁴¹ Another randomized study showed similar outcomes with regard to the ineffectiveness of subacromial decompression performed at the time of rotator cuff repair.⁴²

Surgery for rotator cuff tears

Patients who undergo surgical repair of the rotator cuff can obtain pain relief, increased strength, and increased motion. Ninety percent of patients whose rotator cuff heals after surgery have good to excellent results. Patients with persistent rotator cuff tears after surgery have good to excellent pain relief, but their functional outcome scores are slightly less than those of patients with a healed rotator cuff repair.

The size of the rotator cuff tear and the degree of muscle atrophy directly correlate with rotator cuff healing rates. Small and medium tears heal in 90% of patients, large tears heal in 70%, and massive tears heal in 25% to 50%. Rotator cuff tears that are not repairable due to tendon loss can still be surgically debrided with the expectation that most patients will have less pain despite having no gain in strength or function.

When patients are counseled about surgery, they must understand that the average recovery time after rotator cuff surgery is 4 months, and that it may take up to 6 months for them to regain their motion if they have a

How to give an AC joint injection

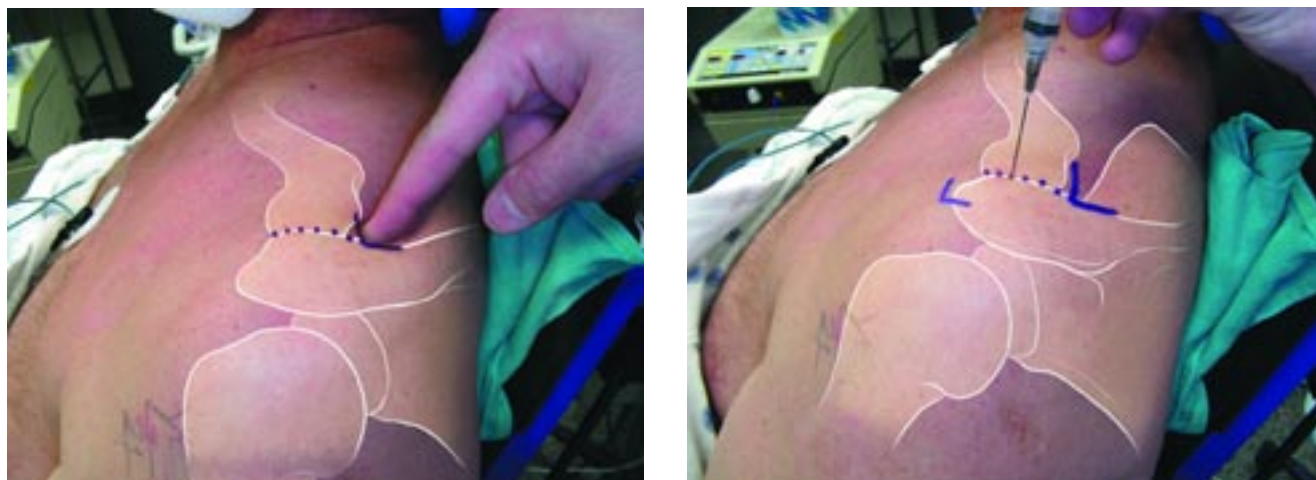


FIGURE 6. **Left**, in this left shoulder, the examiner can palpate the soft spot where the clavicle and the spine of the scapula meet. The AC joint is marked with a dashed line starting from the soft spot and ending lateral and anterior to the soft spot. **Right**, the AC joint can be injected anywhere along the dotted line. The needle may need to be angled towards the acromion in multiple directions before finding the joint, so a small subcutaneous injection with lidocaine should be given first to minimize patient discomfort.

large tear. Although pain is less during the first few weeks if arthroscopic techniques are used, the total recovery period remains unchanged.

Surgery for adhesive capsulitis

Patients with adhesive capsulitis that does not respond to a minimum of 12 months of physical therapy are potential candidates for manipulation under anesthesia and capsular release. Results depend on the cause of the adhesive capsulitis. Idiopathic frozen shoulder responds better to surgical management than

do posttraumatic and postsurgical frozen shoulders.

Surgery for glenohumeral arthritis

Glenohumeral arthritis is commonly treated with resurfacing of the humeral head. Whether the glenoid articular surface can be resurfaced depends on the quality of the bone. Joint replacement provides pain relief for 90% of patients, and long-term studies show that implants can survive for more than 10 years. The average recovery time is 3 months. ■

The average recovery time after rotator cuff surgery is 4 months

REFERENCES

1. Gorski JM, Schwartz LH. Shoulder impingement presenting as neck pain. *J Bone Joint Surg* 2003; 85:635–638.
2. Neer CS. Impingement lesions. *Clin Orthop Rel Res* 1983; 173:70–77.
3. Park HB, Yokota A, Gill HS, El Rassi G, McFarland EG. Diagnostic accuracy of clinical tests for the different degrees of subacromial impingement syndrome. *J Bone Joint Surg Am* 2005; 87:1446–1455.
4. Williams M, Lambert RG, Jhangri GS, et al. Humeral head cysts and rotator cuff tears: an MR arthrographic study. *Skeletal Radiol* 2006; 35:909–914.
5. Henkus HE, Cobben LP, Coerkamp EG, Nelissen RG, van Arkel ER. The accuracy of subacromial injections: a prospective randomized magnetic resonance imaging study. *Arthroscopy* 2006; 22:277–282.
6. Bisbinas I, Belthur M, Said HG, Green M, Learmonth DJ. Accuracy of needle placement in ACJ injections. *Knee Surg Sports Traumatol Arthrosc* 2006; 14:762–765.
7. Hawkins RH, Dunlop R. Nonoperative treatment of rotator cuff tears. *Clin Orthop Relat Res* 1995; 321:178–188.
8. Bartolozzi A, Andreychik D, Ahmad S. Determinants of outcome in the treatment of rotator cuff disease. *Clin Orthop Relat Res* 1994; 308:90–97.
9. Itoi E, Tabata S. Conservative treatment of rotator cuff tears. *Clin Orthop Relat Res* 1992; 275:165–173.
10. Bokor DJ, Hawkins RJ, Huckell GH, Angelo RL, Schickendantz MS. Results of nonoperative management of full-thickness tears of the rotator cuff. *Clin Orthop Relat Res* 1993; 294:103–110.
11. Blair B, Rokito AS, Cuomo F, Jarolem K, Zuckerman JD. Efficacy of injections of corticosteroids for subacromial impingement syndrome. *J Bone Joint Surg Am* 1996; 78:1685–1689.
12. Alvarez CM, Litchfield R, Jackowski D, Griffin S, Kirkley A. A prospective, double-blind, randomized clinical trial comparing subacromial injection of betamethasone and xylocaine to xylocaine alone in chronic rotator cuff tendinosis. *Am J Sports Med* 2005; 33:255–262.
13. Hollingworth GR, Ellis RM, Hattersley TS. Comparison of injection techniques for shoulder pain: results of a double blind, randomised study. *Br Med J (Clin Res Ed)* 1983; 287:1339–1341.

14. **Withrington RH, Girgis FL, Seifert MH.** A placebo-controlled trial of steroid injections in the treatment of supraspinatus tendinitis. *Scand J Rheumatol* 1985; 14:76–78.
15. **Berry H, Fernandes L, Bloom B, Clark RJ, Hamilton EB.** Clinical study comparing acupuncture, physiotherapy, injection and oral anti-inflammatory therapy in shoulder-cuff lesions. *Curr Med Res Opin* 1980; 7:121–126.
16. **McInerney JJ, Dias J, Durham S, Evans A.** Randomised controlled trial of single, subacromial injection of methylprednisolone in patients with persistent, post-traumatic impingement of the shoulder. *Emerg Med J* 2003; 20:218–221.
17. **Yamakado K.** The targeting accuracy of subacromial injection to the shoulder: an arthrographic evaluation. *Arthroscopy* 2002; 18:887–891.
18. **Bjorkenheim JM, Paavolainen P, Ahovuo J, Slati P.** Surgical repair of the rotator cuff and surrounding tissues. Factors influencing the results. *Clin Orthop Relat Res* 1988; 236:148–53.
19. **Watson M.** Major ruptures of the rotator cuff. The results of surgical repair in 89 patients. *J Bone Joint Surg Br* 1985; 67:618–624.
20. **Tempelhof S, Rupp S, Seil R.** Age-related prevalence of rotator cuff tears in asymptomatic shoulders. *J Shoulder Elbow Surg* 1999; 8:296–299.
21. **Sher JS, Uribe JW, Posada A, Murphy BJ, Zlatkin MB.** Abnormal findings on magnetic resonance images of asymptomatic shoulders. *J Bone Joint Surg Am* 1995; 77:10–15.
22. **Yamaguchi K, Tetro AM, Blam O, Evanoff BA, Teefey SA, Middleton WD.** Natural history of asymptomatic rotator cuff tears: a longitudinal analysis of asymptomatic tears detected sonographically. *J Shoulder Elbow Surg* 2001; 10:199–203.
23. **Jacob AK, Sallay PI.** Therapeutic efficacy of corticosteroid injections in the acromioclavicular joint. *Biomed Sci Instrum* 1997; 34:380–385.
24. **Buttaci CJ, Stitik TP, Yonclas PP, Foye PM.** Osteoarthritis of the acromioclavicular joint: a review of anatomy, biomechanics, diagnosis, and treatment. *Am J Phys Med Rehabil* 2004; 83:791–797.
25. **Sethi PM, Kingston S, Elattrache N.** Accuracy of anterior intra-articular injection of the glenohumeral joint. *Arthroscopy* 2005; 21:77–80.
26. **Naredo E, Cabero F, Beneyto P, et al.** A randomized comparative study of short term response to blind injection versus sonographic-guided injection of local corticosteroids in patients with painful shoulder. *J Rheumatol* 2004; 31:308–314.
27. **Gavant ML, Rizk TE, Gold RE, Flick PA.** Distention arthrography in the treatment of adhesive capsulitis of the shoulder. *J Vasc Interv Radiol* 1994; 5:305–308.
28. **Carette S, Moffet H, Tardif J, et al.** Intraarticular corticosteroids, supervised physiotherapy, or a combination of the two in the treatment of adhesive capsulitis of the shoulder: a placebo-controlled trial. *Arthritis Rheum* 2003; 48:829–838.
29. **Rizk TE, Pinals RS, Talaiver AS.** Corticosteroid injections in adhesive capsulitis: investigation of their value and site. *Arch Phys Med Rehabil* 1991; 72:20–22.
30. **Ryans I, Montgomery A, Galway R, Kernohan WG, McKane R.** A randomized controlled trial of intra-articular triamcinolone and/or physiotherapy in shoulder capsulitis. *Rheumatology (Oxford)* 2005; 44:529–535.
31. **Lazarevic MB, Skosey JL, Djordjevic-Denic G, Swedler WI, Zgradic I, Myones BL.** Reduction of cortisol levels after single intra-articular and intramuscular steroid injection. *Am J Med* 1995; 99:370–373.
32. **Hopper JM, Carter SR.** Anaphylaxis after intra-articular injection of bupivacaine and methylprednisolone. *J Bone Joint Surg Br* 1993; 75:505–506.
33. **Birkenshaw R, O'Donnell J, Sammy L.** Necrotizing fasciitis as a complication of steroid injection. *J Accid Emerg Med* 1997; 14:52–54.
34. **McWhorter JW, Francis RS, Heckmann RA.** Influence of local steroid injections on traumatized tendon properties. A biomechanical and histological study. *Am J Sports Med* 1991; 19:435–439.
35. **Tillander B, Franzen LE, Karlsson MH, Norlin R.** Effect of steroid injections on the rotator cuff: an experimental study in rats. *J Shoulder Elbow Surg* 1999; 8:271–274.
36. **Thumboo J, O'Duffy JD.** A prospective study of the safety of joint and soft tissue aspirations and injections in patients taking warfarin sodium. *Arthritis Rheum* 1998; 41:736–739.
37. **Esch JC, Ozerkis LR, Helgager JA, Kane N, Lilliot N.** Arthroscopic subacromial decompression: results according to the degree of rotator cuff tear. *Arthroscopy* 1988; 4:241–249.
38. **Gartsman GM.** Arthroscopic acromioplasty for lesions of the rotator cuff. *J Bone Joint Surg Am* 1990; 72:169–180.
39. **Speer KP, Lohnes J, Garrett WE Jr.** Arthroscopic subacromial decompression: results in advanced impingement syndrome. *Arthroscopy* 1991; 7:291–296.
40. **Altchek DW, Warren RF, Wickiewicz TL, Skyhar MJ, Ortiz G, Schwartz E.** Arthroscopic acromioplasty. Technique and results. *J Bone Joint Surg Am* 1990; 72:1198–1207.
41. **Haahr JP, Andersen JH.** Exercises may be as efficient as subacromial decompression in patients with subacromial stage II impingement: 4–8 years' follow-up in a prospective, randomized study. *Scand J Rheumatol* 2006; 35:224–228.
42. **Gartsman GM, O'Connor DP.** Arthroscopic rotator cuff repair with and without arthroscopic subacromial decompression: a prospective, randomized study of one-year outcomes. *J Shoulder Elbow Surg* 2004; 13:424–426.

ADDRESS: Michael J. Codsi, MD, Department of Orthopaedics, A41, Cleveland Clinic, 9500 Euclid Avenue, Cleveland, OH 44195; e-mail codsim@ccf.org.