

AI-PING CHUA, MB, BS
Respiratory Institute, Cleveland Clinic

STEVEN D. BILLINGS, MD*
Co-head, Section of Dermatopathology,
Department of Anatomic Pathology,
Cleveland Clinic

MARIE M. BUDEV, DO, MPH
Department of Pulmonary, Allergy, and
Critical Care Medicine and the Trans-
plantation Center, Respiratory Institute,
Cleveland Clinic

ATUL C. MEHTA, MB, BS
Department of Pulmonary, Allergy, and
Critical Care Medicine, Respiratory
Institute, Cleveland Clinic; Chief of Staff,
Sheikh Khalifa Medical City, Abu Dhabi,
United Arab Emirates

The Clinical Picture

Ulcerative leg nodules in a transplant recipient

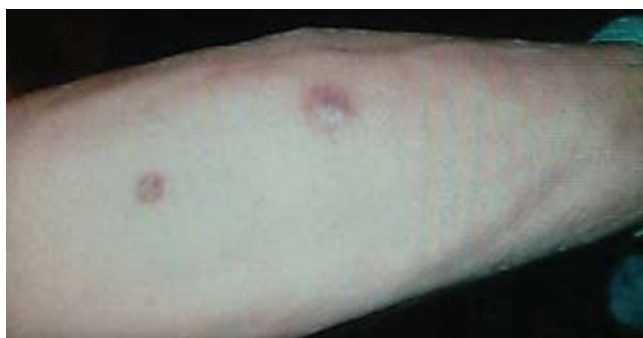

FIGURE 1. Purpuric nodules with surrounding erythema.

A 66-YEAR-OLD WHITE MAN presents with a 1-month history of two nontender, nonpruritic skin lesions on his leg 3 weeks after undergoing bilateral lung transplantation for idiopathic pulmonary fibrosis (**FIGURE 1**). Except for transient lymphopenia, the post-operative course has been uneventful, with no episodes of rejection. Immunosuppressive drugs include tacrolimus (Prograf) and steroids. He has a history of insulin-dependent diabetes mellitus, and no history of significant trauma to his legs. Other than the skin lesions, he feels well and has no systemic symptoms. He has no history of iron overload or deferoxamine (Desferal) therapy.

Q: What is the probable diagnosis?

- ☐ Kaposi sarcoma
- ☐ Majocchi (trichophytic) granuloma
- ☐ *Staphylococcus aureus* furunculosis
- ☐ Primary cutaneous mucormycosis
- ☐ Disseminated zoster

A: This patient has primary cutaneous mucormycosis. Microscopic examination of the skin biopsy showed suppurative granulomatous inflammation

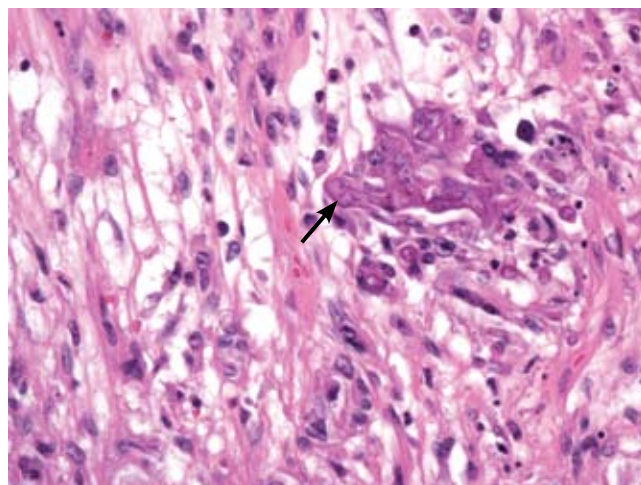


FIGURE 2. Irregular nonseptated, branching, fungal hyphae (arrow) throughout the dermis are surrounded by a histiocytic granulomatous infiltrate (hematoxylin-eosin, original magnification $\times 400$).

with numerous nonseptated, branching fungal hyphae (**FIGURE 2**). A fungal culture grew *Absidia* species. No evidence of disseminated disease was found on computed tomography of the brain, paranasal sinuses, chest, abdomen, and pelvis. Histologic studies and cultures taken from both native and transplanted lungs were negative for fungi.

CAUSES AND RISK FACTORS

Mucormycosis is an invasive infection caused by fungi of a variety of genera (*Rhizopus*, *Rhizomucor*, *Mucor*, *Absidia*, *Apophysomyces*, *Cunninghamella*, *Saksenaia*, *Conidiobolus*, and *Basidiobolus* species) belonging to the class Zygomycetes in the order Mucorales. These ubiquitous environmental fungi have been found widely distributed in hospital sources, having been cultured from plaster casts,¹ tongue depressors,² cloth tapes for securing endotracheal tubes,³ peritoneal dialysis

*Dr. Billings has disclosed that he has received consulting fees from Allos Therapeutics.

catheters,⁴ surgical wounds,⁵ contaminated dressings, needles, and intravenous catheters.⁶

These fungi rarely cause disease in healthy people, but patients with certain risk factors may develop disseminated disease, in which the death rate is high.⁶ Risk factors include diabetes mellitus, renal failure, trauma, burns, malnutrition, solid organ transplantation, hematologic malignancies, use of immunosuppressive drugs (eg, chemotherapeutic agents, corticosteroids, cyclosporine, methotrexate, infliximab [Remicade]⁷), and iron overload and iron-chelating therapy with deferoxamine.⁸ Patients such as ours—an organ transplant recipient with concomitant diabetes mellitus—are highly susceptible to this infection.

■ DIAGNOSIS

The clinical presentation of mucormycosis can be rhino-orbitocerebral (most common),⁹ pulmonary, primary cutaneous, gastrointestinal, cardiac, or disseminated infection.⁶ Primary cutaneous mucormycosis occurs from fungal inoculation of the dermis. Small areas of trauma may be all that is needed for this inoculation to occur.

The initial lesion may be an erythematous patch, plaque, or nodule that may subsequently ulcerate and become gangrenous or necrotic.¹⁰

The differential diagnosis of new cutaneous nodules in an immunocompromised patient includes a wide variety of infections, such as ecthyma gangrenosum caused by *Pseudomonas* or *Candida* species, herpes simplex virus infection, cryptococcal infection, phaeohyphomycosis, and cutaneous aspergillosis.

Because the morphology of cutaneous mucormy-

cosis is not distinctive, and because we need to cast our net wide for the numerous, potentially lethal diagnostic possibilities in an immunosuppressed patient, it is crucial that we have a low threshold for prompt biopsy to establish the diagnosis and initiate definitive treatment. While skin biopsy for microscopy can suggest certain fungi, the exact diagnosis is confirmed by a fungal culture of a biopsy specimen.

■ TREATMENT

Localized soft tissue infection is more amenable to therapy and therefore carries a better prognosis than visceral or disseminated disease.

The best treatment outcomes of primary cutaneous mucormycosis are achieved with both complete excision and debridement of necrotic tissue and systemic antifungal therapy. Amphotericin B in conventional form (Fungizone) and liposomal form (AmBisome) and posaconazole (Noxafil)^{11–12} are effective.

Paradoxically, in contrast to deferoxamine, other iron chelators such as deferiprone (Ferriprox, not available in the United States) and deferasirox (Exjade), which do not supply iron to the fungus, had been shown to be effective against Zygomycetes in vitro and animal models. The role of iron chelators as adjunctive therapy for mucormycosis needs further investigation.⁸

Primary cutaneous mucormycosis may become a disseminated infection. Therefore, one should have a high index of suspicion. When a transplant recipient develops a cutaneous plaque or nodule, biopsy should be performed promptly. Failure to do so can increase the risk of morbidity and death. ■

■ REFERENCES

1. Johnson AS, Ranson M, Scarffe JH, Morgenstern GR, Shaw AJ, Oppenheim BA. Cutaneous infection with *Rhizopus oryzae* and *Aspergillus niger* following bone marrow transplantation. *J Hosp Infect* 1993; 25:293–296.
2. Paydas S, Yavuz S, Disel U, et al. Mucormycosis of the tongue in a patient with acute lymphoblastic leukemia: a possible relation with use of a tongue depressor. *Am J Med* 2003; 114:618–620.
3. Dickinson M, Kalayanamit T, Yang CA, Pomper GJ, Franco-Webb C, Rodman D. Cutaneous zygomycosis (mucormycosis) complicating endotracheal intubation: diagnosis and successful treatment. *Chest* 1998; 114:340–342.
4. Nayak S, Satish R, Gokulnath, Savio J, Rajalakshmi T. Peritoneal mucormycosis in a patient on CAPD. *Perit Dial Int* 2007; 27:216–217.
5. Chew HH, Abuzeid A, Singh D, Tai CC. Surgical wound mucormycosis necessitating hand amputation: a case report. *J Orthop Surg (Hong Kong)* 2008; 16:267–269.
6. Benbow EW, Stoddart RW. Systemic zygomycosis. *Postgrad Med J* 1986; 62:985–996.
7. Gadadhar H, Hawkins S, Huffstutter JE, Panda M. Cutaneous mu-

cormycosis complicating methotrexate, prednisone, and infliximab therapy. *J Clin Rheumatol* 2007; 13:361–362.

8. Ibrahim AS, Spellberg B, Edwards J Jr. Iron acquisition: a novel perspective on mucormycosis pathogenesis and treatment. *Curr Opin Infect Dis* 2008; 21:620–625.
9. Chakrabarti A, Das A, Sharma A, et al. Ten years' experience in zygomycosis at a tertiary care centre in India. *J Infect* 2001; 42:261–266.
10. Nouri-Majalan N, Moghimi M. Skin mucormycosis presenting as an erythema-nodosum-like rash in a renal transplant recipient: a case report. *J Med Case Reports* 2008; 2:112.
11. Sun QN, Fothergill AW, McCarthy DI, Rinaldi MG, Graybill JR. In vitro activities of posaconazole, itraconazole, voriconazole, amphotericin B, and fluconazole against 37 clinical isolates of zygomycetes. *Antimicrob Agents Chemother* 2002; 46:1581–1582.
12. Spellberg B, Edwards J Jr, Ibrahim A. Novel perspectives on mucormycosis: pathophysiology, presentation and management. *Clin Microbial Rev* 2005; 18:556–569.

ADDRESS: Ai-Ping Chua, MD, Respiratory Institute, A90, Cleveland Clinic, 9500 Euclid Avenue, Cleveland, OH 44195; e-mail chuaa@ccf.org.