



EDUCATIONAL OBJECTIVE: The reader will consider which breast masses require further workup and which imaging study is most appropriate

LAUREN STEIN, MD

Imaging Institute, Cleveland Clinic

MELANIE CHELLMAN-JEFFERS, MD

Center for Specialized Women's Health and Section of Breast Imaging, Department of Diagnostic Radiology, Imaging Institute, Cleveland Clinic

The radiologic workup of a palpable breast mass

ABSTRACT

The finding of a palpable breast mass on physical examination often warrants a radiologic workup including directed ultrasonography, diagnostic mammography, and, at times, biopsy with ultrasonographic guidance. The choice of initial imaging study is most often guided by the patient's age at presentation. Communicating the clinical findings to both the patient and the radiologist helps ensure the selection of the most appropriate imaging studies and helps in the interpretation of those studies. Every woman with a palpable breast mass, regardless of her age, should undergo imaging to exclude or establish the diagnosis of cancer.

KEY POINTS

Typically, in women under age 30, ultrasonography is the first or the only test ordered to evaluate the abnormality. In women age 30 or older, diagnostic mammography is typically the first test ordered.

On mammography, a suspicious palpable mass has an irregular shape with spiculated margins. A benign mass typically has a round shape with well-circumscribed margins.

When mammography is required during pregnancy, the patient can be reassured that it will not jeopardize her fetus because the radiation dose is very low and the abdomen and pelvis can be shielded.

A 28-YEAR-OLD WOMAN comes in for her annual checkup. Her physician notices a palpable, painless, 1-cm, well-demarcated mass in the left breast at the 3 o'clock position 2 cm from the nipple, with no associated skin changes, nipple retraction, or discharge. The patient has no personal or family history of breast cancer.

Given the patient's age, physical findings, and medical history, the clinician believes it unlikely that the patient has cancer. How should she proceed with the workup of this patient?

PHYSICAL FINDINGS OF A BREAST MASS ARE NOT EXCLUSIVE

Breast cancer is the most common female malignancy and the second-leading cause of cancer deaths in the United States.¹ The incidence is low in young women and increases with advancing age. Benign breast disease is common in young women and less common in postmenopausal women.^{2,3} However, the discovery of a breast mass, whether by the woman herself or by a clinician, is a common occurrence and distressing for any woman.

Benign lesions tend to have discrete, well-defined margins and are typically mobile. Malignant lesions may be firm, may have indistinct borders, and are often immobile.² Although most breast masses found by palpation are benign, imaging is the critical next step in the workup to help determine if the mass is benign or malignant.

Benign palpable masses include:

- Cysts (FIGURE 1)
- Fibroadenomas (FIGURE 2)

doi:10.3949/ccjm.76a.08015

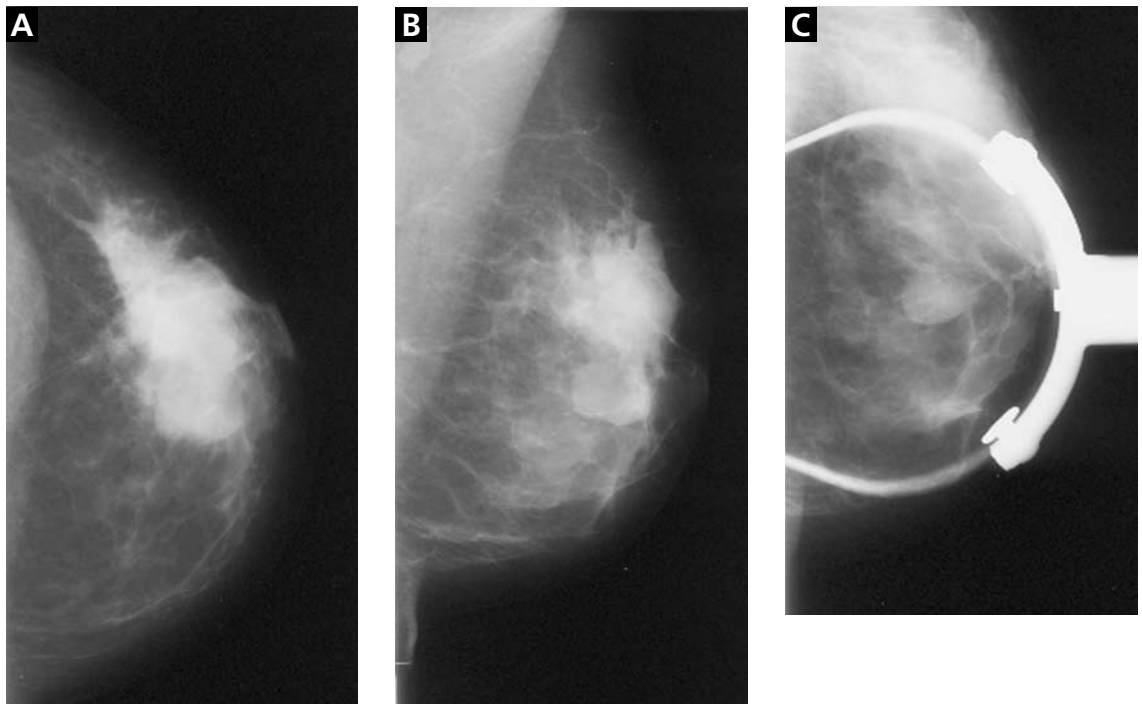
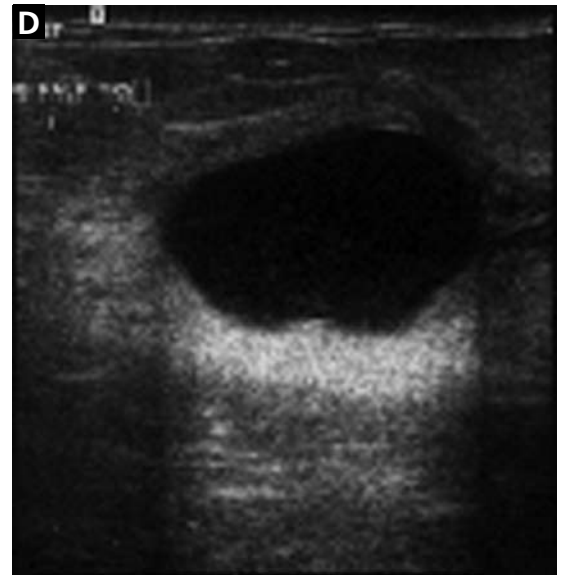


FIGURE 1. A simple cyst in the left breast. All three mammographic views—cranio-caudal (A), mediolateral oblique (B), and spot-compression (C)—show a round, well-circumscribed mass in the mid-breast. Ultrasonography (D) shows a round, well-circumscribed anechoic lesion with a sharply defined posterior wall and posterior acoustic enhancement.



On examination, note the clock-face location, size, texture, tenderness, and mobility of the lump

- Prominent fat lobules
- Lymph nodes
- Oil cysts
- Lipomas
- Hamartomas (FIGURE 3)
- Hematomas
- Fat necrosis
- Galactoceles.

Malignant palpable masses include:

- Invasive ductal and lobular carcinoma (FIGURE 4)
- Ductal carcinoma in situ (which rarely presents as a palpable mass.)

HISTORY AND PHYSICAL EXAMINATION

To ensure that imaging provides the most useful information about a palpable breast lump,

it is important to first do a careful history and physical examination. Important aspects of the history include family history, personal history of breast cancer, and any previous breast biopsies. The onset and duration of the palpable mass, changes in its size, the relationship of these changes to the menstrual cycle, and the presence or lack of tenderness are additional important elements of the history.

On examination, it is important to note the clock-face location, size, texture, tender-

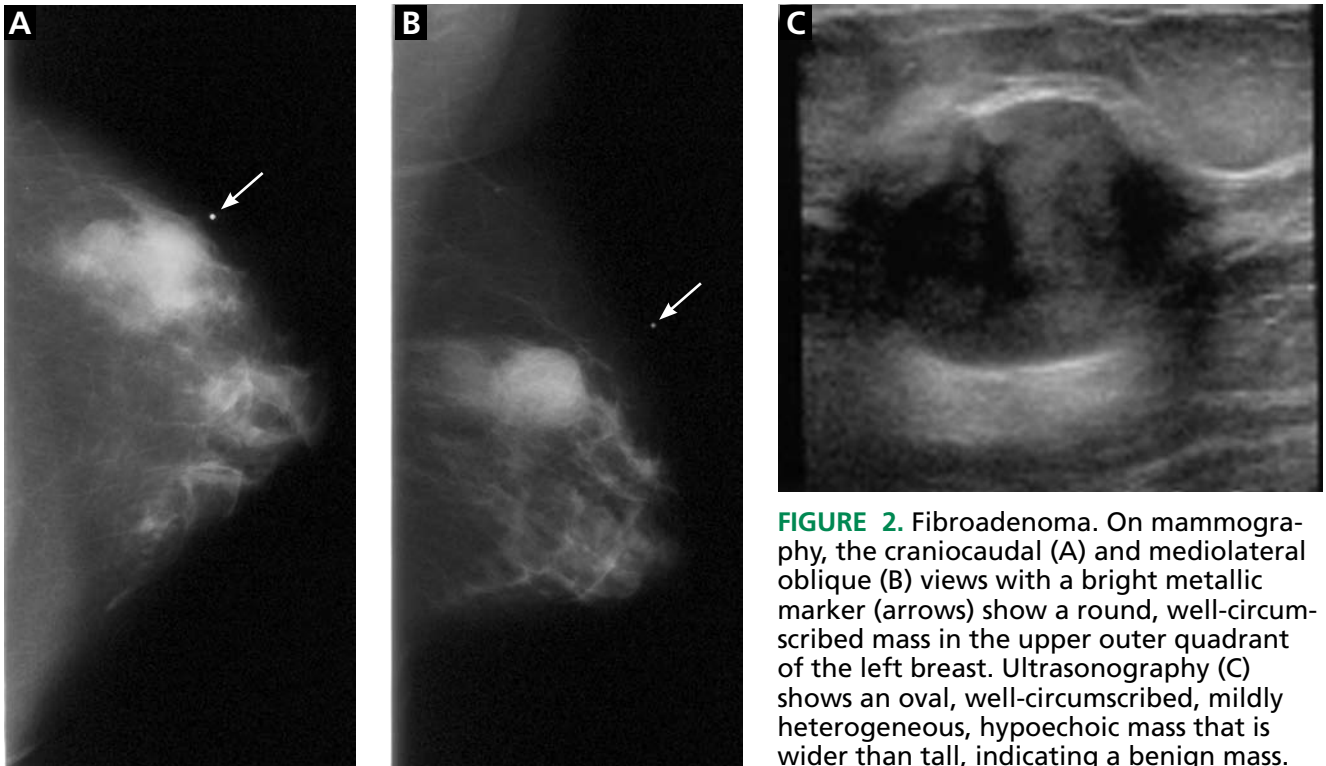


FIGURE 2. Fibroadenoma. On mammography, the craniocaudal (A) and mediolateral oblique (B) views with a bright metallic marker (arrows) show a round, well-circumscribed mass in the upper outer quadrant of the left breast. Ultrasonography (C) shows an oval, well-circumscribed, mildly heterogeneous, hypoechoic mass that is wider than tall, indicating a benign mass.

ness, and mobility of the lump. Accompanying nipple discharge and skin erythema or retraction are also important to report. In addition to conveying the location of the mass to the radiologist, it is equally important that the patient know what features the physician feels. This way, if the clinical information from the ordering physician is not available at the time of the radiologic evaluation, the patient will be able to guide the radiologist to the region of concern.

IMAGING TECHNIQUES

Mammography and ultrasonography are the primary imaging studies for evaluating palpable breast masses. Typically, in women under age 30, ultrasonography is the first or the only test ordered to evaluate the abnormality.⁴ In women age 30 or older, diagnostic mammography is typically the first test ordered. If mammography indicates that the palpable mass is not benign, then ultrasonography is the next study to be done.³ Although a powerful tool, magnetic resonance imaging of the breast does not currently have a role in the workup of a palpable abnormality and should

not be used as a decision-delaying tactic or in place of biopsy.

Screening or diagnostic mammography?

Mammography is used in both screening and diagnosis. Screening mammography consists of two standard views of each breast—craniocaudal and mediolateral oblique—and is appropriate for asymptomatic women.

Women age 30 or older who present with a palpable breast mass require diagnostic mammography, in which standard mammographic views are obtained, as well as additional views (eg, tangential or spot-compression views) to better define the area of clinical concern. In a tangential view, a metallic skin marker is placed on the skin overlying the site of the palpable abnormality.

On mammography, a suspicious palpable mass has an irregular shape with spiculated margins. A benign mass typically has a round shape with well-circumscribed margins. If the palpable abnormality is not mammographically benign (eg, if it does not look like a lymph node, lipoma, or degenerating fibroadenoma), then ultrasonography is performed.

Mammography is less sensitive in younger

Women over age 30 who present with a palpable breast mass require diagnostic mammography

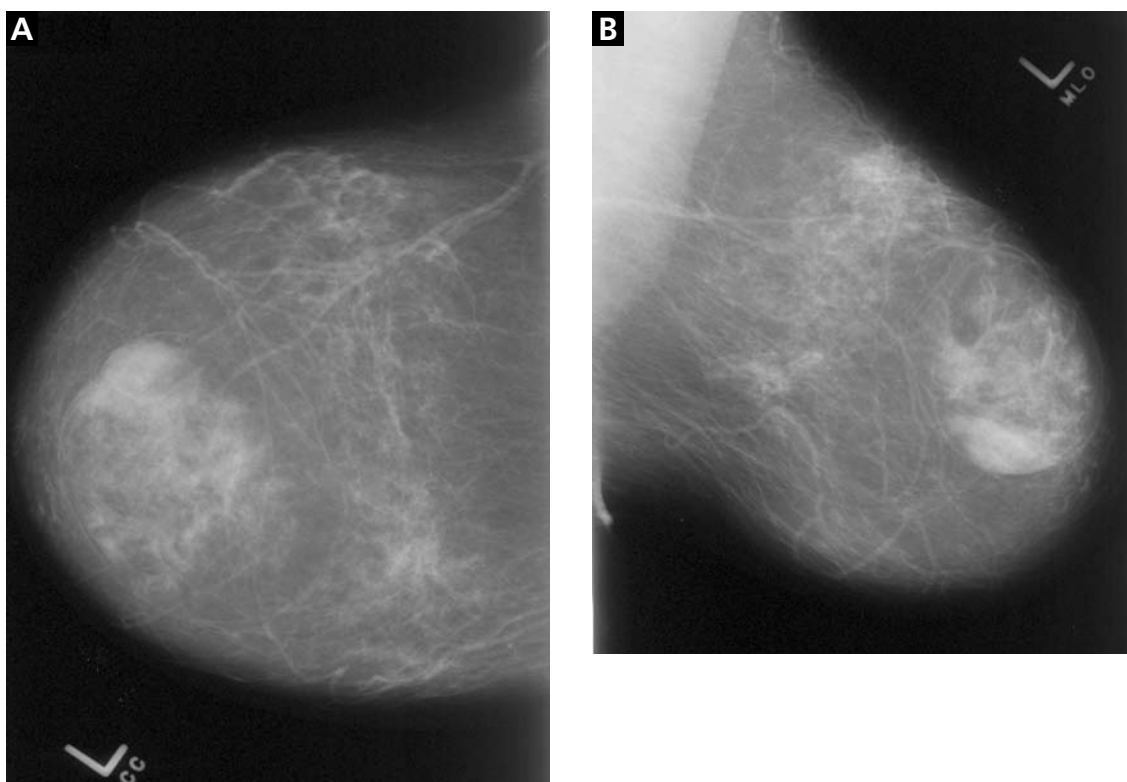


FIGURE 3. Hamartoma. Craniocaudal (A) and mediolateral oblique (B) mammographic views of the left breast show an apparently encapsulated, heterogeneous mass that contains fat mixed with fibroglandular tissue.

Core-needle biopsy has become more popular than fine-needle aspiration, as it includes surrounding tissue

women (ie, under age 30) because their breast tissue tends to be dense and glandular, whereas the tissue becomes more “fat-replaced” with age.³

Ultrasonography plays a complementary role

Ultrasonography complements diagnostic mammography and can be used as a first imaging study to evaluate a palpable breast mass in a young woman (ie, under age 30) with dense breast tissue. Ultrasonography is helpful in distinguishing cystic lesions from solid masses. It helps the radiologist delineate the shape, borders, and acoustic properties of the mass. It is also performed when a palpable mass is mammographically occult. When a mass appears suspicious on either mammography or ultrasonography, ultrasonography can be used to guide biopsy.

A suspicious mass on ultrasonography classically appears “taller than wide” and has posterior acoustic shadowing. Microlobulations and a spiculated margin also raise concern for

malignancy. A benign sonographic appearance of a palpable mass includes a “wider than tall” (ellipsoid) shape, with homogeneous echogenicity, and four or fewer gentle lobulations. A thin, echogenic capsule also suggests the mass is benign.

Core-needle biopsy with ultrasonographic guidance

Core-needle biopsy is performed with a large-diameter (14-gauge to 18-gauge) needle to obtain tissue cores for histologic analysis. It has gained popularity over fine-needle aspiration because it includes surrounding tissue architecture, thus providing a more definitive histologic diagnosis.

Pathologic information obtained from core-needle biopsy allows the radiologist and surgeon to counsel the patient and determine the best surgical management or follow-up imaging study. If a clinician performs fine-needle biopsy in the office, it should be preceded by an imaging workup of the palpable finding.

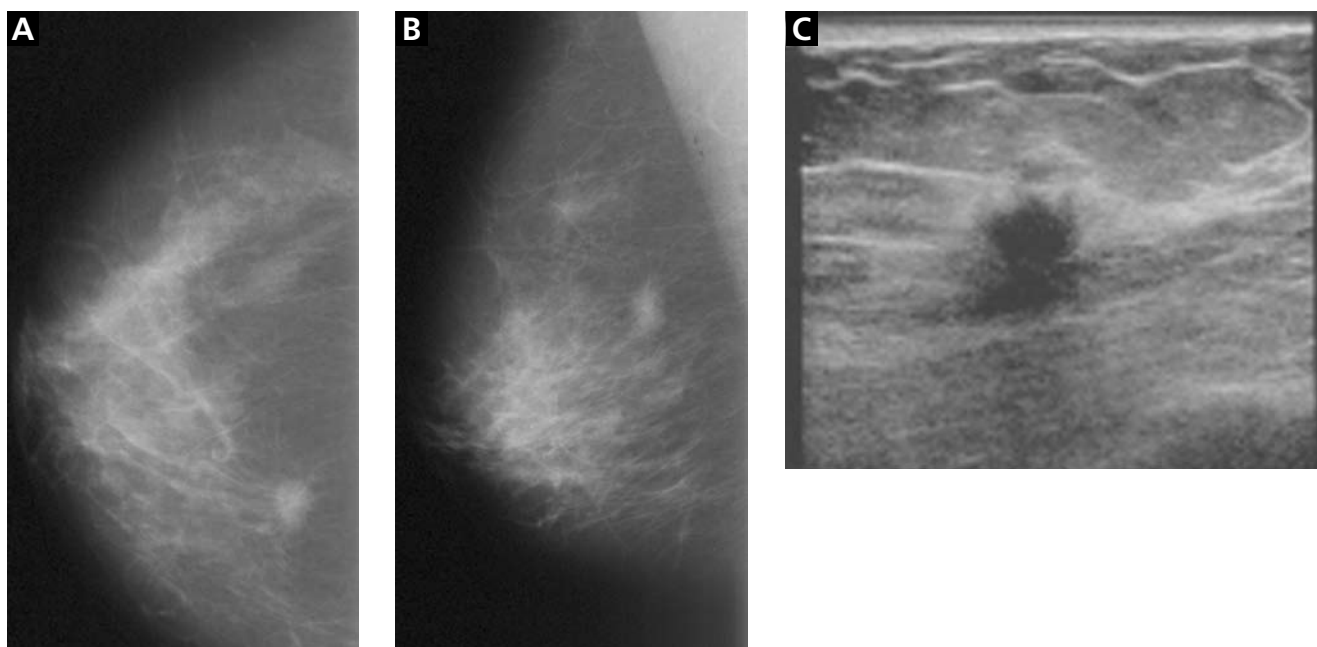


FIGURE 4. Infiltrating ductal carcinoma. Craniocaudal (A) and mediolateral oblique (B) mammographic views of the right breast show an irregular, mildly spiculated, high-density lesion in the posterior, medial breast. Ultrasonography (C) shows an irregularly shaped hypoechoic mass which is taller than wide (a profile tending to indicate malignancy) and has mild posterior acoustic shadowing.

■ WHAT IS APPROPRIATE FOR OUR 28-YEAR-OLD PATIENT?

Because she is under age 30, ultrasonography is the initial study of choice to evaluate the mass. If a simple cyst is detected, she can be reassured that the lesion is benign, and no subsequent follow-up is required. If the lesion is a solid mass with benign features, mammography may be considered, the patient may be followed with short-interval imaging (every 6 months) depending on patient-specific factors such as family history, or the mass can be biopsied. If the lesion is a solid mass with suspicious or malignant features, mammography with spot-compression views should be performed, and the patient should undergo core-needle biopsy with ultrasonographic guidance.

In a patient age 30 or older, diagnostic mammography is the imaging study of first choice.³ If the mass is clearly benign on mammography, no additional imaging would be necessary. If mammography fails to image the mass or shows it to have benign features such as fat, then the patient can undergo ultrasono-

graphy for further evaluation and confirmation of the clinical and mammographic findings. If the mass appears suspicious or malignant on mammography, ultrasonography is the next step, as it can help characterize the lesion and be used to guide core-needle biopsy.

■ IF A PREGNANT WOMAN HAS A PALPABLE BREAST MASS

Most publications on breast cancer in pregnancy report a prevalence of 3 per 10,000 pregnancies, accounting for 3% of all breast cancers diagnosed.⁵ Therefore, imaging evaluation of a palpable mass should not be postponed.

Hormonal changes throughout pregnancy may increase the nodularity of breast tissue, raising the concern of palpable masses. Additionally, there is a higher prevalence of galactoceles and lactating adenomas in these patients. Because contrasting fatty breast tissue is lost during pregnancy and because of the need to minimize radiation exposure, ultrasonography is often the imaging test of first choice. If

Ultrasound is often the study used first in pregnancy, but mammography can also be used

mammography is required, the radiation dose is very low and the patient's abdomen and pelvis can be shielded.⁶ In this situation, the patient can be reassured that the imaging test is not jeopardizing her fetus.

■ WHAT WORKUP IS REQUIRED IN MEN?

Breast cancer in men is rare, accounting for less than 0.5% of all cases.⁷ Most often, a palpable breast mass in a man presents as unilateral gynecomastia. Gynecomastia occurs in a bimodal age distribution (in the 2nd and 7th decades) and has a variety of hormonal and drug-related causes. Despite the low prevalence of breast cancer in men, the combination of mammography and ultrasonography is recommended for evaluation at all ages. ■

■ REFERENCES

1. Klein S. Evaluation of palpable breast masses. *Am Fam Physician* 2005; 71:1731–1738.
2. Pruthi S. Detection and evaluation of a palpable breast mass. *Mayo Clin Proc* 2001; 76:641–648.
3. Harvey JA. Sonography of palpable breast masses. *Semin Ultrasound CT MR* 2006; 27:284–297.
4. Mehta TS. Current uses of ultrasound in the evaluation of the breast. *Radiol Clin North Am* 2003; 41:841–856.
5. Gallenberg MM, Lopines CL. Breast cancer and pregnancy. *Semin Oncol* 1989; 16:369–376.
6. Barnavon Y, Wallack MK. Management of the pregnant patient with carcinoma of the breast. *Surg Gynecol Obstet* 1990; 171:347–352.
7. Cardenosa G. *The Core Curriculum: Breast Imaging*. Philadelphia: Lippincott Williams and Wilkins, 2003;304.

ADDRESS: *Melanie Chellman-Jeffers, MD, Imaging Institute, Section of Breast Imaging, A10, Cleveland Clinic, 9500 Euclid Avenue, Cleveland, OH 44195; e-mail chellmm@ccf.org.*