

Abstract 20

Temporal Lobe and Sinus Node: A Case Report Provides Evidence for Bidirectional Effects

Rebecca O'Dwyer, MD;¹ Andreas Alexopoulos, MD, MPH;¹
Walid Saliba, MD;² Imad Najm, MD;¹ and Richard Burgess, MD, PhD¹
¹Epilepsy Center, Department of Neurology, Neurological Institute, and
²Department of Cardiovascular Medicine, Cleveland Clinic, Cleveland, OH

Winner of the Young Investigator Award

Introduction: Epileptic seizures have been associated with changes in autonomic nervous system (ANS) function, such as changes in blood pressure and in heart and respiratory rate, as well as cardiac arrhythmias. A relationship between temporal lobe epilepsy (TLE) and autonomic dysfunction has been recognized. Electrical stimulation of limbic structures and insula may elicit changes in the cardiovascular regulatory system by exciting the central autonomic network. Likewise, increased activity of the ANS may be associated with increased frequency of epileptic seizures. Often cardiac rhythm changes may precede electroencephalographic or clinical changes at the onset of seizures by more than a few seconds. Tachycardia is more frequently seen with seizures arising from the temporal lobe; however, significant ictal bradycardia that rarely leads to asystole may also be seen. Resective epilepsy surgery (temporal lobectomy) is an established treatment modality for intractable TLE, rendering two-thirds of patients seizure free, on average. Whether surgical resection has an effect on the accompanying cardiac dysautonomia is less clear.

Case Report: A healthy 20-year-old male presented to our clinic with a history of seizures starting at the age of 18 years. Seizures were characterized by a rising abdominal sensation, followed by loss of awareness associated with staring, lip smacking, and purposeless hand fumbling. Interestingly, some seizures were associated with an abrupt loss of axial tone, producing a precipitous fall. Other than one isolated febrile seizure as an infant, the patient had no risk factors for epilepsy. As seizures were not controlled despite several antiepileptic medication (AED) trials, the patient underwent an inpatient video-scalp EEG evaluation at the age of 21 years that suggested that seizures were arising from the right mesial temporal lobe. A long QT interval during the ictus was noted at this time. He was found to be a suitable candidate for a standard right temporal lobectomy. This intervention resulted in cessation of seizures for almost 2.5 years (while on lamotrigine 200 mg qd and levetiracetam 3,000 mg qd). Seizures—semiologically unchanged—returned when the patient independently reduced his AEDs. Despite resumption of AED therapy, seizures occurring 2 to 4 times a week again proved intractable to AEDs. During a repeat video-EEG evaluation at the age of 27 years, a seizure asso-

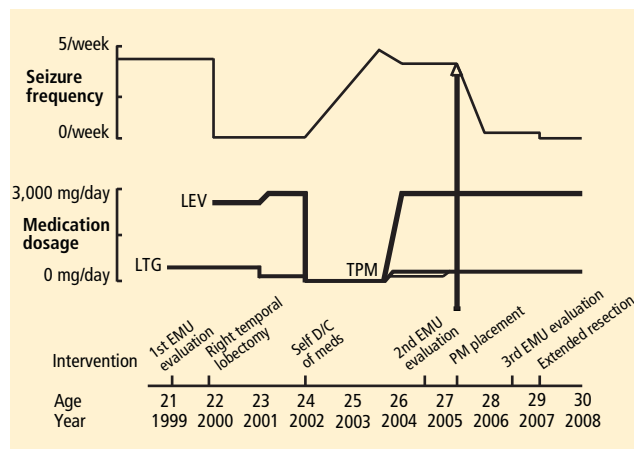


FIGURE. Timeline of events presented in case report.

ciated with prolonged ictal asystole (> 20 sec) was recorded. A three-chamber DDI pacemaker (PM) was placed and the patient was discharged. His seizure frequency decreased to once a month, and on his annual PM follow-up he reported that he remained conscious throughout his seizures. A previously undetected lesion was noted on MRI involving part of the remaining basal temporal lobe. A third (invasive) video-EEG evaluation, with placement of subdural electrodes to map the remaining epileptogenic zone, led to extension of the previous resection with excision of the MRI lesion, found to be a developmental tumor (DNET) on pathological examination. The patient has remained seizure free postoperatively. PM reports < 1% pacing subsequent to the second (curative) epilepsy surgery.

Discussion: Electrical stimulation studies in both animals and humans have shown effects of both cortical and subcortical structures on cardiac rhythm and their potential role in seizure-induced arrhythmias. However, there is little evidence to show an “antidromic” effect from firing of the sinus node on cerebral dysfunction. The patient’s first resection clearly failed to remove the entire epileptogenic zone, as the seizures recurred. However, after placement of the PM, there was a change in seizure semiology and a reduction in seizure frequency, raising the possibility that ictal preservation of consciousness and decreased seizure frequency were due to the firing of the PM. Some AEDs, such as carbamazepine and phenytoin, are known to have modulatory effects on the ANS, but this patient received neither. Likewise, after resection of the residual epileptogenic zone, an improvement in cardiac function, as manifested by a decreased necessity for PM firing, was seen. This case report illustrates the intricate relationship between the heart and brain in TLE, and provides the impetus to further investigate this relationship and its therapeutic potential.