

THE CLINICAL PICTURE

FEDERICO BISCETTI, MD*

Laboratory of Vascular Biology and Genetics, Department of Medicine, A. Gemelli University Hospital, Catholic University School of Medicine, Rome, Italy

GIUSEPPE STRAFACE, MD

Unit of Vascular Medicine and Mass Spectrometry Laboratory, Department of Internal Medicine, Sapienza University of Rome, Italy

GIULIA DE ANGELIS, MD

Department of Infectious Diseases, A. Gemelli University Hospital, Catholic University School of Medicine, Rome, Italy

ANDREA FLEX, MD

Laboratory of Vascular Biology and Genetics, Department of Medicine, A. Gemelli University Hospital, Catholic University School of Medicine, Rome, Italy

The Clinical Picture

Yellow nails, ankle edema, and pleural effusion

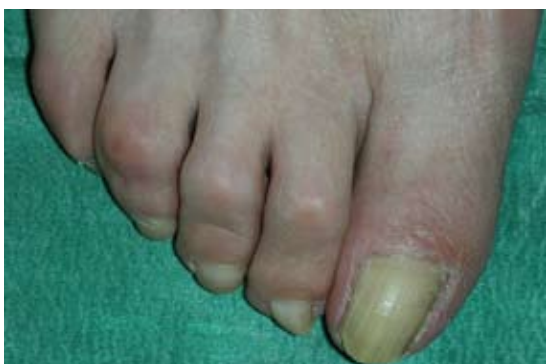

FIGURE 1.

A 57-YEAR-OLD WOMAN SAYS that for the past 30 years she has been aware of thickening, reduction in the growth rate, and yellow discoloration of the nail beds of her fingers and toes. Nail clippings were cultured about 10 years ago, but no fungus was isolated. About 7 years after she first noticed the nail changes, she developed pitting edema of the ankles without evidence of cardiac failure, and she was put on a diuretic.

A chest radiograph taken 8 years ago during a health examination was normal. However, 1 month before admission to our department, she began experiencing exertional dyspnea, with productive cough but no fever.

She has never traveled abroad, has no history of hypertension or ischemic cardiomyopathy, has never undergone surgery, and has no history of tuberculosis.

■ EXAMINATION AND TESTING

On examination, the patient has thickened yellowish nails on all fingers and toes (FIGURE 1). Radiography and computed tomography

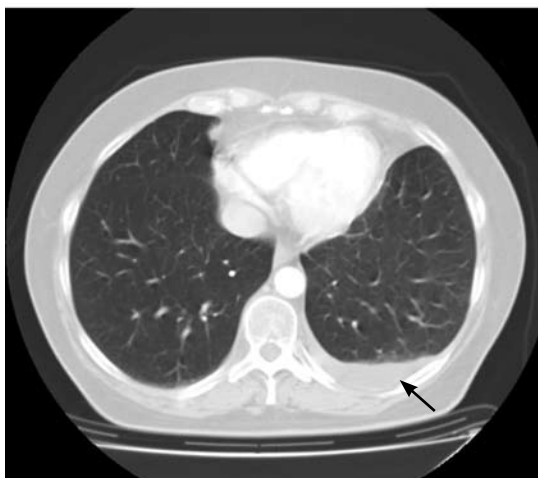
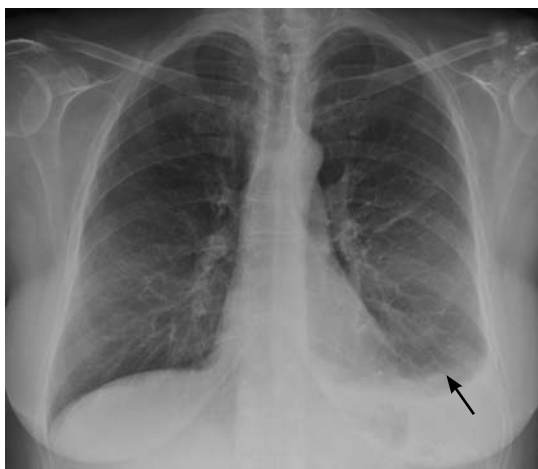

FIGURE 2. Radiography (top) and computed tomography (bottom) revealed a unilateral pleural effusion (arrows).

(FIGURE 2) show a unilateral pleural fluid accumulation but no obvious inflammatory changes or tumor.

Thoracentesis reveals an exudative pleural fluid with a high protein concentration, a

doi:10.3949/ccjm.76a.08050

normal lactate dehydrogenase concentration, and an elevated lymphocyte count.

Q: Which of the following is the most likely diagnosis?

- Cardiac failure
- Yellow nail syndrome
- Infection
- Neoplastic disease

A: The correct diagnosis is yellow nail syndrome, a rare disorder characterized by yellow nails, lymphedema, and chronic respiratory manifestations. However, patients rarely present with all three parts of the triad, and fewer than half of patients present with pleural effusions.

The respiratory manifestations of yellow nail syndrome are diverse and include pleural effusion, bronchiectasis, rhinosinusitis, chronic cough, and recurrent lung infections. Furthermore, this syndrome is in the differential diagnosis of chronic pleural effusions lasting more than 1 year, and also of bronchiectasis and rhinosinusitis.

The pathophysiology of yellow nail syndrome remains unclear, but various anatomic or functional lymphatic drainage abnormalities have been proposed as the underlying cause.

Therapy includes bronchopulmonary hygiene (eg, postural drainage); inhaled steroids and antibiotics to control exacerbations of symptoms; serial thoracentesis or pleuro-

desis to control pleural effusions; and lymphatic drainage and diuretic drugs for lymphedema. Some experts propose vitamin E for the treatment of yellow nails, but yellow nails often improve spontaneously.

■ CASE CONCLUDED

In this case, the diagnosis of yellow nail syndrome was based on the presence of its three major features. She had no history of hypertension or ischemic cardiomyopathy, and no echocardiographic signs of cardiac failure. She had no signs of infection or malignancy and had never taken antirheumatic drugs such as D-penicillamine (Cuprimine, Depen), which can cause pleural effusion, and nothing in her history or presentation suggested an immunosuppressed state.

Her treatment involved thoracentesis to reduce the pleural effusion, correction of her nutritional status, a low-salt diet, vitamin E supplementation, and diuretics. At discharge, her pleural effusion and lymphedema were reduced, and her dyspnea had resolved.

■ SUGGESTED READING

Maldonado F, Tazelaar HD, Wang CW, Ryu JH. Yellow nail syndrome: analysis of 41 consecutive patients. *Chest* 2008; 134:375–381.

ADDRESS: Federico Biscetti, MD, Department of Internal Medicine, Catholic University School of Medicine, Largo Agostino Gemelli 8, Rome 00168, Italy; e-mail f.biscetti@gmail.com.

Lymphatic drainage abnormalities have been proposed as the underlying cause