

**EDUCATIONAL OBJECTIVE:** Readers will distinguish the phases of hepatitis B virus infection**IBRAHIM A. HANOUNEH, MD**Department of General Internal Medicine,  
Cleveland Clinic**RAMI KHORIATY, MD**Department of General Internal Medicine,  
Cleveland Clinic**NIZAR N. ZEIN, MD**Mikati Foundation Endowed Chair in Liver  
Diseases; Chief, Section of Hepatology;  
Medical Director of Liver Transplantation,  
Department of Gastroenterology  
and Hepatology, Transplantation Center,  
Cleveland Clinic

# A 35-year-old Asian man with jaundice and markedly high aminotransferase levels

A 35-YEAR-OLD man who was born in Vietnam presents to the emergency department of a local hospital because he has had jaundice for 5 days and fatigue, malaise, and anorexia for 2 weeks. He also has nausea and mild epigastric and right upper quadrant abdominal pain. He denies having fevers, chills, night sweats, vomiting, diarrhea, melena, hematochezia, or weight loss.

His medical history is remarkable only for perinatally acquired hepatitis B virus (HBV) infection, for which he never received antiviral therapy. He does not take any prescribed, over-the-counter, or herbal medications.

He lives in the Midwest region of the United States and works full-time as a physician in private practice. He is married and has two children.

He has not travelled recently. He has no pets at home and has not been exposed to any.

He has never smoked. He drinks alcohol socially but has never used recreational drugs.

In a laboratory evaluation performed a year ago for insurance purposes, his liver function tests—serum albumin, total bilirubin, alkaline phosphatase, alanine aminotransferase, and aspartate aminotransferase levels—were all normal. He was positive for HBV surface antigen and HBV e antigen and negative for antibodies against these antigens.

## ■ PHASES OF HBV INFECTION

**1** Which of the following best describes the status of HBV infection in this patient before his current symptoms developed?

- ☐ Resolved HBV infection
- ☐ Chronic inactive HBV infection
- ☐ Chronic active HBV infection
- ☐ Immune-tolerant chronic HBV infection

The correct answer is immune-tolerant chronic HBV infection.

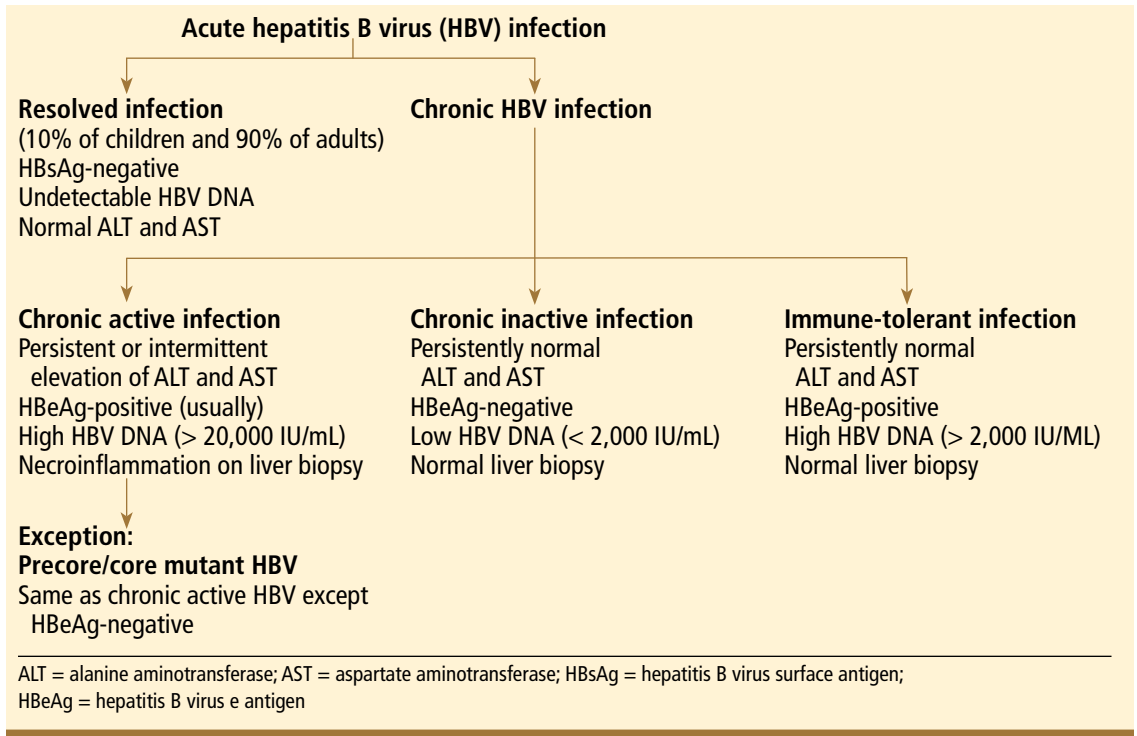
**Resolved infection.** In immunocompetent adults, most primary HBV infections are self-limited: people clear the virus and gain lasting immunity (defined as the loss of HBV surface antigen, the development of antibody against surface antigen, no detectable HBV DNA in the serum, and normal alanine and aspartate aminotransferase levels). However, a minority of primary HBV infections persist and become chronic.

The risk of an HBV infection becoming chronic is higher in immunocompromised patients and in infants and children. In 90% of infected newborns, the disease progresses to chronic infection, but it does so in only 10% of adults (**FIGURE 1**).

**Chronic HBV infection** is defined as the persistence of HBV surface antigen in the serum for at least 6 months. Patients with chronic HBV infection can be broadly classified as having either inactive disease (the inactive surface antigen carrier state) or chronic active hepatitis B (**FIGURE 1**).<sup>1-9</sup>

**Chronic inactive HBV infection.** Carri-

**The patient acquired HBV at birth and was never treated for it**



**FIGURE 1.** Clinical course of hepatitis B virus infection

**In adults, only  
about 10%  
of acute HBV  
infections  
become chronic**

ers of inactive HBV infection have low serum levels of HBV DNA (< 2,000 IU/mL), persistently normal aminotransferase levels, and no HBV e antigen; if a liver biopsy is performed, no significant hepatitis is found.

**Chronic active HBV infection.** Patients with chronic active HBV infection, in contrast, have high serum HBV DNA levels (> 20,000 IU/mL) and persistently or intermittently high aminotransferase levels; they do have HBV e antigen, and a liver biopsy shows moderate or severe necroinflammation.

A small group of patients with chronic active hepatitis B may be negative for e antigen but still have high aminotransferase levels, high HBV DNA levels, and continued necroinflammation in the liver.<sup>4</sup> The virus in these patients has a mutation in its precore or core promoter gene that prevents the production of e antigen.

Patients with chronic active HBV infection (whether positive or negative for e antigen) are at a significantly greater risk of progressive liver injury and developing cirrhosis and hepatocellular carcinoma than are inactive carriers of HBV.

**Immune-tolerant chronic HBV infection.** Patients who acquired HBV at birth (eg,

our patient) may have immune-tolerant HBV infection, which is characterized by significant HBV replication manifested by the presence of HBV e antigen and high levels of HBV DNA in the serum. However, these patients have no clinical or pathologic evidence of active liver disease (no symptoms, normal serum alanine aminotransferase levels, and minimal changes on liver biopsy).<sup>5</sup> This was obviously the case in our patient, based on his history and laboratory results before his current symptoms developed.

## Case continues: Liver function abnormalities

On physical examination, the patient's temperature is 99.9°F (37.7°C), heart rate 106 per minute, blood pressure 98/54 mm Hg, respiratory rate 18 per minute, and oxygen saturation 100% while breathing ambient air. He is alert and oriented to time, place, and person.

He has icteric sclera, and his skin is jaundiced. His lymph nodes are not palpable. His cardiac examination is normal except for tachycardia. His lungs are clear to auscultation and percussion. He has mild epigastric and right upper quadrant abdominal tender-

ness with no peritoneal signs, hepatosplenomegaly, or masses.

He has no asterixis, and his complete neurologic examination is normal. His extremities are normal, with no edema.

His basic laboratory values on admission are listed in **TABLE 1**. His amylase and lipase levels are normal. A urine dipstick test is positive for bilirubin.

### ■ WHAT IS THE LEAST LIKELY DIAGNOSIS?

**2** Which one of the following is the *least* likely diagnosis in this patient?

- ☐ Reactivation of hepatitis B
- ☐ Drug-associated liver injury
- ☐ Acute viral hepatitis
- ☐ Acute alcoholic hepatitis
- ☐ Ischemic hepatitis

The degree and pattern of liver function abnormalities in our patient reflect hepatocellular injury rather than cholestatic liver disease, because his aminotransferase levels are elevated much higher than his alkaline phosphatase level (**TABLE 1**). Bilirubin elevation does not help differentiate the two conditions.

The degree and pattern of aminotransferase elevations are also helpful in narrowing the differential diagnosis. Serum aminotransferase levels of more than 1,000 U/L are mainly seen in patients with ischemic, viral, and toxin-induced liver injury. Other rare causes of such high levels include Budd-Chiari syndrome, Wilson disease, and autoimmune hepatitis.

**Ischemic hepatitis.** Our patient has mild hypotension, but it does not seem to have been severe enough or of long enough duration to have caused ischemic hepatitis.

**Drug-associated liver injury.** Hepatotoxicity associated with drugs (most commonly acetaminophen [Tylenol]), herbal therapy, or mushroom poisoning should be considered in any patient whose aminotransferase levels are this high. However, our patient denies taking any medications (prescribed or over-the-counter), herbal remedies, or illicit drugs.

**Acute viral hepatitis** can certainly explain the patient's clinical picture. Infection with hepatitis A virus, hepatitis D virus, hepatitis E virus, cytomegalovirus, Epstein-Barr virus, herpes simplex viruses types 1 and 2, and va-

**TABLE 1**

### The patient's laboratory values on admission

TEST	RESULTS	NORMAL RANGE
<b>Sodium</b>	141 mmol/L	132–148
<b>Potassium</b>	3.7 mmol/L	3.5–5.0
<b>Chloride</b>	110 mmol/L	98–111
<b>Bicarbonate</b>	16 mmol/L	23–32
<b>Blood urea nitrogen</b>	25 mg/dL	8–25
<b>Creatinine</b>	0.6 mg/dL	0.7–1.4
<b>Glucose</b>	87 mg/dL	65–100
<b>Hemoglobin</b>	16.3 g/dL	12–16
<b>White blood cell count</b>	$4.8 \times 10^9/L$	4–11
<b>Platelet count</b>	$120 \times 10^9/L$	150–400
<b>Alanine aminotransferase</b>	2,743 U/L	0–45
<b>Aspartate aminotransferase</b>	2,310 U/L	7–40
<b>Alkaline phosphatase</b>	190 U/L	40–150
<b>Bilirubin, total</b>	17.4 mg/dL	0–1.5
<b>Albumin</b>	3.2 g/dL	3.5–5
<b>International normalized ratio</b>	3.4	0.77–1.17
<b>Partial thromboplastin time</b>	52.5 seconds	22–35

ricella zoster virus have all been implicated in severe acute hepatitis. Although hepatitis E virus infection is more common in developing countries, it has been reported in the United States.<sup>6</sup> It is unlikely that acute hepatitis C virus infection is producing this degree of elevation in aminotransferase levels.

**Reactivation of the patient's chronic HBV infection** can also account for his clinical presentation.

**Acute alcoholic hepatitis** should be suspected clinically if a patient has a history of heavy alcohol use and clinical and laboratory findings that are compatible with the diagnosis. However, the absolute values of serum aspartate aminotransferase and alanine aminotransferase in acute alcoholic hepatitis are almost always less than 500 IU/L (and typically less than 300 IU/L). Our patient's values are much higher, and he says he does not drink very much. Although people sometimes underestimate their alcohol intake, alcoholic hepatitis is the least likely diagnosis in our patient.

TABLE 2

## His viral serologic test results

TESTS	RESULTS
Hepatitis A virus IgM	Negative
Hepatitis C virus IgM	Negative
Hepatitis D virus antigen	Negative
Hepatitis E virus antigen	Negative
Hepatitis B virus (HBV) surface antigen	Positive
HBV surface antibody	Negative
HBV core IgM	Positive
HBV core IgG	Positive
HBV e antigen	Negative
HBV e antibody	Negative
Herpes simplex virus (HSV) IgM	Positive
HSV IgG	Positive
HSV-1 DNA	Negative
HSV-2 DNA	Negative
Epstein-Barr virus DNA	Negative
Cytomegalovirus DNA	Negative
Varicella zoster virus DNA	Negative
Hepatitis C virus RNA	Negative
HBV DNA	> 5 million IU / mL

HBV = hepatitis B virus; HSV = herpes simplex virus; Ig = immunoglobulin

## Case continues: The patient is hospitalized

The patient is admitted with a diagnosis of acute hepatitis. Given his history of chronic hepatitis B, he is empirically started on lamivudine (Epivir-HBV).

Results of his serologic tests for viruses implicated in acute hepatitis are shown in TABLE 2. Results of further blood tests:

- Antinuclear antibody negative
- Autoimmune liver disease panel negative
- Serum ceruloplasmin 30 mg/dL (normal range 15–60)
- Alpha fetoprotein 35.1 µg/L (< 10).

Abdominal ultrasonography is performed and reveals a small stone in the gallbladder with no evidence of biliary dilatation; otherwise, the gallbladder appears normal. Doppler ultrasonography shows the liver vessels to be patent; the liver is normal in appearance. The abdomen and

pelvis appear to be normal on computed tomography without intravenous contrast.

On the third hospital day, the patient's blood test results are:

- Aspartate aminotransferase 199 U/L (normal range 7–40)
- Alanine aminotransferase 735 U/L (0–45)
- Total bilirubin 22.9 mg/dL (0–1.5)
- International normalized ratio 6.0 (0.77–1.17)
- White blood cell count  $5.1 \times 10^9/L$  (4–11)
- Hemoglobin 11.7 g/dL (12–16)
- Platelet count  $166 \times 10^9/L$  (150–400)
- Blood and urine cultures negative.

## WHAT IS CAUSING HIS ACUTE HEPATITIS?

**3** On the basis of the new data, which of the following statements about the cause of acute hepatitis in this patient is the most accurate?

- ☐ Herpetic hepatitis is the most likely cause, given his positive test for immunoglobulin M (IgM) against herpes simplex virus
- ☐ Hepatitis C cannot be excluded with the available data
- ☐ Negative HBV e antigen does not exclude the diagnosis of acute exacerbation of HBV infection
- ☐ Hepatocellular carcinoma is the likely diagnosis, given the elevated alpha fetoprotein level

The third answer above is correct: a negative test for hepatitis B e antigen does not exclude the diagnosis of acute exacerbation of HBV infection

**Herpetic hepatitis.** Although not common, hepatitis due to herpes simplex virus infection should be considered in the differential diagnosis of any patient presenting with severe acute hepatitis, particularly when fever is present. Common features of herpetic hepatitis on presentation include high fever, leukopenia, markedly elevated aminotransferases, and mild cholestasis. Vesicular rash occurs in only less than half of cases of herpetic hepatitis.<sup>10</sup>

Serologic testing is of limited value because it has high rates of false-positive and false-negative results. The diagnosis can be confirmed only by viral polymerase chain reaction testing or by identifying herpes simplex viral inclusions in the liver biopsy.

However, the death rate is high in this disease, and since herpetic hepatitis is one of the few treatable causes of acute liver failure, parenteral acyclovir (Zovirax) should be considered empirically in patients presenting with acute liver failure. Our patient was started on acyclovir when his tests for IgM against herpes simplex virus came back positive.

**Hepatitis C.** Antibodies against hepatitis C virus do not develop immediately after this virus is contracted; they may take up to 12 weeks to develop after exposure. For this reason, about 30% to 50% of patients with acute hepatitis C virus infection are negative for these antibodies initially. In those patients, hepatitis C virus RNA in the blood is the most sensitive test to detect acute hepatitis C virus infection.

Our patient has neither antibodies against hepatitis C virus nor hepatitis C virus RNA by polymerase chain reaction testing, which rules out hepatitis C virus infection.

**Disappearance of e antigen in HBV infection.** The disappearance of HBV e antigen is usually associated with a decrease in serum HBV DNA and remission of liver disease. However, some patients continue to have active liver disease and high levels of HBV DNA despite e antigen seroconversion. This is due to a stop codon mutation in the pre-core region of the viral genome that decreases or prevents production of HBV e antigen.<sup>4</sup> In other words, even though HBV e antigen is a good marker of HBV replication in general, a subgroup of patients with chronic HBV infection are negative for e antigen but still have a high rate of viral replication as evidenced by high serum HBV DNA levels.

Patients with perinatally acquired chronic HBV infection most often have immune-tolerant chronic HBV infection. Among those patients (mostly Asian),<sup>5,7</sup> the virus is spontaneously cleared at a rate of approximately 2% to 3% per year,<sup>8</sup> most often during the second and third decades of age.

Transition from the immune-tolerant phase to the immune clearance phase is frequently associated with mild transient worsening of the liver function profile.<sup>9,11,12</sup> However, in a small percentage of patients, hepatic decompensation and even (rarely) death from hepatic failure may occur secondary to a sudden activation of the immune system as it at-

tempts to clear the virus. This may result in an increase in immune-mediated lysis of infected hepatocytes.

**Hepatocellular carcinoma.** Exacerbation of hepatitis B may be associated with an elevation of alpha fetoprotein, which may falsely raise concerns about the possibility of hepatocellular carcinoma. However, our patient had abdominal imaging with both ultrasonography and computed tomography, which showed no evidence of hepatocellular carcinoma.

**Comment.** The most likely cause of the patient's acute liver failure is an acute exacerbation of hepatitis B. However, herpetic hepatitis should be ruled out by testing for herpes simplex virus by polymerase chain reaction, performing a liver biopsy, or both.

### Case continues: His condition worsens

A transjugular liver biopsy shows changes associated with chronic hepatitis B, severe acute hepatitis with extensive confluent and submassive hepatic necrosis, and no intracellular viral inclusions. Subsequently, acyclovir is stopped.

On the 6th hospital day, he develops progressive metabolic acidosis and hypotension, with worsening hypoxemia. A chest radiograph is obtained to look for pneumonia, but it is indeterminate; computed tomography of the chest without contrast medium is likewise unremarkable. Duplex ultrasonography of the four extremities is negative for venous thrombosis.

The patient becomes more lethargic and difficult to arouse. He is transferred to the intensive care unit and intubated. His prothrombin and partial thromboplastin times continue to rise, the prothrombin time reaching values of more than 50 seconds. In addition, progressive renal insufficiency develops.

### WHAT IS THE NEXT STEP?

**4** Which of the following is the most appropriate next step in the management of this patient?

- ☐ Liver transplantation
- ☐ HBV immunoglobulin only
- ☐ Interferon and a nucleoside analogue
- ☐ Liver-assist devices
- ☐ Continue supportive care only

**His ALT and AST are much higher than his alkaline phosphatase, suggesting hepatocellular injury**



TABLE 3

### King's College criteria for predicting poor prognosis in acute liver failure

#### In acute liver failure from acetaminophen (Tylenol) toxicity

Arterial pH < 7.3

Or all of the following:

Encephalopathy grade III or IV

Prothrombin time > 100 seconds

Creatinine > 3.4 mg/dL

#### In acute liver failure from other causes

Prothrombin time > 100 seconds

Or three of the following:

Age < 10 years or > 40 years

Prothrombin time > 50 seconds

Total bilirubin > 18 mg/dL

More than 7 days of jaundice before the onset of encephalopathy

Non-A and non-B hepatitis, halothane-induced hepatitis, or hepatitis from idiosyncratic drug reactions

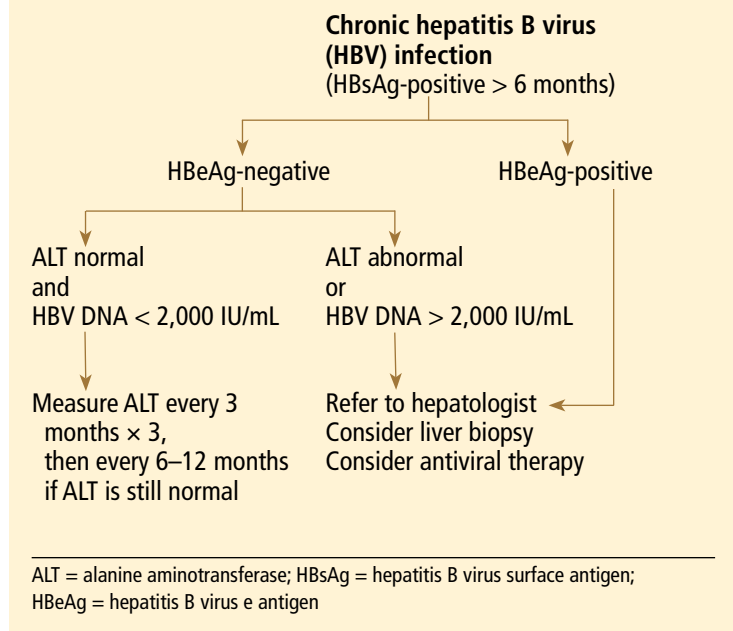
BASED ON O'GRADY J, ALEXANDER G, HAYLLAR K, WILLIAMS R. EARLY INDICATORS OF PROGNOSIS IN FULMINANT HEPATIC FAILURE. GASTROENTEROLOGY 1989; 97:439-445.

**Consider empiric parenteral acyclovir if the patient presents with severe acute liver failure**

**Liver transplantation.** Since the patient's severe acute hepatitis is accompanied by coagulopathy and encephalopathy, he meets the definition of having acute liver failure. Liver transplantation remains the only definitive therapy.

The most commonly used prognostic criteria in patients with acute liver failure are those developed at the King's College Hospital (TABLE 3).<sup>13</sup> Several studies have shown these criteria to have positive predictive values ranging from slightly less than 70% to nearly 100% and negative predictive values ranging from 25% to 94%.<sup>14-16</sup> According to the King's College Hospital criteria, our patient has a poor prognosis (having a prothrombin time > 50 seconds, total bilirubin > 18 mg/dL, and jaundice for more than 7 days before the onset of encephalopathy) and may benefit from liver transplantation.

**HBV immune globulin immunoprophylaxis** is indicated in patients with HBV infection undergoing liver transplantation, to prevent recurrence of hepatitis B after the transplant, particularly in those with a high pretransplant viral load.<sup>17</sup> The use of pretrans-



**FIGURE 2.** Evaluation of patients with chronic hepatitis B virus infection

plant antiviral therapy and the posttransplant combination of antiviral therapy and HBV immune globulin has reduced the rate of hepatitis B recurrence to less than 10%. However, immune globulin is by no means the best single next step in managing this patient, who clearly needs a new liver.

**Interferon, nucleoside analogues.** Options for antiviral treatment are interferon alfa and nucleoside analogues. Interferon therapy is contraindicated in patients such as ours, who have decompensated liver disease, because it can exacerbate the disease.<sup>18</sup>

Treatment with a nucleoside analogue—lamivudine (Epivir), adefovir (Hepsera), entecavir (Baraclude), telbivudine (Tyzeka), or tenofovir (Viread)—is a safe and well-tolerated alternative in those with decompensated liver disease. The major complication of long-term lamivudine therapy is the emergence of resistant viral strains. There is no evidence that combination therapy with interferon and lamivudine is superior to antiviral monotherapy in improving the treatment outcome; however, combination therapy may decrease the rate of lamivudine-resistant mutations.

The suggested evaluation of patients with chronic HBV infection is shown in FIGURE 2.

TABLE 4 shows the current recommendations for treating it.<sup>18,19</sup>

**Liver-assist devices.** Because liver allografts are in short supply, there has been a strong interest in developing a device that would provide the same benefits for patients with liver failure as hemodialysis does for patients with renal failure. Trials are under way to determine the efficacy and safety of these devices.<sup>20</sup>

### Case continues: He receives a liver

The patient undergoes liver transplantation. He is given HBV immune globulin during and after the surgery.

**Pathologic review.** Under the microscope, his old liver has widespread necrosis and hemorrhage as well as inflammatory changes suggesting a chronic viral process. Regenerative nodules are present in the small amount of surviving liver parenchyma, consistent with early cirrhosis. Iron staining shows +3 depositions in areas of hepatic collapse (a nonspecific finding). Periodic acid-Schiff staining after diastase (used to detect alpha-1 antitrypsin deficiency) is negative. Herpetic viral inclusions are not present.

An immunoassay for herpes simplex virus antigen is negative. Immunostaining with antibodies to the HBV core antigen is negative. HBV surface antigen is strongly and diffusely positive in the cytoplasm of 80% to 90% of hepatocytes. The immunohistologic staining pattern is consistent with integration of HBV DNA into the DNA of hepatic tissue.

**Postoperative course.** Lamivudine is continued after surgery, and the patient is sent home. He has resumed the level of functioning he had before becoming ill.

**Comment.** The outcome of liver transplantation for hepatitis B has notably improved since HBV immune globulin and nucleoside analogues were introduced. The results of liver transplantation for hepatitis B, particularly patient and graft survival rates, are now better than those in transplant patients with hepatitis C and similar to those in transplant patients with other types of liver disease.<sup>21</sup> The combination of HBV immune globulin and lamivudine has cut the rate of HBV reinfection after liver transplantation to approximately 10% and increased the 5-year survival rate after transplantation to about 80%.<sup>17,22</sup>

TABLE 4

### Recommendations for treating chronic hepatitis B

CATEGORY	TREATMENT	INTERFERON	NUCLEOSIDE ANALOGUE
Inactive carrier	No <sup>a</sup>		
Immune tolerant	No <sup>a</sup>		
Chronic active <sup>b</sup>	Yes	Yes	Yes
Decompensated liver disease <sup>c</sup>	Yes	No	Yes
Immunocompromised	Yes	No	Yes

<sup>a</sup>Treatment may be considered with either interferon or a nucleoside analogue if the patient has a high viral load (> 2,000 IU/mL), elevated aminotransferase levels, or active disease on liver biopsy

<sup>b</sup>Whether positive or negative for e antigen

<sup>c</sup>Liver transplantation should be considered

### KEY POINTS

- In immunocompetent adults, most primary HBV infections are self-limited.
- Chronic HBV infection is defined as the persistence of HBV surface antigen in the serum for at least 6 months. Patients having chronic HBV infection can be broadly classified as inactive carriers or having chronic active disease.
- Most patients with chronic active HBV infection are positive for HBV e antigen, except patients in whom the virus has a mutation in the precore or core region of its genome that prevents the production of e antigen.
- Patients who carry inactive HBV or who are immune-tolerant require serial measurements of aminotransferase and HBV DNA levels. Treatment can be considered if the patient has a high viral load (> 2,000 IU/mL), elevated aminotransferases, or active disease on liver biopsy.
- Carriers of chronic active HBV (whether positive or negative for HBV e antigen) should be referred to a hepatologist for consideration of liver biopsy and treatment.
- Interferon should not be used in immunocompromised patients or those with decompensated liver disease because it can further exacerbate the liver disease.

**In a subgroup, HBV mutates and no longer can produce e antigen**

- Liver transplantation should be considered in patients with acute liver failure who

have a poor prognosis according to the King's College Hospital criteria. ■

## REFERENCES

1. **Dusheiko G.** Hepatitis B. In: Bircher J, Benhamou JP, McIntyre N, Rizzetto M, Rodes J, editors. *Oxford Textbook of Clinical Hepatology*. 2nd ed. Oxford, UK: Oxford University Press; 1999:876–896.
2. **Chu CJ, Hussain M, Lok AS.** Quantitative serum HBV DNA levels during different stages of chronic hepatitis B infection. *Hepatology* 2002; 36:1408–1415.
3. **Pawlotsky JM, Bastie A, Hezode C, et al.** Routine detection and quantification of hepatitis B virus DNA in clinical laboratories: performance of three commercial assays. *J Virol Methods* 2000; 85:11–21.
4. **Brunetto MR, Giarin MM, Oliveri F, et al.** Wild-type and e-antigen-minus hepatitis viruses and course of chronic hepatitis. *Proc Natl Acad Sci USA* 1991; 88:4186–4190.
5. **Lok AS, Lai CL.** A longitudinal follow-up of asymptomatic hepatitis B surface antigen-positive Chinese children. *Hepatology* 1988; 5:1130–1133.
6. **Hsu HY, Chang MH, Hsieh KH, et al.** Cellular immune response to HBcAg in mother-to-infant transmission of hepatitis B virus. *Hepatology* 1992; 15:770–776.
7. **Chang MH, Hsu HY, Hsu HC, Ni YH, Chen JS, Chen DS.** The significance of spontaneous hepatitis B e antigen seroconversion in childhood: with special emphasis on the clearance of hepatitis B e antigen before 3 years of age. *Hepatology* 1995; 22:1387–1392.
8. **Ruiz-Moreno M, Otero M, Millan A, et al.** Clinical and histological outcome after hepatitis B e antigen to antibody seroconversion in children with chronic hepatitis B. *Hepatology* 1999; 29:572–575.
9. **Liaw YF, Chu CM, Su JJ, Huang MJ, Lin DY, Chang-Chien CS.** Clinical and histological events preceding hepatitis B e antigen seroconversion in chronic type B hepatitis. *Gastroenterology* 1983; 84:216–219.
10. **Norvell JP, Blei AT, Jovanovic BD, Levitsky J.** Herpes simplex virus hepatitis: an analysis of the published literature and institutional cases. *Liver Transplant* 2007; 13:1428–1434.
11. **Liaw YF, Pao CC, Chu CM, Sheen IS, Huang MJ.** Changes of serum hepatitis B virus DNA in two types of clinical events preceding spontaneous hepatitis B e antigen seroconversion in chronic type B hepatitis. *Hepatology* 1987; 7:1–3.
12. **Maruyama T, Iino S, Koike K, Yasuda K, Milich DR.** Serology of acute exacerbation in chronic hepatitis B virus infection. *Gastroenterology* 1993; 105:1141–1151.
13. **O'Grady JG, Alexander GJ, Hayllar KM, Williams R.** Early indicators of prognosis in fulminant hepatic failure. *Gastroenterology* 1989; 97:439–445.
14. **Shakil AO, Kramer D, Mazariegos GV, Fung JJ, Rakela J.** Acute liver failure: clinical features, outcome analysis, and applicability of prognostic criteria. *Liver Transplant* 2000; 6:163–169.
15. **Anand AC, Nightingale P, Neuberger JM.** Early indicators of prognosis in fulminant hepatic failure: an assessment of the King's criteria. *J Hepatol* 1997; 26:62–68.
16. **Schmidt LE, Dalhoff K.** Serum phosphate is an early predictor of outcome in severe acetaminophen-induced hepatotoxicity. *Hepatology* 2002; 36:659–665.
17. **Samuel D, Muller R, Alexander G, et al.** Liver transplantation in European patients with the hepatitis B surface antigen. *N Engl J Med* 1993; 329:1842–1847.
18. **Lok A, McMahon BJ.** Chronic hepatitis B. *Hepatology* 2007; 45:507–539.
19. **Sorren MF, Belangia EA, Costa J, et al.** National Institutes of Health consensus development conference statement: management of hepatitis B. *Ann Intern Med* 2009; 150:104–110.
20. **Kjaergard LL, Liu J, Als-Nielsen B, Gluud C.** Artificial and bioartificial support systems for acute and acute-on-chronic liver failure: a systematic review. *JAMA* 2003; 289:217–222.
21. **Kim WR, Poterucha JJ, Kremers WK, Ishitani MB, Dickson ER.** Outcome of liver transplantation for hepatitis B in the United States. *Liver Transplant* 2004; 10:968–974.
22. **Terrault NA, Zhou S, Combs C, et al.** Prophylaxis in liver transplant recipients using a fixed dosing schedule of hepatitis B immunoglobulin. *Hepatology* 1996; 24:1327–1333.

ADDRESS: Nizar N. Zein, MD, Digestive Disease Institute, A30, Cleveland Clinic, 9500 Euclid Avenue, Cleveland, OH 44195; e-mail zeinn@ccf.org.