

THE CLINICAL PICTURE

SALVADOR ARIAS-SANTIAGO, MD

Department of Dermatology, San Cecilio University Hospital, Granada, Spain

HUSEIN HUSEIN-ELAHMED, MD

Department of Dermatology, San Cecilio University Hospital, Granada, Spain

JOSÉ ANEIRO-FERNÁNDEZ, MD

Department of Pathology, San Cecilio University Hospital, Granada, Spain

MARÍA SIERRA GIRÓN-PRIETO, MD

Department of Dermatology, San Cecilio University Hospital, Granada, Spain

RAMÓN NARANJO-SINTES, PhD

Department of Dermatology, San Cecilio University Hospital, Granada, Spain

The Clinical Picture

Palmoplantar eruption

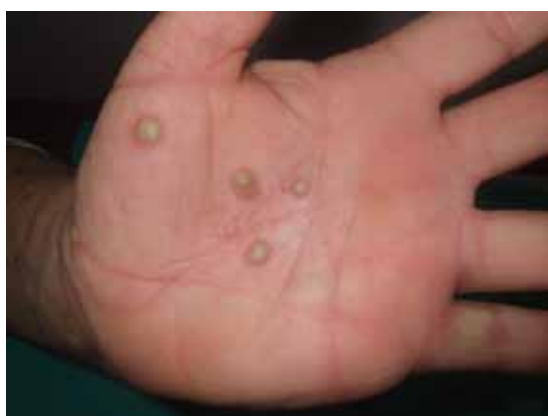

FIGURE 1

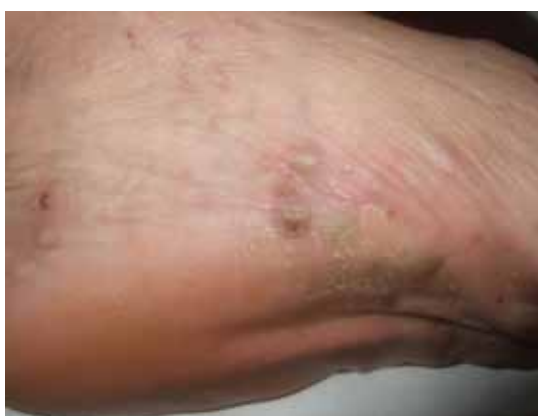

FIGURE 2

A 38-YEAR-OLD WOMAN presents with recurrent asymptomatic lesions on the palms and soles and on the sides of both feet. The lesions have been developing for 2 months, unaccompanied by fever or other systemic symptoms.

She has a history of episodes of arthritis of the anterior chest wall, which she has treated with nonsteroidal anti-inflammatory drugs (NSAIDs).

Physical examination reveals pustules on the palms and soles (**FIGURE 1** and **FIGURE 2**). No lesions are noted on the oral and genital mucosae.

Laboratory tests of C-reactive protein, erythrocyte sedimentation rate, viral serologies, and antinuclear antibodies are normal. A pustule culture is negative, and a cutaneous biopsy shows parakeratosis and elongation of rete ridges, neutrophils migrating from papillary capillaries to the epidermis, and spongiform Kogoj pustule.

Thoracic radiography shows increased

density in the sternoclavicular joints, and a three-phase technetium-99m-labeled bone scan and gallium scan reveal radionuclide uptake in the sternoclavicular and manubriosternal joints (**FIGURE 3**). Computed tomography of the thorax and abdomen reveal no abnormalities.

Q: Which is the most likely diagnosis?

- ☐ Pustular psoriasis
- ☐ Impetigo contagiosa
- ☐ Syndrome of synovitis, acne, pustulosis, hyperostosis, osteitis (SAPHO)
- ☐ Dyshidrotic eczema
- ☐ Acute exanthematous pustulosis (drug eruption)

A: SAPHO syndrome is the most likely diagnosis. The presence of pustules and aseptic osteitis of the anterior chest wall is compatible with SAPHO syndrome. Treatment with topical clobetasol propionate (Temovate) for pustules and NSAIDs for osteitis brought a good response.

Pustular psoriasis is an uncommon type of

The key finding is noninfectious inflammatory osteitis in a patient with skin lesions

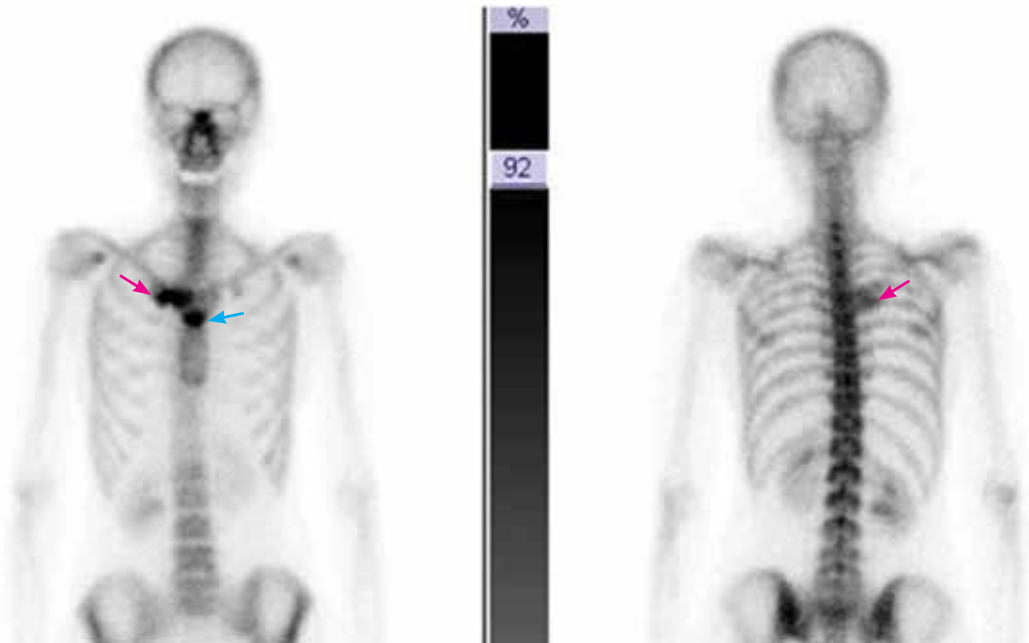


FIGURE 3. Radionuclide uptake in the sternoclavicular joint (red arrows) and manubriosternal joint (blue arrow) was noted on bone scans.

psoriasis characterized by erythema and pustules involving the flexural and anogenital areas. Cutaneous lesions of psoriasis vulgaris may be present before an acute pustular episode. Withdrawal of systemic corticosteroids in a patient with psoriasis has been reported as a precipitating factor.

Impetigo contagiosa is a superficial cutaneous infection characterized by an erythematous macule that evolves into a vesicle or pustule. These lesions are more common in children. Culture of the fluid usually reveals *Staphylococcus aureus* or *S pyogenes*.

Dyshidrotic eczema is a pruritic vesicular eruption of unknown cause on the palm and soles (bilateral and symmetric). The typical histologic findings are spongiotic and intraepidermal vesicles.

Acute exanthematous pustulosis is a drug-induced reaction characterized by confluent erythema, blisters, and pustules, mucous membrane erosions with fever, and lymphadenopathy. Cultures of the pustules are negative, and biopsy can help confirm the diagnosis of drug eruption.

■ SAPHO SYNDROME

SAPHO syndrome is a rare condition of unknown pathogenesis originally described by

Chamot et al¹ in 1987. The onset is usually in young adulthood, and is similar in men and women. It is characterized by synovitis, acne, pustulosis, hyperostosis, and osteitis. Of paramount importance is the finding of a non-infectious inflammatory osteitis in a patient with skin lesions.

Clinical findings:

Pustules plus rheumatic pain

SAPHO syndrome must be suspected when a patient is affected by a pustular skin disease associated with rheumatic pain. If examination shows that the pain is caused by a sterile inflammation of bone or joints, the diagnosis tends to be confirmed.²

Osteoarticular involvement tends to be limited to the anterior chest wall. It may include aseptic osteitis, hyperostosis, and symmetrical arthritis. Peripheral and axial osteitis is one of the main characteristics of the syndrome and is found in around 90% of cases.

Cutaneous manifestations are present in two-thirds of patients and consist chiefly of severe acne (acne fulminans, acne conglobata, and hidradenitis suppurativa), pustular psoriasis, and palmoplantar pustulosis. Neutrophilic dermatoses associated with this syndrome include Sweet syndrome and pyoderma

Suspect SAPHO syndrome if a pustular skin disease is associated with rheumatic pain

gangrenosum. Acne lesions are usually seen in men, whereas palmoplantar pustulosis is seen in women,³ often accompanying osteoarticular manifestations.

Radiologic findings in the spine are spondylodiskitis, osteosclerosis, sacroiliac joint involvement, and paravertebral ossification. In anterior chest wall hyperostosis, common findings are bone hypertrophy and sclerosis with a soft-tissue component. Laboratory test results are uncharacteristic, with variable signs of inflammation, and the C-reactive protein and sedimentation rate are usually elevated in the absence of leukocytosis.

Pathogenesis remains elusive

The pathogenesis of this syndrome remains elusive. Since SAPHO syndrome usually involves the axial skeleton, some investigators have suggested a possible link between the SAPHO syndrome and the seronegative spondyloarthropathies.³ It has also been related to an infection by *Propionibacterium acnes* and *Corynebacterium* species,⁴ which have been isolated in cultures of bone and skin lesions. However, the fact that these bacteria are contaminant agents makes their involvement in the pathogenesis of this syndrome unlikely. More recently, high concentrations of tumor necrosis factor alpha in bone specimens of patients with SAPHO syndrome have been reported, thus highlighting the central role of this cytokine in maintaining inflammation.

Treatment is to relieve symptoms

Since understanding of the pathogenesis of SAPHO syndrome is limited, a wide range of therapies has been used,⁵ mostly to relieve symptoms. These include NSAIDs; steroids; antibiotics; bisphosphonates such as pamidronate (Aredia) and zoledronic acid (Reclast); and immunosuppressors and immunomodulators such as methotrexate (Trexall), leflunomide (Arava), sulfasalazine (Azulfidine), cyclosporine (Sandimmune). The results with these therapies have been quite varied. Good response has been reported with tumor necrosis factor alpha blockers—infliximab (Remicade), etanercept (Enbrel), and adalimumab (Humira).⁶

REFERENCES

1. Chamot AM, Benhamou CL, Kahn MF, Beranek L, Kaplan G, Prost A. Acne-pustulosis-hyperostosis-osteitis syndrome. Results of a national survey. 85 cases [in French]. *Rev Rhum Mal Osteoartic* 1987; 54:187–196.
2. Benhamou CL, Chamot AM, Kahn MF. Synovitis-acne-pustulosis hyperostosis-osteomyelitis syndrome (SAPHO). A new syndrome among the spondyloarthropathies? *Clin Exp Rheumatol* 1988; 6:109–112.
3. Hayem G, Bouchaud-Chabot A, Benali K, et al. SAPHO syndrome: a long-term follow-up study of 120 cases. *Semin Arthritis Rheum* 1999; 29:159–171.
4. Moll C, Hernández MV, Cañete JD, et al. Ilium osteitis as the main manifestation of the SAPHO syndrome: response to infliximab therapy and review of the literature. *Semin Arthritis Rheum* 2008; 37:299–306.
5. Olivieri I, Padula A, Palazzi C. Pharmacological management of SAPHO syndrome. *Expert Opin Investig Drugs* 2006; 15:1229–1233.
6. Arias-Santiago S, Sanchez-Cano D, Callejas-Rubio JL, Fernández-Pugnaire MA, Ortego-Centeno N. Adalimumab treatment for SAPHO syndrome. *Acta Derm Venereol* 2010; 90:301–302.

ADDRESS: Salvador Arias-Santiago, MD, San Cecilio University Hospital, Av Dr. Olóriz 16, Granada 18012, Spain; e-mail salvadorarias@hotmail.es.