

## THE CLINICAL PICTURE

**MING-JU TSAI, MD**

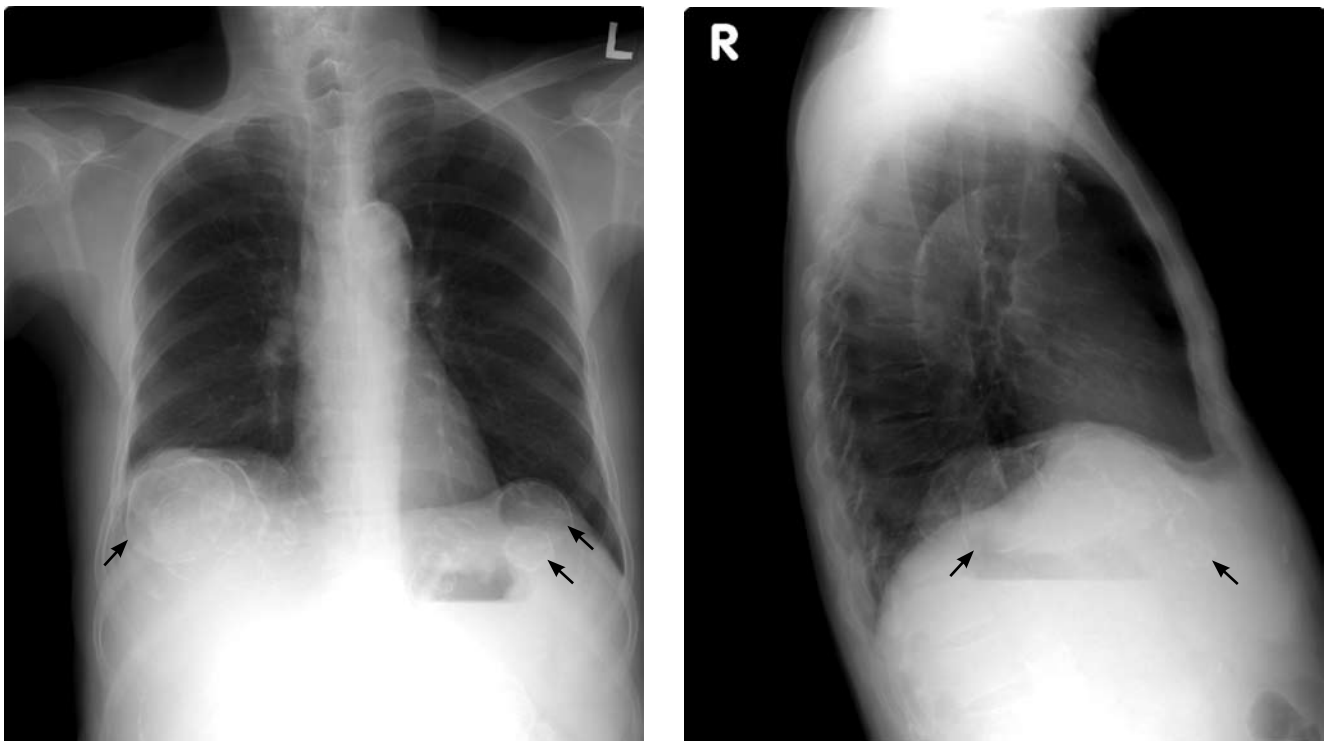
Department of Internal Medicine, Kaohsiung Medical University Hospital, Kaohsiung Medical University, Kaohsiung, Taiwan

**HUNG-CHUN CHEN, MD, PhD**

Department of Internal Medicine, Kaohsiung Medical University Hospital and Faculty of Renal Care, Kaohsiung Medical University, Kaohsiung, Taiwan

# The Clinical Picture

## Calcified cysts in the upper abdomen



**FIGURE 1.** Chest radiographs show multiple calcified cystic lesions in the upper abdomen (arrows).

**A** 69-YEAR-OLD MAN has been on hemodialysis for about 15 years. Routine plain chest radiographs (**FIGURE 1**) show multiple calcified cystic lesions in the upper abdomen. He has no fever or abdominal pain.

**Q:** Which is the most plausible diagnosis?

- ☐ Nephrolithiasis
- ☐ Hydatid cyst
- ☐ Polycystic kidney and liver disease
- ☐ Metastatic calcification
- ☐ Intra-abdominal abscesses
- ☐ Cystadenoma

**A:** This patient has polycystic kidney disease. He first came to our hospital 21 years ago because of upper gastrointestinal bleeding, and he was found to have multiple cystic lesions. He was diagnosed as having polycystic kidney disease with multiple hepatic cysts.

About 15 years ago, he had several episodes of gross hematuria with right flank pain, which were attributed to bleeding from the cysts. Because his renal function was deteriorating, he started regular hemodialysis at that time. He underwent parathyroidectomy for secondary hyperparathyroidism 2 years ago.

The differential diagnosis of calcified cystic

doi:10.3949/ccjm.77a.09050

lesions in the upper abdomen includes infectious diseases (eg, chronic intra-abdominal abscess, echinococcosis, cysticercosis), neoplasms (eg, cystadenomas, cystadenocarcinomas), organized hematomas, liver cysts, renal cysts, gallstones, renal stones, calcified lymph nodes, and vessel calcification.

Autosomal dominant polycystic kidney disease is the most common inherited renal disease.<sup>1</sup> Typically, patients with this disease have a positive family history, although about 5% to 10% do not.<sup>1,3</sup> (Our patient did not.)

The diagnosis is suggested by family history and imaging, with typical findings including large kidneys and extensive cysts scattered throughout both kidneys.<sup>1-3</sup> The history, epidemiologic data, and the character of the cystic lesions help in making the final diagnosis.

In patients at risk, the presence of at least two renal cysts (unilateral or bilateral) at age 15 to 30, of at least two cysts in each kidney at age 30 to 59, and of at least four cysts in each kidney at age 60 or older is regarded as sufficient to establish the diagnosis.<sup>1-3</sup>

Approximately 80% of patients with autosomal dominant polycystic kidney disease also have hepatic cysts.<sup>1,3</sup> Cyst calcifications occur in about 25% of patients, either as a residual effect of intracystic hemorrhage or as a consequence of secondary hyperparathyroidism.<sup>4,5</sup> ■

## REFERENCES

1. Braun WE. Autosomal dominant polycystic kidney disease: emerging concepts of pathogenesis and new treatments. *Cleve Clin J Med* 2009; 76:97-104.
2. Torres VE, Bennett WM. Diagnosis of and screening for autosomal dominant polycystic kidney disease. In: Rose BD, editor: *UpToDate*. Waltham, MA: UpToDate, 2009.
3. Grantham JJ. Clinical practice. Autosomal dominant polycystic kidney disease. *N Engl J Med* 2008; 359:1477-1485.
4. Coffin B, Hadengue A, Degos F, Benhamou JP. Calcified hepatic and renal cysts in adult dominant polycystic kidney disease. *Dig Dis Sci* 1990; 35:1172-1175.
5. Levine E, Grantham JJ. Calcified renal stones and cyst calcifications in autosomal dominant polycystic kidney disease: clinical and CT study in 84 patients. *AJR Am J Roentgenol* 1992; 159:77-81.

**ADDRESS:** Hung-Chun Chen, MD, PhD, Department of Internal Medicine, Kaohsiung Medical University Hospital, Kaohsiung Medical University, No.100, Tzyou 1st Road, Kaohsiung 807, Taiwan; e-mail [chenhc@kmu.edu.tw](mailto:chenhc@kmu.edu.tw).