

## THE CLINICAL PICTURE

**SALVADOR ARIAS-SANTIAGO, MD**

Department of Dermatology, San Cecilio University Hospital, Granada, Spain

**JOSÉ ANEIROS-FERNÁNDEZ, MD**

Department of Pathology, San Cecilio University Hospital, Granada, Spain

**HUSEIN HUSEIN-ELAHMED, MD**

Department of Dermatology, San Cecilio University Hospital, Granada, Spain

**MARÍA SIERRA GIRÓN-PRieto, MD**

Department of Dermatology, San Cecilio University Hospital, Granada, Spain

**LEOPOLDO MUÑOZ-MEDINA, PhD**

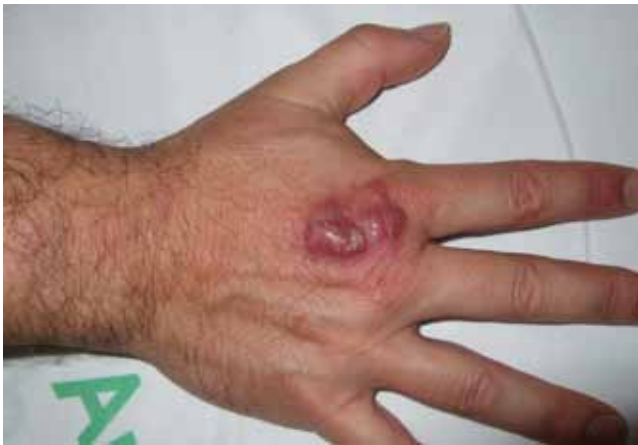Department of Internal Medicine, San Cecilio University Hospital, Granada, Spain

**RAMÓN NARANJO-SINTES, PhD**

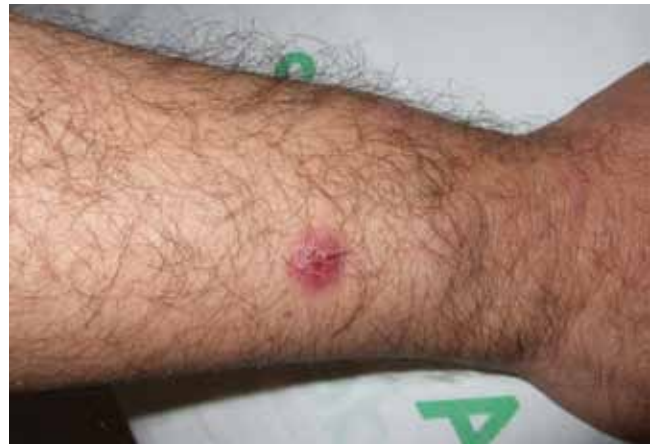Department of Dermatology, San Cecilio University Hospital, Granada, Spain

# The Clinical Picture

## Painful red nodule on the right hand



**FIGURE 1.** A red nodule with central ulceration on the right hand.

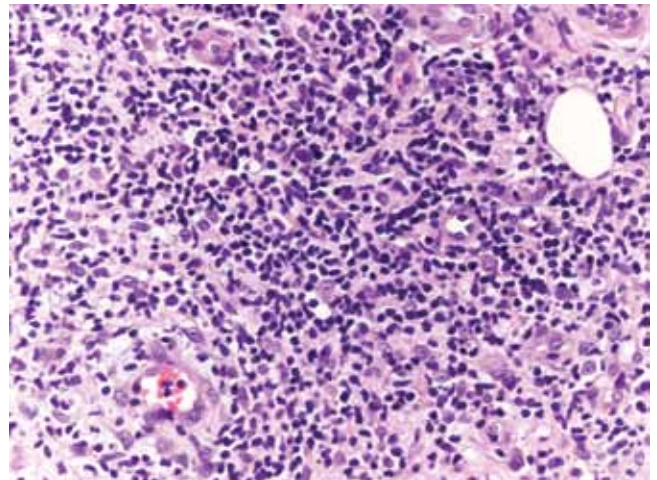


**FIGURE 2.** A nodule on the patient's forearm with a sporotrichoid distribution. Locoregional lymph nodes were not palpable.

**A** 46-YEAR-OLD HEALTHY MAN presents with a 15-day history of a tender subcutaneous nodule on the dorsum of the right hand that appeared after cleaning his aquarium. He has no fever or systemic symptoms. For 2 weeks he has been taking amoxicillin-clavulanate (Augmentin) and metronidazole (Flagyl), but without an adequate response.

On physical examination, the nodule is painful and has central ulceration (**FIGURE 1**). Another two nodules are noted on the forearm, with a sporotrichoid distribution (**FIGURE 2**). Locoregional lymph nodes are not palpable.

Laboratory testing (hemography, biochemistry panel, coagulation test, and C-reactive protein) are normal. Routine bacterial cultures of blood and wound drainage are repeatedly negative. Histologic study (**FIGURE 3**) reveals signs of acute and chronic inflammation (a mixed infiltrate with lymphocytes, neutrophils, and histiocytes) with abundant bacilli by Ziehl-Neelsen and Giemsa stains.



**FIGURE 3.** Histologic testing revealed a mixed infiltrate with lymphocytes, neutrophils, and histiocytes (hematoxylin-eosin,  $\times 40$ ).

**Q:** Which is the most likely diagnosis?

- Tuberculosis verrucosa cutis
- Sporotrichosis
- Nontuberculous mycobacterial infection
- Leishmaniasis
- Nocardiosis

**A:** The correct answer is nontuberculous mycobacterial infection. *Mycobacterium marinum* was subsequently isolated from culture (Löwenstein-Jensen medium) of wound drainage.

Tuberculosis verrucosa cutis is an indolent, warty plaque that occurs after direct inoculation of *M tuberculosis* into the skin of someone previously infected with *M tuberculosis*. It can result from accidental exposure to tuberculous tissue in high-risk groups such as laboratory workers, physicians, and pathologists.

*Sporothrix schenckii* is the dimorphic fungus that causes sporotrichosis. Activities associated with acquisition of sporotrichosis include gardening (rose-gardener's disease), landscaping, farming, berry-picking, horticulture, and carpentry. The characteristic infection involves suppurating subcutaneous nodules that progress proximally along lymphatic channels (lymphocutaneous sporotrichosis).

Leishmaniasis is a disease caused by the protozoa of the *Leishmania* species, which is transmitted by the bite of a female sandfly. Initially, the lesion is a small, red papule up to 2 cm in diameter. Over several weeks, the papule becomes darker, develops a crust in the center, and eventually ulcerates to present a typical appearance of an ulcer with raised edges and surrounding dusky red skin.

*Nocardia* is a genus of filamentous gram-positive bacteria that stains acid-fast, just as *M marinum* does. *Nocardia asteroides* primarily affects the lungs and can disseminate systemically. However, *Nocardia brasiliensis* is often associated with sporotrichoid-spreading subcutaneous nodules.

**■ CLINICAL PRESENTATION AND DIAGNOSIS**

*M marinum* is a genus of nontuberculous mycobacteria that usually causes disease in fish but can cause human skin infection by penetrating through a break in the skin. It can spread to deeper structures, resulting in tenosynovitis, arthritis, or osteomyelitis.<sup>1</sup> The disease caused by

*M marinum* is sometimes called “swimming pool granuloma” or “fish-tank granuloma.”<sup>2</sup>

In this case, the patient probably acquired the infection while cleaning his home aquarium,<sup>3</sup> so asking about contact with pet fish is very important for the clinical diagnosis.

Lesions are usually localized to the site of the inoculation, with a predilection for areas predisposed to trauma, such as the hands and the fingers, after an incubation period of 2 to 8 weeks. Lesions are self-limited and usually appear as pruriginous bluish-red papules or pustules that may increase in size to form a verrucous or violaceous plaque or nodule. Superficial lesions often undergo central ulceration. Disseminated infection is rare and occurs mainly in patients who are immunocompromised because of renal transplant, systemic lupus erythematosus, chronic steroid therapy, or anti-tumor necrosis factor alpha therapy.<sup>4</sup> In such cases, infection can be life-threatening.

On histopathologic study, a nonspecific inflammation consisting of a mixed infiltrate with lymphocytes, neutrophils, and histiocytes is usually observed. Sometimes a granulomatous inflammatory infiltrate mimicking tuberculoid granuloma may be noted. *M marinum* is an aerobic, nonmotile acid-fast bacillus. It grows at 30°C to 32°C on Löwenstein-Jensen medium in 2 to 5 weeks, but cultures are rarely positive. Polymerase chain reaction and enzyme-linked immunosorbent assays can help identify the organism. Other diagnoses to be considered are leishmaniasis, tuberculosis verrucosa cutis, blastomycosis, histoplasmosis, and sporotrichosis.

**■ TREATMENT**

Treatment of *M marinum* infection is not based on any specific criteria. Spontaneous resolution in 24 to 36 months has been described.<sup>5</sup> Antibiotics are the first-line therapy, and sometimes surgical treatment may be necessary for deeper infection with necrotic tissue. Cryotherapy, electrode therapy, and irradiation have been reported to be effective.

Few studies have been conducted to determine the first-line antibiotic treatment for *M marinum* infection. In this case, treatment with sulfamethoxazole-trimethoprim<sup>6</sup> (Bactrim) resulted in resolution of the lesions in 6 months. Other antibiotics often used as monotherapy

**There are currently no specific treatment criteria for *M marinum* infection**

are tetracycline, minocycline (Minocin), and doxycycline (Vibramycin) 100 mg twice daily for 3 months.<sup>7</sup> However, treatment failure has been described with many antibiotics.

Multidrug therapy is usually prescribed to minimize the risk of resistance. A combination of clarithromycin (Biaxin), streptomycin, and ethionamide (Trecator) has been prescribed successfully.<sup>3</sup> Another combined regimen—clarithromycin 500 mg twice a day, rifampin (Rifadin) 600 mg daily, and ethambutol (Myambutol) 25 mg/kg daily—has been shown to be effective.<sup>5</sup> Also, rifampin 600 mg daily and ethambutol 15 to 25 mg/kg/day were effective in a patient with a sporotrichoid *M marinum* infection associated with infliximab (Remicade).<sup>8</sup> The duration of treatment ranged between 2 and 6 months, or up to 2 months after the disappearance of the cutaneous lesions.

Clinical awareness of *M marinum* infection is important so that the diagnosis can be made and appropriate therapy can be initiated promptly, because some cases with disseminated disease and serious complications have been described.<sup>9</sup> ■

## REFERENCES

1. Lam A, Toma W, Schlesinger N. *Mycobacterium marinum* arthritis mimicking rheumatoid arthritis. *J Rheumatol* 2006; 33:817–819.
2. Lewis FM, Marsh BJ, von Reyn CF. Fish tank exposure and cutaneous infections due to *Mycobacterium marinum*: tuberculin skin testing, treatment, and prevention. *Clin Infect Dis* 2003; 37:390–397.
3. Dodiuk-Gad R, Dyachenko P, Ziv M, et al. Nontuberculous mycobacterial infections of the skin: a retrospective study of 25 cases. *J Am Acad Dermatol* 2007; 57:413–420.
4. Streit M, Böhlen LM, Hunziker T, et al. Disseminated *Mycobacterium marinum* infection with extensive cutaneous eruption and bacteremia in an immunocompromised patient. *Eur J Dermatol* 2006; 16:79–83.
5. Jogi R, Tying SK. Therapy of nontuberculous mycobacterial infections. *Dermatol Ther* 2004; 17:491–498.
6. Alinovi A, Vecchini F, Bassissi P. Sporotrichoid mycobacterial infection. A case report. *Acta Derm Venereol* 1993; 73:146–147.
7. Mahaisavariya P, Chaiprasert A, Khemngern S, et al. Nontuberculous mycobacterial skin infections: clinical and bacteriological studies. *J Med Assoc Thai* 2003; 86:52–60.
8. Rallis E, Koumantaki-Mathioudaki E, Frangoulis E, Chatziolou E, Katsambas A. Severe sporotrichoid fish tank granuloma following infliximab therapy. *Am J Clin Dermatol* 2007; 8:385–388.
9. Imakado S, Kojima Y, Hiyoshi T, Morimoto S. Disseminated *Mycobacterium marinum* infection in a patient with diabetic nephropathy. *Diabetes Res Clin Pract* 2009; 83:e35–e36.

ADDRESS: Salvador Arias-Santiago, MD, San Cecilio University Hospital, Av Dr Olóriz 16, Granada 18012, Spain; e-mail [salvadorarias@hotmail.es](mailto:salvadorarias@hotmail.es).