

## THE CLINICAL PICTURE

**SUDIP KUMAR GHOSH, MD, DNB**

Assistant Professor, Department of Dermatology, Venereology, and Leprosy, R. G. Kar Medical College, Kolkata, India

**DEBABRATA BANDYOPADHYAY, MD**

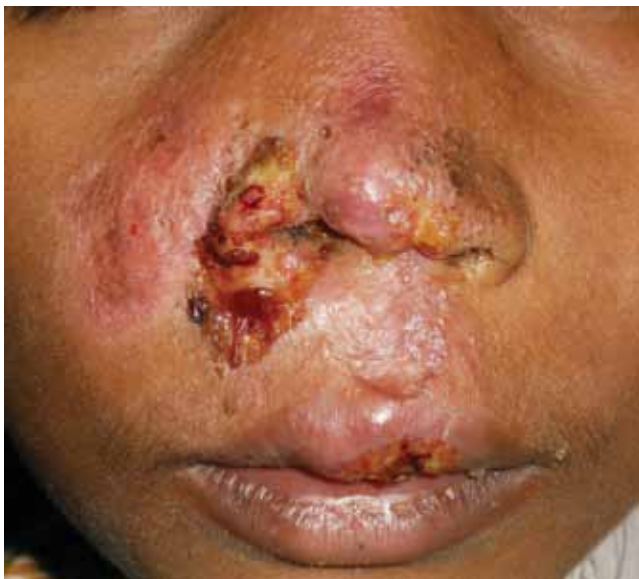Professor, Department of Dermatology, Venereology, and Leprosy, R. G. Kar Medical College, Kolkata, India

**LOKNATH GHOSHAL, MD**

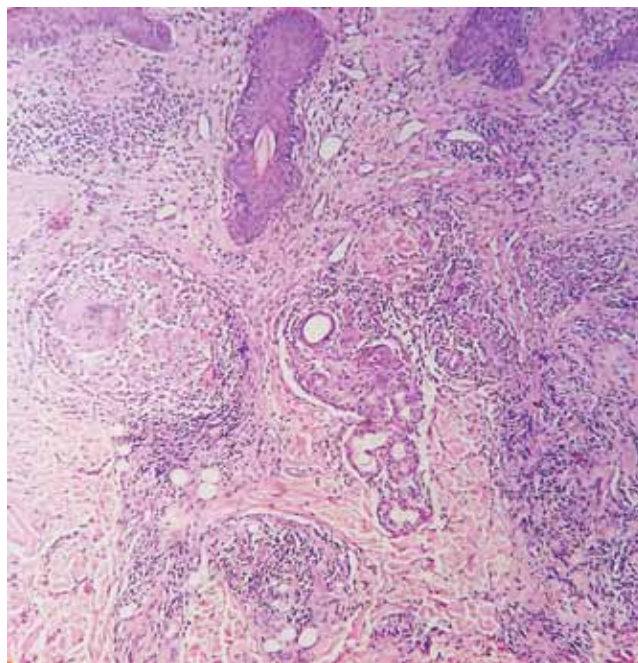
Resident Medical Officer-cum-Clinical Tutor, Department of Dermatology, Venereology, and Leprosy, R. G. Kar Medical College, Kolkata, India

# The Clinical Picture

## Facial swelling and ulceration with nasal destruction



**FIGURE 1.** Ulcerated plaque with destruction of the right nasal wing.



**FIGURE 2.** Epithelioid cell granuloma and giant cells (hematoxylin and eosin, x 100).

**A** 12-YEAR-OLD BOY presents with painless swelling and ulceration on and around his nose that has progressed gradually over the last 6 months. The lesion has increased in size despite treatment with topical neomycin and oral erythromycin. He has no systemic symptoms.

On examination (**FIGURE 1**), we note an indurated, nontender plaque with scarring at places on his right cheek, nose, and the vermilion border of the lip. In addition, there are two purulent ulcerations on the nose partly destroying the right nasal wing. The upper lip is also infiltrated, studded with a solitary ulceration. There is no regional lymphadenopathy. An examination of systems is normal.

doi:10.3949/ccjm.78a.10097

**Q:** What is the diagnosis?

- Lupus vulgaris (tuberculosis of the skin)
- Wegener granulomatosis
- Midline lethal granuloma (natural killer T-cell lymphoma)
- Hansen disease (leprosy)
- Lupoid form of cutaneous leishmaniasis

**A:** Lupus vulgaris is the correct diagnosis.

Cutaneous tuberculosis occurs in many forms, and lupus vulgaris is one of the most common.<sup>1</sup> Lupus vulgaris usually arises as a result of hematogenous spread from an endog-

enous source. It may also arise from exogenous inoculation or as a complication of vaccination with bacille Calmette-Guérin.<sup>2</sup>

Several morphologic variants have been described.<sup>1,2</sup> One form is characterized by plaques, often studded with psoriasiform scales. Large plaques may show irregular areas of scarring with islands of active lupus tissue and a thickened and hyperkeratotic margin. Ulcerative and mutilating variants of lupus vulgaris are characterized by scarring, ulceration, crusts over areas of necrosis, and destruction of the deep tissues and cartilage, resulting in deformities. The vegetative form produces marked infiltration, ulceration, and necrosis, with minimal scarring. Mucous membranes and cartilages are often destroyed. Tumor-like hypertrophic lesions and multiple papular and nodular lesions may also be seen. Nasal lesions may start as nodules, which may bleed and then ulcerate, sometimes resulting in cartilage destruction.

### CLINICAL FEATURES AND LABORATORY WORKUP CLINCHED THE DIAGNOSIS

A number of factors helped to confirm the diagnosis in this patient:

- A strongly positive Mantoux test (22-mm induration at 48 hours)
- Acid-fast bacilli on Ziehl-Neelsen staining of the smear taken from the purulent ulceration
- Isolation of *Mycobacterium tuberculosis* from the purulent exudates via culture in Lowenstein-Jensen medium
- A suggestive histopathologic picture (FIGURE 2)

### REFERENCES

1. Freitag DS, Chin R. Facial granulomas with nasal destruction. *Chest* 1988; 93:422–423.
2. Yates VM. Mycobacterial infections. In: Burns T, Breathnach S, Cox N, Griffiths C, editors. *Rook's Textbook of Dermatology*, Volume 2. 8th ed. Oxford: Wiley-Blackwell; 2010:31.1-31.41.
3. Takwale A, Berth-Jones J. Tuberculosis and tuberculids.

- The features on presentation
- A significant clinical improvement within 2 months of starting antituberculosis therapy.

### DIFFERENTIAL DIAGNOSIS

The differential diagnosis includes all the conditions in the question above. However, the absence of respiratory and renal involvement helps rule out Wegener granulomatosis; the absence of impaired sensation and nerve thickening helps rule out Hansen disease; and the absence of a nasal septal defect helps rule out Wegener granulomatosis, midline lethal granuloma, and Hansen disease.

On the other hand, the lupoid form of cutaneous leishmaniasis usually presents as an erythematous, infiltrated plaque that often closely resembles lupus vulgaris, but these lesions are usually less destructive than lupus vulgaris. However, the laboratory workup including the microbiological and histopathologic examination clearly excluded the other potential diagnoses in this patient.

### TREATMENT

Lupus vulgaris is treated with standard antituberculosis therapy.<sup>3</sup> The first phase of a four-drug regimen is given for 2 months—isoniazid, rifampin (Rifadin), pyrazinamide, and ethambutol (Myambutol). The second phase consists of isoniazid and rifampin for 4 months.<sup>3</sup>

Early recognition and confirmation of the diagnosis followed by treatment are of immense importance for preventing permanent disfigurement. ■

In: Lebowitz MG, Berth-Jones J, Heymann WR, Coulson I, editors. *Treatment of Skin Disease: Comprehensive Therapeutic*. 3rd ed. Philadelphia: Saunders-Elsevier; 2010:758–759.

ADDRESS: Sudip Kumar Ghosh, MD, DNB, Department of Dermatology, Venereology, and Leprosy, R. G. Kar Medical College, 1, Khudiram Bose Sarani, 700004 Kolkata, India; e-mail dr\_skgghosh@yahoo.co.in.

**Lupus vulgaris is treated with standard antituberculosis therapy**