

History of vasculitis: The life and work of Adolf Kussmaul

ERIC L. MATTESON, MD, MPH

Consultant, Divisions of Rheumatology and Epidemiology, Professor of Medicine, Mayo Clinic College of Medicine, Chair, Division of Rheumatology, Mayo Clinic, Rochester, MN

ABSTRACT

Adolf Kussmaul is well known for his contributions to the science of medicine and the specialty of rheumatology. A much-loved teacher and respected physician and researcher, Kussmaul's desire to understand disease, his careful clinical observations, and his innovative thinking in medical technology mark him as a pioneer in modern rheumatology.

Adolf Kussmaul, who lived and practiced medicine in the 19th century, is known for his clinical skills, his scientific acumen, his gift for teaching, and his mastery of diverse areas of knowledge. He was a contemporary of such luminaries as pathologist Rudolf Virchow. In the rheumatology community, he is best known for describing the first case of polyarteritis nodosa (PAN).

FIRST CASE

In the first volume of the first edition of *German Archive for Clinical Medicine*, Kussmaul, along with his pathology associate Rudolf Maier, reported the case of Carl Seufarth, a 27-year-old tailor's journeyman. Seufarth arrived at the University of Freiburg internal medicine clinic on May 4, 1865, at 10 AM. Kussmaul was at that time head of medicine at Freiburg. Seufarth's journeyman's log recorded that he had been healthy when he left his hometown of Gernsbach in southwest Germany on January 30, 1865. His entry indicated that he was 5 feet 2 inches tall, was of strong build, and had healthy facial color.

Kussmaul's 1866 description of Seufarth upon his arrival at the clinic is among the most memorable passages in medical literature:

"The patient was one of those patients for whom one can already give the prognosis before the diagnosis; the first impression was one of a lost soul whose few remaining days are numbered."

Despite his frail appearance, Seufarth was able to walk into the hospital and climb the two flights of stairs to the internal medicine clinic without assistance. He had had a cold followed by a productive cough in the autumn of 1864, but felt well afterward. In the 8

days prior to admission to the University of Freiburg, he developed diarrhea and frequent chills with fevers and sweats. He had felt unwell for the preceding 2 to 3 weeks, during which he was hospitalized briefly for scabies, wandered from one place to another, and eventually arrived in Freiburg. Freiburg police imprisoned him on May 2 for begging and brought him to the internal medicine department on May 4 because of weakness.

Over the next several days, Seufarth experienced rapidly developing weakness, numbness in the left hand and eventually other extremities, and paralysis of the arm and hand muscles. He was closely monitored at the clinic with his temperature recorded every morning and evening. On the 28th day of hospitalization, pea-sized nodules were discovered in the subcutaneous skin of the abdomen and chest. By June 2, the patient was in a state of extreme weakness. He died on June 3, 1865, at 2 AM.

Upon autopsy, Maier effected a sketch of Seufarth's heart (**Figure 1**). The aneurysmal dilatations and narrowings in the coronary arteries that are characteristic of PAN are easily recognized. In the autopsy report, Maier described the condition of the heart as:

"A peculiar mostly nodular thickening (periarteritis nodosa) of countless arteries and below the caliber of the liver artery and the major branches of the coronary arteries of the heart . . ."

This description is what we understand today as typical of vascular involvement in PAN. Maier also examined the tissue microscopically. In his report, he described the aneurysmal dilatations, narrowings, and inflammation occurring at the branches of the arteries. His sketch of involved organs depicted neutrophilic infiltration into the walls of the vessels.

When consulted by Kussmaul for a second opinion, pathologist Rudolf Virchow said he had not observed patients with disease similar to that of Seufarth. In his archives, however, he later found a specimen of an aneurysm in a branch of the superior mesenteric artery.

Kussmaul and Maier published the case under the title "On a previously undescribed peculiar arterial disease (periarteritis nodosa) accompanied by Bright's disease and rapidly progressive general muscle weakness." "Periarteritis nodosa" was later termed "polyarteritis nodosa" to better describe the inflammation of multiple medium-

Dr. Matteson reported that he has no financial interests or relationships that pose a potential conflict of interest with this article.

This article was developed from an audio transcript of Dr. Matteson's presentation at the "New Directions in Small Vessel Vasculitis: ANCA, Target Organs, Treatment, and Beyond" symposium held at Cleveland Clinic on May 4, 2011.

The transcript was formatted and edited by Cleveland Clinic Journal of Medicine staff for clarity and conciseness, and was then reviewed, revised, and approved by Dr. Matteson.

doi:10.3949/ccjm.79.s3.12

and small-vessel arteries rather than inflammation around the arteries as Maier had initially envisioned it.

■ BIOGRAPHICAL NOTES

The son of a German army surgeon, Kussmaul was born in 1822 in Graben near Karlsruhe, a small town in the Black Forest of southwestern Germany. Kussmaul began his medical studies at the University of Heidelberg in 1840. That same year, he constructed the first ophthalmoscope. The device did not function as intended because he had not discovered the light orientation needed to prevent the iris from contracting. But, as he later said, “It was the best ophthalmoscope of the time. Its only drawback was that it did not work.”

After graduating from the University of Heidelberg, Kussmaul went into private practice in Wiesloch. He returned to the University a year later, after having developed pericarditis, where he served as an assistant in 1846 and 1847 and engaged not only in medicine and medical discovery, but also poetry, publishing, and social movements. He founded a magazine that published short stories, poetry, and spoofs on the government; and he coined the term “Biedermeier,” which refers to a furniture style as well as a German social movement.

With plans to further his medical education, Kussmaul and his friend, Edward Bronner, traveled to Vienna and Prague in 1847 and 1848. In Vienna, they met the anatomic pathologist Karl Rokitansky. Although the young men hoped to study with the renowned scientist, they were soon dissuaded by Rokitansky’s clear dislike of working with students. He also had little use for patients, holding that the best patient was a dead patient because of all that one could learn by doing an autopsy.

Kussmaul and Bronner returned to Germany, Kussmaul having been called to serve as a physician in the Baden battalion during the German-Danish war. There, he contributed significantly to the health of the army by insisting that wounded soldiers not be bled—a common treatment at that time that actually accelerated the deaths of many soldiers in the field.

■ ACADEMICIAN, SCIENTIST, AND CLINICIAN

Shortly after his 1850 marriage to Luise Amanda Wolf, the daughter of a famous surgeon, Kussmaul developed an ascending polyradiculopathy, which at one time was called Landry-Kussmaul paralysis and later Guillain-Barré syndrome. This condition, along with his previous history of pericarditis, stimulated Kussmaul’s pursuit of medical knowledge for better understanding of his own afflictions as well as medicine in general.

He completed his doctoral dissertation at the University of Würzburg in 1853. There, he worked with pathology professor Virchow, who is known as the father of the theory of coagulation and the cellular theory of disease. It is perhaps less well known that in a treatise on

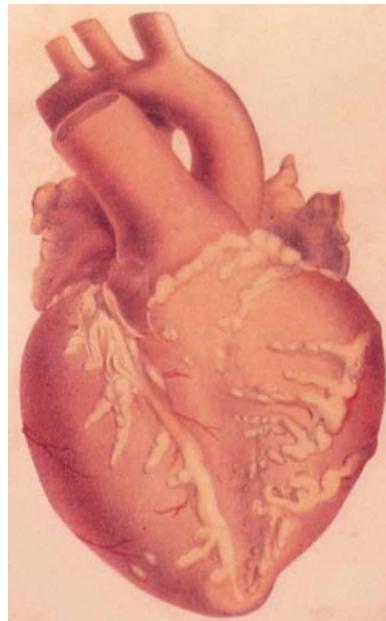


FIGURE 1. A drawing from Kussmaul and Maier’s account shows aneurysmal dilatations and narrowings in the coronary arteries of Carl Seufarth, the first patient reported to have polyarteritis nodosa.

Source: Kussmaul A, Maier R. Über eine bisher nicht beschriebene, eigentümliche Arterienkrankung (Periarteritis nodosa), die mit Morbus Brightii und rapid fortschreitender allgemeiner Muskellähmung einhergeht. *Deutsches Arch klin Med* 1866; 1:484–518.

histopathology in 1847, Virchow proposed that vasculitis actually might occur in blood vessels and originate in the adventitia. This profound insight was lost at the time because of inadequate understanding of vasculitic disorders.

Returning to the University of Heidelberg in 1854, Kussmaul earned the rank of assistant professor of medicine and, by 1857, professor of medicine. Two years later, he relocated to the University of Erlangen as a professor of medicine. His inaugural lecture at the University of Erlangen was the presentation of two cases of Landry-Kussmaul paralysis. Kussmaul’s research at Erlangen focused on differentiating the symptoms of mercurialism from syphilis (mercury was used for the treatment of syphilis).

Kussmaul was then called to the University of Freiburg in 1863 as head of the department of medicine. Among Kussmaul’s achievements at the University of Freiburg in the 1860s were the description of paradoxical pulse in obstructive pericarditis that we know as the Kussmaul pulse, and the description of the breathing characteristic of diabetic acidotic coma that we know as Kussmaul respiration. There he also performed the first gastroscopy on a sword-swallowing circus performer using a derivation of a laryngoscope; unfortunately, again his invention was thwarted by lack of an adequate light source. He also studied peptic ulcer disease and described a technique for dilating a stenosed peptic ulcer lesion with a balloon device. He later worked with Czerny and Billroth to develop the surgical procedure used routinely for nearly

HISTORICAL PERSPECTIVE

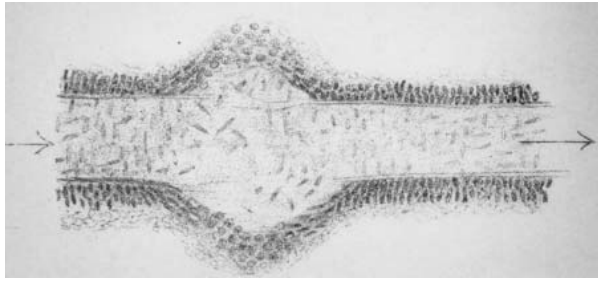


FIGURE 2. Sketch by Karl Rokitansky's student, Hans Eppinger, depicting his microscopic examination of mesenteric artery aneurysm. Eppinger discovered that the aneurysms were the result of dilatation of the entire arterial wall.

Source: Eppinger H. Pathogenesis (Histogenesis und Aethiologie) der Aneurysmen einschliesslich des aneurysma equi verminosum. Arch Klin Chir 1887; 35:1–563.

100 years to relieve peptic ulcer disease prior to the introduction of drugs such as ranitidine.

■ RHEUMATOLOGY “WORMS”

Kussmaul and Maier initially published the Seufarth case in abstract form and called it “human worm aneurysm,” because they thought that the vascular pea-shaped or pea-sized structures represented worm and nematode infiltration. When they examined the specimens microscopically, however, they realized that they were viewing an inflammatory disease process.

Ironically, vessel disease of the PAN type was described in 1852 by Rokitansky. Rokitansky reported finding mesenteric aneurysms in the branch points of the arteries; however, because he eschewed technology, he did not examine the specimen microscopically and

failed to recognize the inflammatory process. His student, Hans Eppinger, revisited the specimen some 30 years later and, under microscopic examination, clearly defined the aneurysmal dilatations and inflammatory infiltrates (**Figure 2**).

A final rheumatology worm episode occurred late in Kussmaul's career in Strasburg, where he had become head of the department of medicine in 1878. Kussmaul asked his assistant and biographer, Albert Kahn, to administer naphthalene to a patient to eradicate intestinal worms. Strangely, the worms survived, but the fever resolved. Due to a pharmacy error, acetanilide, an anti-inflammatory marketed by Bayer, had been dispensed rather than naphthalene. Bayer subsequently marketed the product as Antifebrin.

■ REMEMBERED AND COMMEMORATED

Kussmaul was a much-loved teacher and a well-respected physician. After he retired in 1888, he returned to Heidelberg as emeritus professor of medicine. He died in 1902 at age 80. His desire to understand disease, his clinical observations, his teaching abilities, and his ability to apply medical technology to the bedside all played roles in his contributions to clinical medicine. One of several Kussmaul commemoration sites is a lunette in Lenox Hill Hospital, New York, New York, where his portrait plaque is displayed alongside those of Ismar Boas and Carl Anton Ewald, the founders of modern gastroenterology.

Correspondence: Eric L. Matteson, MD, MPH, Division of Rheumatology, Mayo Clinic, 200 First Street SW, Rochester, MN 55905; matteson.eric@mayo.edu