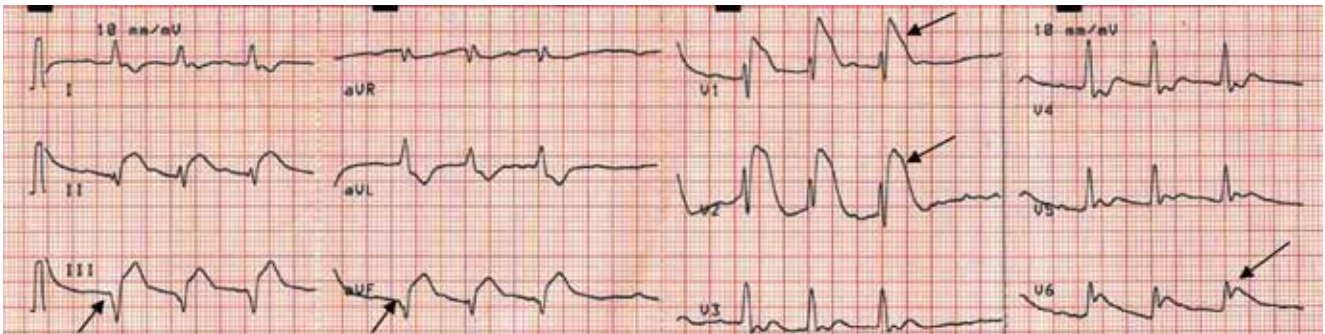


**HESHAM R. OMAR, MD**  
Internal Medicine Department,  
Mercy Hospital and Medical Center,  
Chicago, IL

# The Clinical Picture

## Chest pain followed by sudden collapse



**FIGURE 1.** Electrocardiography at presentation shows ST segment elevation in the inferior leads (II, III, and aVF) and in leads V<sub>1</sub>, V<sub>2</sub>, and V<sub>6</sub>, and Q waves in leads III and aVF.

**Right-  
chest-lead  
electro-  
cardiography  
confirmed  
right  
ventricular  
injury**

ONE MORNING, while at work as an intensive care unit nurse, a 51-year-old man—a heavy smoker with diabetes and hypertension but no previous symptoms of heart disease—experienced a sudden onset of chest pain and profuse sweating. A few minutes later, witnesses saw him collapse, with an initial rhythm of ventricular fibrillation on the portable monitor, for which he underwent defibrillation. Cardiopulmonary resuscitation was started and was continued for 20 minutes; spontaneous circulation was restored, and the patient regained full consciousness. His blood pressure was 90/60 mm Hg in both arms. Arterial blood gas testing revealed normal oxygenation, and electrocardiography was performed (**FIGURE 1**).

**Q:** Given what we know so far, what is the most likely cause of the ST segment elevation in leads V<sub>1</sub> and V<sub>2</sub>?

- ☐ Brugada syndrome
- ☐ Pulmonary embolism
- ☐ Right ventricular injury
- ☐ Anterior myocardial infarction

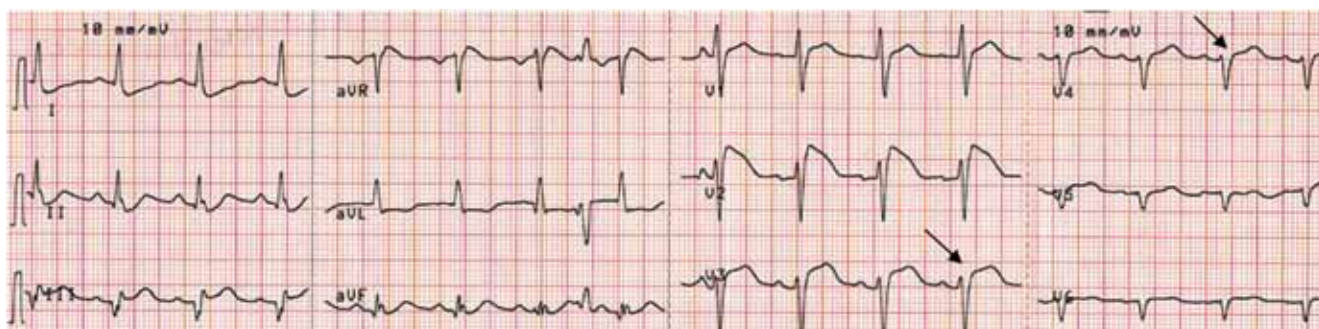
doi:10.3949/ccjm.78a.10050

**A:** The correct answer is right ventricular injury (discussed below).

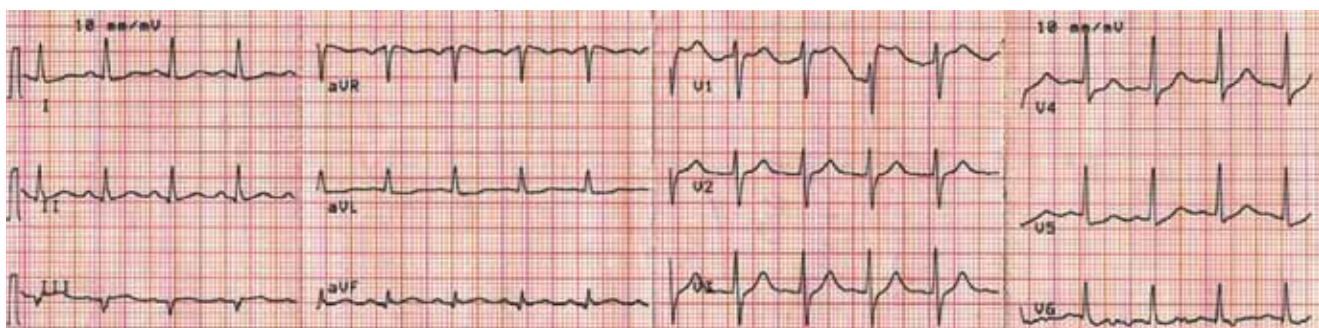
**Brugada syndrome** is a genetic disorder caused by a mutation in the cardiac sodium channel gene. It is characterized by a pronounced elevation of the J point, a coved-type ST segment elevation in leads V<sub>1</sub> and V<sub>2</sub>, and a propensity to develop malignant ventricular arrhythmias and sudden cardiac death.

In this patient, the pattern of ST segment elevation in leads V<sub>1</sub> and V<sub>2</sub> may be falsely interpreted as the classic type 1 Brugada electrocardiographic pattern. However, the classic type 1 Brugada electrocardiogram is characterized by a coved ST elevation followed by a negative T wave.<sup>1</sup> The absence of T-wave inversion following ST segment elevation in this patient excluded Brugada syndrome. Moreover, the main presentation in patients with Brugada syndrome is either syncope or sudden cardiac death.

**Pulmonary embolism** can present with various electrocardiographic patterns. ST segment elevation in the antroseptal leads is an extremely rare sign and has been demonstrat-



**FIGURE 2.** Right-chest-lead electrocardiography shows ST segment elevation in leads  $V_3R$  and  $V_4R$ , (arrows), confirming right ventricular injury.



**FIGURE 3.** Electrocardiography after thrombolytic therapy shows resolution of ST segment elevation in leads  $V_1$  and  $V_2$ . There are no Q waves in the anterior leads.

ed in a few reports.<sup>2,3</sup> Pulmonary embolism can also present with abnormal Q waves in leads III and aVF but not in lead II.<sup>4</sup> The initial electrocardiographic rhythm in patients who present with cardiac arrest is usually pulseless electrical activity; however, the combination of increased right ventricular oxygen consumption due to increased right ventricular afterload and right ventricular hypoperfusion due to hypotension can lead to right ventricular ischemia and subsequent arrhythmias. Mittal and Arora<sup>5</sup> described a case of submassive pulmonary embolism with right ventricular infarction presenting with sustained ventricular tachycardia.

The prognosis is usually poor in patients with cardiac arrest due to pulmonary embolism, which is usually caused by a massive embolus and usually necessitates thrombolytic therapy.

In the patient described here, pulmonary embolism was part of the differential diagnosis, given the presence of ST segment elevation in leads  $V_1$  and  $V_2$  in the context of the clinical scenario. However, the restoration of

spontaneous circulation without any specific treatment for pulmonary embolism and the normal oxygenation after cardiac arrest excluded pulmonary embolism.

**Right ventricular myocardial injury** is important to recognize for therapeutic and prognostic reasons. It is usually associated with inferior infarction because it is typically secondary to an acute occlusion of the proximal right coronary artery proximal to the take-off of the right ventricular marginal branch. In the described scenario, the presence of ST segment elevation and Q waves in the inferior leads together with reciprocal ST segment depression in leads I and aVL represents an inferior myocardial infarct. ST segment elevation in the right precordial leads  $V_3R$  and  $V_4R$  is a marker for right ventricular injury—especially in  $V_4R$ , in which it is a powerful predictor of right ventricular involvement. ST segment elevation in leads  $V_1$  and  $V_2$  is not usually demonstrated in patients with right ventricular injury because the electrical current of injury from the left ventricle inferior myocardial infarction dominates the right ventricular elec-

**In this patient, differentiating between right ventricular injury and anterior myocardial infarction is important to determine the culprit vessel**

trical forces, blocking the appearance of ST segment elevation in these leads.<sup>6</sup> Data from the Hirulog and Early Reperfusion or Occlusion-2 trial showed that ST segment elevation of 1 mm or greater in lead V<sub>1</sub> is associated with an increased risk of death in patients with acute inferior myocardial infarction.<sup>7</sup> Furthermore, the presence of ST-segment elevation in lead V<sub>6</sub> in patients with acute Q-wave inferior myocardial infarction, as evident in the first electrocardiogram, is associated with larger infarct size and a greater incidence of major arrhythmias.<sup>8</sup>

### ■ DETERMINING THE CULPRIT VESSEL

In the scenario described here, differentiating between right ventricular injury and anterior myocardial infarction is important to determine the culprit vessel.

In right ventricular injury, there is a reduction of amplitude of the ST segment elevation from leads V<sub>1</sub> to V<sub>5</sub>, but in patients with anterior myocardial infarction, the ST segment elevations are usually lowest in lead V<sub>1</sub> and increase toward lead V<sub>5</sub>. Another difference is the progressive regression of the ST segment

changes without the appearance of Q waves in right ventricular injury.<sup>6</sup> The presence of ST segment elevation in leads V<sub>1</sub> and V<sub>2</sub> in this patient therefore suggested right ventricular injury as the most likely diagnosis. Furthermore, two features suggested that the culprit vessel was the right coronary artery, not the circumflex artery: the ST segment elevation was greater in lead III than in lead II, and the ST segment depression was greater in lead aVL than in lead I.

### ■ CASE CONCLUDED

The right precordial leads revealed ST segment elevation in V<sub>3R</sub> and V<sub>4R</sub> (FIGURE 2). Streptokinase (Streptase) therapy was started, as the hospital was not equipped with a catheterization suite. Serial cardiac enzymes were elevated. Electrocardiography after thrombolytic therapy confirmed the resolution of ST segment elevation. However, the severity of the right ventricular failure resulted in cardiogenic shock and renal failure resistant to fluid infusion and inotropic and vasopressor support. The patient died 5 days after the episode of cardiac arrest. ■

### ■ REFERENCES

1. Antzelevitch C, Brugada P, Borggreffe M, et al. Brugada syndrome: report of the second consensus conference: endorsed by the Heart Rhythm Society and the European Heart Rhythm Association. *Circulation* 2005; 111:659–670.
2. Livaditis IG, Paraschos M, Dimopoulos K. Massive pulmonary embolism with ST elevation in leads V<sub>1</sub>–V<sub>3</sub> and successful thrombolysis with tenecteplase. *Heart* 2004; 90:e41.
3. Falterman TJ, Martinez JA, Daberkow D, Weiss LD. Pulmonary embolism with ST segment elevation in leads V<sub>1</sub> to V<sub>4</sub>: case report and review of the literature regarding electrocardiographic changes in acute pulmonary embolism. *J Emerg Med* 2001; 21:255–261.
4. Sreeram N, Cheriex EC, Smeets JL, Gorgels AP, Wellens HJ. Value of the 12-lead electrocardiogram at hospital admission in the diagnosis of pulmonary embolism. *Am J Cardiol* 1994; 73:298–303.
5. Mittal SR, Arora H. Pulmonary embolism with isolated right ventricular infarction. *Indian Heart J* 2001; 53:218–220.
6. Geft IL, Shah PK, Rodriguez L, et al. ST elevations in leads V<sub>1</sub> to V<sub>5</sub> may be caused by right coronary artery occlusion and acute right ventricular infarction. *Am J Cardiol* 1984; 53:991–996.
7. Wong CK, Gao W, Stewart RA, et al; Hirulog and Early Reperfusion or Occlusion-2 Investigators. Prognostic value of lead V<sub>1</sub> ST elevation during acute inferior myocardial infarction. *Circulation* 2010; 122:463–469.
8. Tsuka Y, Sugiura T, Hatada K, Abe Y, Takahashi N, Iwasaka T. Clinical characteristics of ST-segment elevation in lead V<sub>6</sub> in patients with Q-wave acute inferior wall myocardial infarction. *Coron Artery Dis* 1999; 10:465–469.

ADDRESS: Hesham R. Omar, MD, Internal Medicine Department, Mercy Hospital and Medical Center, 2525 South Michigan Avenue, Chicago, IL 60616; e-mail hesham\_omar2003@yahoo.com.