

THE CLINICAL PICTURE

FERNANDO JAÉN ÁGUILA, MD, PhD

Department of Internal Medicine, Virgen de las Nieves University Hospital, Granada, Spain

JOSÉ ANTONIO VARGAS-HITOS, MD, PhD

Department of Internal Medicine, Virgen de las Nieves University Hospital, Granada, Spain

DAVID ESTEVA FERNÁNDEZ, MD

Department of Internal Medicine, Virgen de las Nieves University Hospital, Granada, Spain

JUAN JIMÉNEZ ALONSO, MD, PhD

Department of Internal Medicine, Virgen de las Nieves University Hospital, Granada, Spain

The Clinical Picture

A farmer with chest pain and lung nodules

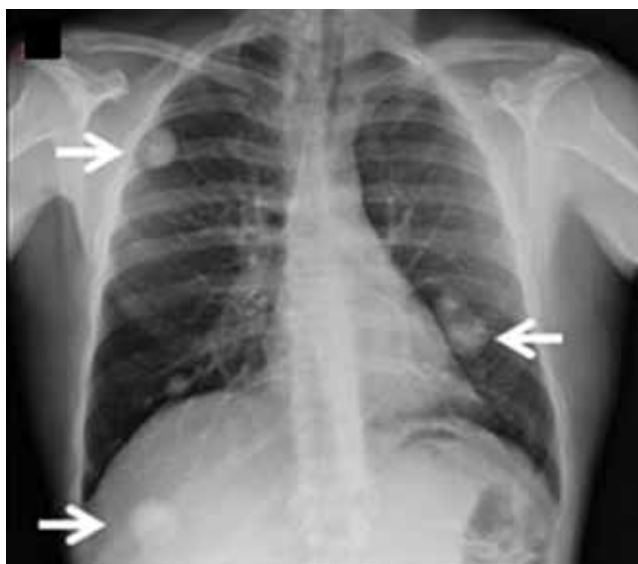


FIGURE 1

A 50-YEAR-OLD FARMER reports having bilateral pleuritic chest pain for the past week. He was treated 25 years ago for brucellosis, with neither clinical nor radiologic lung involvement. He is a 30-pack-year smoker. He lives in a rural area. He reports no other symptoms.

The physical examination is normal except for mild hepatomegaly. Laboratory tests (including transaminases) were normal, with the exception of the C-reactive protein level (7 mg/dL). Tumor markers, beta-2-microglobulin level, serologic tests for atypical bacteria and *Brucella* organisms, Mantoux test, protein electrophoresis, and tests for autoimmune antibodies were normal or negative. Echocardiography revealed no vegetations. However, chest radiography revealed multiple nodules

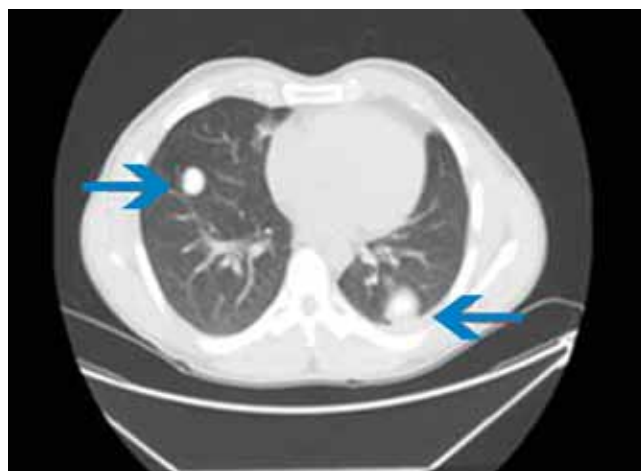

FIGURE 2

in both lungs (**FIGURE 1**, arrows). Thoracic computed tomography showed well-defined nodules 2 to 3 cm in diameter suggestive of calcified granuloma (**FIGURE 2**, arrows).

Q: Which is the most likely diagnosis?

- ☐ Pulmonary tuberculosis
- ☐ Metastatic lung disease
- ☐ Pulmonary brucellosis
- ☐ Septic pulmonary emboli
- ☐ Lymphoma

A: The most likely diagnosis is pulmonary brucellosis. The patient lives in a rural area where brucellosis is endemic, and his occupation has meant that he also has had decades of daily exposure to farm animals, mainly sheep.

Lung biopsy specimens were obtained by minimally invasive thoracoscopy (**FIGURE 3**), and histologic study revealed noncaseating

doi:10.3949/ccjm.79a.11077

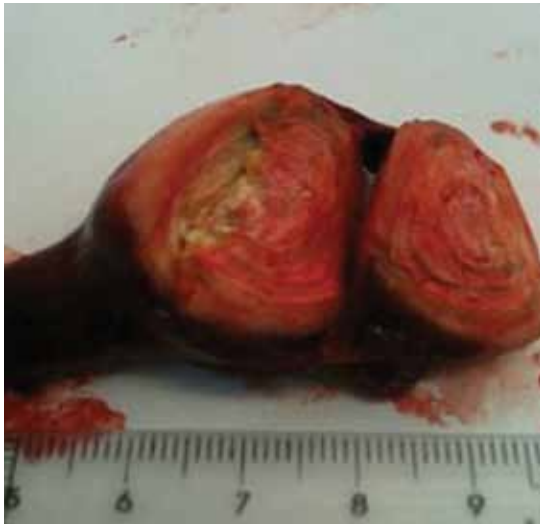

FIGURE 3

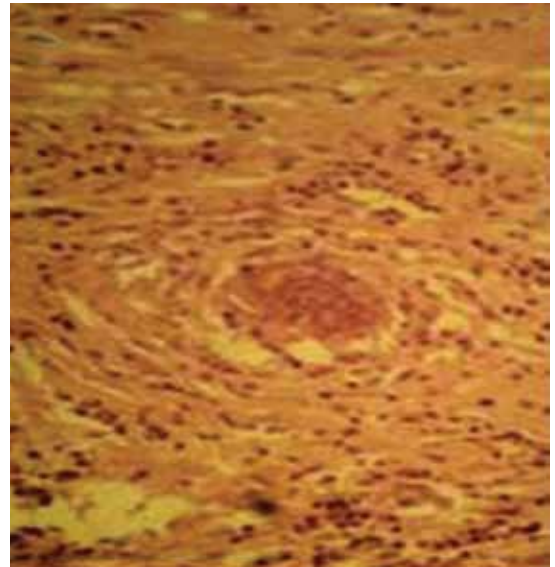


FIGURE 4

granulomas with central necrosis (FIGURE 4). Lastly, cultures of the resected nodule were positive for *Brucella melitensis*.

Once the diagnosis of pulmonary brucellosis was made, the following treatment regimen was started: rifampicin 600 mg daily for 2 months, doxycycline 100 mg twice daily for 2 months, and intramuscular gentamicin 240 mg daily for 2 weeks. The chest pain gradually improved and resolved completely by 1 month after treatment was started; the lung lesions disappeared 8 weeks later. The patient remains disease-free at 6 months.

■ TYPICAL FEATURES OF BRUCELLOSIS

Brucellosis is a zoonotic disease transmitted to humans not only by ingestion of infected dairy products, but also by direct contact with infected animals or by inhalation of contaminated aerosols. This latter physiopathologic mechanism of acquiring the disease seems to be the most probable when the lungs are involved,¹ and it is common in people such as our patient, whose occupation exposes them to *Brucella* species.

Although brucellosis can initially present with mild respiratory tract symptoms, true pulmonary involvement (characterized by a more aggressive and prolonged course) is very uncommon, with a reported incidence of 1% to 7%.^{1,2} Respiratory involvement in brucellosis may appear as part of a systemic illness,

as the presenting symptom of the disease, or even as a solitary abnormality on chest radiography.¹ Bronchopneumonia, interstitial pneumonia, empyema, pleural effusion, paratracheal lymphadenopathy, and lung nodules have all been reported.²

Reinfection or a late relapse?

In our patient, a question was whether the second episode of brucellosis was a reinfection or a late relapse of the disease. Reinfection seemed the most feasible explanation, supported by his continuous occupational exposure, the properly treated first episode (rifampicin 600 mg daily and doxycycline 100 mg twice daily, both for 45 days), the long symptom-free period, and the fact that most relapses have been reported to occur during the first 6 months after therapy.³ However, late reactivation of an asymptomatic chronic lung infection was also possible, given the ability of *Brucella* species to survive inside the phagocytic mononuclear cells; brucellosis reactivation has been reported even 28 years after the first episode.⁴

■ DIAGNOSTIC CHALLENGES

The diagnosis of brucellosis with laboratory testing is challenging. The organism is difficult to isolate in sputum culture (only one case has been described until now),⁵ and serologic tests can be falsely negative, although this is rare.^{6,7} In fact, serologic testing in patients with fo-

The diagnosis of brucellosis with laboratory testing is challenging

cal brucellosis may be falsely negative when the serum agglutination test is performed,^{4,7} as could have occurred in our patient. In several studies, pleural fluid culture has been shown as a good method to isolate *Brucella* organisms,⁸ but biopsy is often the only way to establish the diagnosis.⁶

Complications of lung involvement in brucellosis are seldom severe and, when they appear, usually respond to the same treatment as for uncomplicated brucellosis.²

The combination of respiratory symptoms, epidemiologic risk factors, an endemic setting, and a history of a previous episode all raise clinical suspicion of brucellosis. If clinical suspicion is high, negative results of sputum, serology, or pleural fluid cultures should never rule out the disease; biopsy of the respiratory region affected is warranted. ■

REFERENCES

1. Hatipoglu CA, Bilgin G, Tulek N, Kosar U. Pulmonary involvement in brucellosis. *J Infect* 2005; 51:116–119.
2. Pappas G, Bosilkovski M, Akritidis N, Mastora M, Krteva L, Tsianos E. Brucellosis and the respiratory system. *Clin Infect Dis* 2003; 37:e95–e99.
3. Ariza J, Corredoira J, Pallares R, et al. Characteristics of and risk factors for relapse of brucellosis in humans. *Clin Infect Dis* 1995; 20:1241–1249.
4. Ögredici Ö, Erb S, Langer I, et al. Brucellosis reactivation after 28 years. *Emerg Infect Dis* 2010; 16:2021–2022.
5. Gattas N, Loberant N, Rimón D. Miliary and reticulo-nodular pulmonary brucellosis. [in Hebrew]. *Harefuah* 1998; 135:357–359, 407.
6. Theegarten D, Albrecht S, Tötsch M, Teschler H, Neubauer H, Al Dahouk S. Brucellosis of the lung: case report and review of the literature. *Virchows Arch* 2008; 452:97–101.
7. Celik AD, Yulugkural Z, Kilincer C, Hamamcioglu MK, Kuloglu F, Akata F. Negative serology: could exclude the diagnosis of brucellosis? *Rheumatol Int* 2010; Epub ahead of print.
8. Kerem E, Diav O, Navon P, Branski D. Pleural fluid characteristics in pulmonary brucellosis. *Thorax* 1994; 49:89–90.

ADDRESS: José Antonio Vargas-Hitos, MD, PhD, Department of Internal Medicine, Virgen de las Nieves University Hospital, 9th Floor, Av. Fuerzas Armadas N° 2, 18014 Granada, Spain; e-mail joseantoniovh@hotmail.com.