

Deep brain stimulation for movement disorders: Patient selection and technical options

■ ABSTRACT

Deep brain stimulation (DBS) is used as a treatment for movement disorders. Unlike ablative procedures, DBS is reversible and adjustable. It is approved in the United States for treatment of Parkinson disease (PD), dystonia, and tremor. This surgical procedure is considered safe and effective for the management of the motor symptoms of these disorders, although it does not cure the underlying conditions. Potential complications of DBS surgery include intracranial hemorrhage, infections, and complications related to the hardware. There may also be complications related to stimulation or programming, although these are usually associated with dosages of dopaminergic medications and are reversible. DBS is usually performed under conscious sedation with awake evaluation during intraoperative physiologic testing. Typically, the procedure is performed with stereotactic image guidance, using computed tomography or magnetic resonance imaging (MRI) for targeting. Surgery can be accomplished with stereotactic frames or frameless systems. Recently, intraoperative MRI guidance has become available and is an alternative to the traditional surgical procedure, allowing for implantation of the DBS device under general anesthesia.

Implantation of a deep brain stimulator is the most common surgical procedure performed in the United States and industrialized world for the management of advanced movement disorders. These procedures are US Food and Drug Administration (FDA)-approved for the management of the symptoms of Parkinson disease (PD) and essential tremor. Deep

brain stimulation (DBS) is also approved for managing primary generalized dystonia and torticollis under a humanitarian device exemption.

Deep brain stimulation has largely replaced ablative procedures such as thalamotomy and pallidotomy. While ablative procedures can be effective for the symptoms of movement disorders, they cause a permanent lesion in the targeted nuclei and are therefore not reversible. DBS is considered safer because it can be adjusted over time and the location of the leads can be revised.¹ On the other hand, regular maintenance of implanted hardware may be considered a disadvantage of DBS.

■ HARDWARE AND TARGETS

While ablative procedures do not require implantable hardware, DBS consists of permanently implanted neurostimulation systems. The battery-powered pulse generators typically last for several years but require multiple replacements during a lifetime. In addition, if other hardware components fail, surgical revision may be required to maintain treatment efficacy. Surgery involving implantation of hardware carries a higher risk of infection than does a nonimplantation procedure. If infections occur, removal of the hardware is often required, with reimplantation performed after the infection clears. In addition, the expense of DBS hardware may limit availability in some cases.

Three components

Permanently implanted DBS devices have three components: the DBS lead, which is inserted into the brain and extends to the outside of the skull; the implantable pulse generator, typically located in the infraclavicular area; and an extension cable that connects the two components (**Figure 1**). Patients may have unilateral or bilateral lead implantation and unilateral or bilateral implantation of pulse generators. A single generator may be connected to both brain leads. Patients also have the option of receiving either a nonrechargeable or a rechargeable pulse generator. The advantage of the latter is longer intervals between battery replacement surgery (up to 9 years). However, these require more maintenance by the patient, who needs to periodically recharge the generators at home using a wireless charg-

Dr. Machado reported ownership interest in ATI Medical Equipment Corporation, Cardionomics, and Intellect Medical, Inc.; and consulting services for Monteris Medical. Dr. Deogaonkar reported intellectual property rights with Autonomic Technologies, Inc. and consulting for Medtronic, Inc. Dr. Cooper reported that he has no financial interests or relationships that pose a potential conflict of interest with this article.

This article is based on Dr. Machado's presentation at "The Annual Therapy Symposium on Movement Disorders for the Modern Clinician" held in Fort Lauderdale, Florida, on January 29, 2011, and was written by Drs. Machado, Deogaonkar, and Cooper.

doi:10.3949/ccjm.79.s2a.04

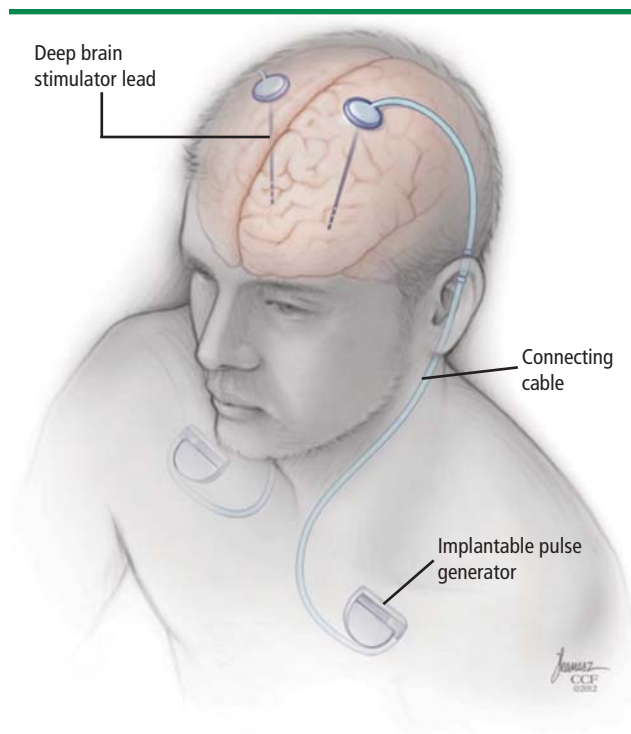


FIGURE 1. The components of an implantable deep brain stimulation system.

ing unit. The recharging procedure may be time consuming and difficult for patients who are challenged by new technologies. In our experience, most patients with PD and tremor prefer nonrechargeable pulse generators.

Target nuclei

Several nodes or nuclei can serve as targets for DBS. In patients with PD, the most common surgical target is the subthalamic nucleus (STN), either unilaterally or bilaterally.² The globus pallidus pars interna (GPi) is also a viable target and is preferred for some patients with PD. The most common target for managing essential tremor is the ventral intermediate nucleus (VIM) of the thalamus, which can also be the target of choice for patients with tremor-predominant PD. However, the GPi and STN are usually preferred over the VIM in patients with PD because stimulation of these targets can relieve symptoms other than tremor, such as rigidity and bradykinesia. Bilateral stimulation of the GPi is the most frequent approach in patients with generalized torsion dystonia and torticollis, although the STN and thalamic nuclei (off-label) are also considered options.

■ PATIENT SELECTION

Patients are evaluated in our center at Cleveland Clinic by a multidisciplinary team that includes a movement disorder neurologist, a subspecialized neurosurgeon, a

movement disorder neuropsychologist, and a psychiatrist with special interest in the behavioral comorbidities of movement disorders.³ Neuroimaging is included in this assessment. We have also included physical therapy as part of the initial evaluation in order to gain insight into the patient's limitations and develop rehabilitation strategies that may enhance the outcomes of surgery or provide alternatives should surgery not be indicated. This evaluation provides extensive data that are then reviewed by the team in a conference dedicated to discussing candidacy for DBS or options for managing the symptoms of advanced movement disorders. Behavioral and cognitive issues are assessed in detail and, in our experience, are the most common reasons for not recommending DBS.

An important part of the evaluation of patients with PD is a formal test with rating of the motor section of the Unified Parkinson's Disease Rating Scale (UPDRS) with the patient off medications for 8 to 12 hours and then after a test dose of levodopa. At our center, this off/on test is videotaped so that the responsiveness of individual symptoms to levodopa can be reviewed later in conference.

Risk of cognitive decline

While DBS is considered safe and effective, there is a risk of cognitive decline in some patients. In most patients, long-term stimulation-related cognitive decline may be detected with formal measures but is not clinically significant and is outweighed by the motor and quality-of-life benefits of surgery. In some patients, long-term cognitive decline can be significant and can limit function. Cognitive neuropsychologic testing provides valuable information in this regard. Patients with preserved cognitive function seldom experience significant decline with DBS while those with substantial baseline impairment are thought to be at greater risk. Patients who meet criteria for dementia are usually not considered candidates for DBS, but exceptions exist. Transient perioperative cognitive difficulties are more common than persistent deficits, and typically resolve within a few weeks (see "Complications of deep brain stimulation," page S22).

Benefits in Parkinson disease

Deep brain stimulation can address several symptoms of PD but with varying effects. Tremor, rigidity, and bradykinesia usually improve substantially. Gait has a more variable response, and balance is typically refractory. A general rule is that symptoms that improve with a single dose of levodopa should also improve with DBS. (Tremor, however, will most often respond to DBS even if refractory to medication.) Good candidates for surgery typically have a greater than 30% improvement in UPDRS motor score with levodopa challenge, but sometimes, improvement in the total score is less informative than evaluation

of the effects of levodopa on particular symptoms. Treatment effects can be compared with the patient's expectations for surgery in order to infer whether the goals for symptom improvement are realistic.

Treatment outcomes depend on etiology

After programming, DBS can provide **PD symptom control** similar to that of medication “on time,” but with fewer on-off fluctuations and less on-time dyskinesia. Good surgical candidates are patients who once responded well to dopaminergic medications but who, after several years with the disease, present with increased duration of “off time,” unpredictable duration of on time, and medication side effects such as on-time dyskinesia. Patients who do not respond well to levodopa even in subscores of the UPDRS may not be good candidates for DBS, and in some cases the diagnosis itself needs to be reviewed.

Deep brain stimulation can improve quality of life and alleviate symptoms of **essential tremor**. Tremor control is best for the upper extremities and tends to be better for distal tremors than for proximal ones. Patients who are good candidates for surgery often have severe tremors. A substantial improvement in these symptoms often has a dramatic, positive effect on work and quality of life. In some patients, surgery is considered for mild tremor if it seriously disrupts the patient's lifestyle or occupation and cannot be well controlled with medications. Often, in these cases, tremor that appears relatively mild to the examiner is significantly limiting for the patient.

Very severe and proximal tremor is more refractory, though it may also improve. The changes can be well documented with objective measures. In these cases, however, residual tremor can still be moderate to severe and can be functionally limiting. Head or vocal tremors are typically refractory. They may be improved with bilateral implantation, but this cannot be accurately predicted. Patients who present with head-only or head-predominant tremor are thought to be less likely to benefit than those with limb tremor. Nonetheless, tremors of the head can severely impair quality of life. Because there are few other treatment options, some patients choose DBS with the understanding that the outcome is uncertain and the benefit may be limited.

Tremor resulting from **multiple sclerosis** or other causes can be medically refractory and disabling. In our experience, DBS can be an off-label option for managing secondary tremors and good outcomes have been observed. However, outcomes are much less predictable and tremor control less effective than in patients with essential tremor.

Patients with **primary generalized dystonia** can be considered candidates for DBS and may experience improved symptom control and quality of life.⁴ Patients with the *DYT1* mutation are more likely to respond well

to DBS, as are those with other forms of primary generalized dystonia. In contrast to that seen in patients with PD and tremor, symptomatic improvement is frequently not observed during intraoperative testing. Several months of stimulation and programming may be required before significant improvements are detected.⁵ Surgery can also be considered for off-label use in the treatment of patients with **secondary dystonia**—such as that following injury or associated with cerebral palsy—but outcomes are less predictable and usually more limited. A possible exception may be seen in cases of **tardive dystonia**, for which there is increasing evidence⁶ for the effectiveness of DBS. This remains an off-label use of DBS.

Realistic expectations

An important aspect of the multidisciplinary evaluation includes a discussion of the expectations for surgery, the risks, and the requirements for postoperative care. As discussed above, DBS is reversible and adjustable, so outcomes depend not only on accurate implantation of the hardware but also on postoperative programming. Also, monitoring and maintenance of the implanted hardware are required in these patients. It is important that patients and families appreciate the fact that specialized, long-term postoperative follow-up is as much a part of the treatment as is the implantation itself.

■ UNILATERAL VERSUS BILATERAL DBS

Most patients with generalized dystonia undergo bilateral DBS. However, patients with PD or essential tremor may receive bilateral, staged, or unilateral implants. Some patients with PD present with either near-complete predominance of symptoms on one side or with symptoms that affect mostly the dominant extremity. In these patients, unilateral implantation is often recommended because it has less risk than the bilateral approach and may be sufficient to address the most limiting symptoms.

As the disease advances, an additional surgery may be required to accomplish bilateral symptom control. Nevertheless, we do not routinely recommend preventive implantation because it is not known whether second-side symptoms will become severe enough to require it. This strategy allows for deferring surgical risk, which is in itself advantageous. In our experience, bilateral implantation is often recommended to PD patients who present with symptoms such as freezing of gait.

Patients who have essential tremor often present with bilateral symptoms. Although many patients will indicate that they need symptom relief on both upper extremities in order to perform activities of daily living, our practice is to recommend surgery on one side at first and to suggest the patient consider contralateral implantation after weeks or months. Bilateral implantation may carry a risk for dysarthria and the risk is thought to be reduced

COMPLICATIONS OF DEEP BRAIN STIMULATION

Potential complications of deep brain stimulation (DBS) may be related to the surgery, the hardware, or stimulation.

Surgical complications

Surgical complications include intracranial and intracerebral hemorrhage, infection, misplacement of the DBS leads, or suboptimal placement of the leads. Intraoperative or postoperative hemorrhage is the most dreaded complication of DBS. While many smaller hemorrhages are asymptomatic or only transiently symptomatic, larger hemorrhages can be devastating. Hemorrhages may occur as the result of laceration to intracerebral vessels during microelectrode recording or lead implantation. In some cases, hemorrhages can be delayed and related to venous infarction or to clotting disorders. For treatment of Parkinson disease, either the globus pallidus pars interna (GPi) or the subthalamic nucleus (STN) can be targeted. Surgery on the GPi carries a greater hemorrhagic risk than does that on the STN. The risk of perioperative, cardiovascular, pulmonary, or other medical complications varies with age, comorbidities, and medical history.

Hardware complications

Hardware complications include migration of the leads, DBS lead failure or failure of any component of the system, and pain over the hardware. Battery failure can be addressed by replacing the generators prior to the estimated expiration.

Erosion of the subcutaneous portions of the hardware through the skin is also a concern and thought to be more common in patients with a very low body mass index. Erosion can happen at any time after implantation. Infection requires complete or partial removal of the DBS system.

Stimulation-related complications

All patients will experience some stimulation-related side effects during DBS programming. Stimulation signals with amplitudes greater than those required to achieve symptom control will affect neighboring structures—such as the internal capsule—and cause unintended effects. One of the goals of programming is to identify these thresholds and to set stimulation at amplitudes that do not cause intolerable side effects. Stimulation-related adverse effects are reversible with amplitude adjustments. Dyskinesia, worsening of axial symptoms (freezing, balance, and gait disturbance), speech disturbance, involuntary muscle contractions, paresthesia, and diplopia are among the common stimulation-related and transient side effects. Stimulation-induced dyskinesia is frequently managed with a reduction in the dosage of dopaminergic medications. In fact, in order to control symptoms with fewer medication side effects, programming of DBS—particularly the first few sessions—is performed along with changes in levodopa doses.

if bilateral procedures are staged. Although high rates of dysarthria have been reported following bilateral surgery for tremor, its occurrence has been infrequent in our experience with bilateral staged DBS. Benefits of treating tremor in the dominant extremity usually exceed those of treating nondominant tremor, so most patients prefer that the dominant side be the first one treated.

TECHNICAL OPTIONS

There are several technical options for implantation of DBS systems. Stereotactic procedures rely on co-registration of preoperative imaging with external and internal fiducials, or points of reference. Targeting of the intended structures is performed by combining direct and indirect methods. Direct methods rely on identification of the target structures with imaging, such as visualization of the STN and GPi on preoperative magnetic resonance imaging (MRI). Indirect targeting relies on cadaveric anatomic atlases and coordinate systems that infer the location of the intended structures in relation to anatomical points of reference.

Frame-based systems

In the most common approach to DBS surgery,⁷ stereotactic frames are placed over the patient's head and

secured with pins. The frame becomes the fixed point of reference for accurate stereotactic surgery and must remain in place for the duration of the procedure. Computed tomography or MRI is then performed with the frame in place, so that the images are co-registered with the fiducial points of the stereotactic frame. The targets are then selected for surgery and trajectories are chosen based on anatomic structures. The patient is positioned supine and the frame and head are secured to the operating table. The coordinates calculated by the clinical workstations are then set to the stereotactic frame and arc. The stereotactic arc (**Figure 2**) is attached to the base of the frame and the entry points of the leads—where the burr hole will be placed—are marked on the skin and then on the skull. Once the burr hole and opening of the meninges are completed, the targeting cannulae are inserted. The microelectrode system is then mounted for recording of the target area and subsequently for final lead implantation.

Frameless systems

The workflow and overall surgical procedure for implantation of DBS with frameless systems are similar to those of the frame-based procedure. However, instead of fixing the head to a rigid frame that prevents head motion,

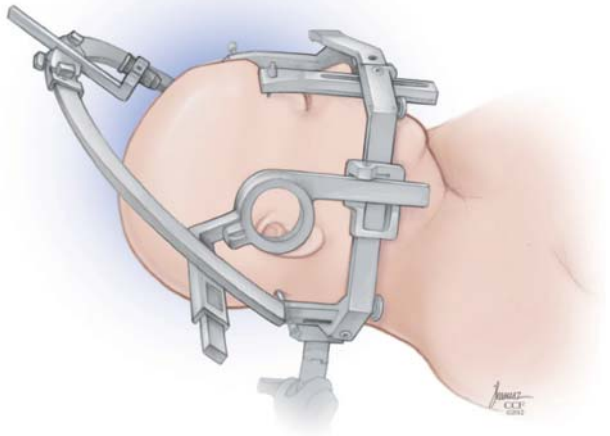


FIGURE 2. In a frame-based system, the stereotactic arc is attached to the base of the frame. Entry points of the leads are marked on the skin and on the skull.

a lighter-weight, frameless system is fixed to the head and moves with it (**Figure 3**). First, metal screws and fiducials are fixed to the head under local anesthesia or sedation. Preoperative imaging is then acquired with the fiducials in place and the surgical plans are completed in the same fashion as for frame-based surgery. The patient is then placed supine on the operating table and the frameless system is attached to the head with the aid of image guidance, in the location determined by target and trajectory planning.

The key advantage of the frameless system over the frame-based system is greater mobility of the head. Another important advantage is easier access to the airway, should an emergency situation occur. In our practice, patients with experience of both frameless and frame-based systems did not report significantly less discomfort with the frameless system.

The frameless system also has disadvantages, including less secure fixation of the head, which can add risk to the procedure. In addition, because of its lightweight, plastic construction, it provides less robust support to the instrumentation entering the brain than do metallic head frames and, in some cases, there is less flexibility for adjusting targets if needed during surgery. In addition, frameless systems are nonreusable and represent a substantial additional cost.

Microelectrode recording

Physiologic verification of anatomic targets identified by imaging can be accomplished with microelectrode recording (MER). This technique involves placing fine, high-impedance electrodes through the target area, so that anatomic structures can be recognized by characteristic electrical activity of individual neurons or groups of neurons. The locations of the structures are identified

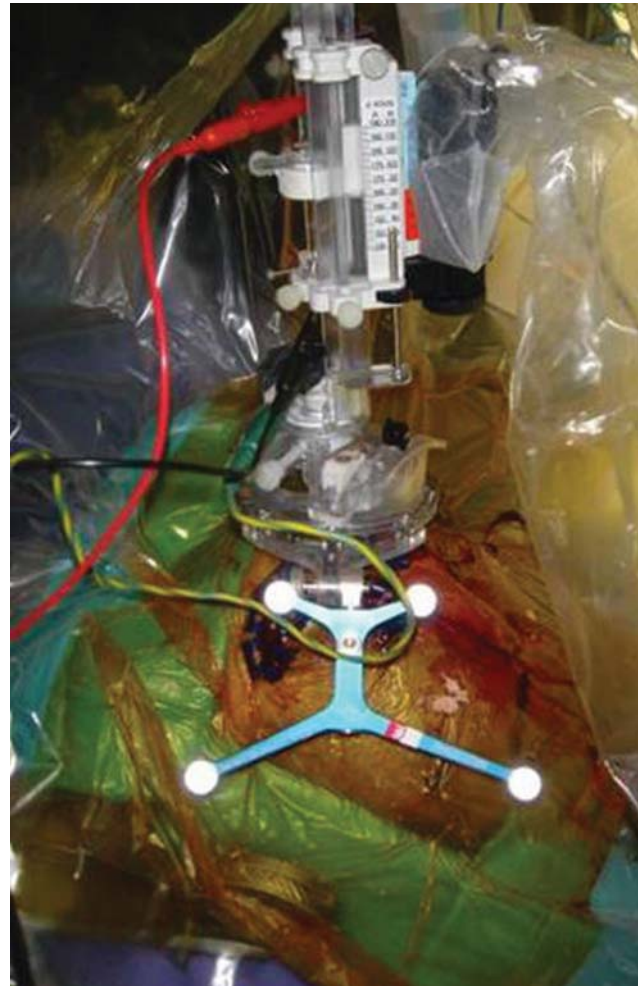

FIGURE 3. Surgeon's view of the frameless device, placed over the head approximately at the level of the coronal suture. The occipital area is in the bottom of the figure. When a frameless system is used, a lighter-weight structure is affixed to the head.

and the lengths of the electrode trajectories through the different structures—as well as the gaps between these structures—are recorded. The distances are then compared with the anatomy and a best-fit model is created to infer the location of the trajectory in the target area. Additional MER penetrations are made in order to further delineate the anatomy. Once a location for implantation has been selected, the DBS lead is inserted into the target area.

Electrode implantation

Lead implantation is often performed under fluoroscopic guidance in order to ensure accuracy and stability. When implanted, the electrode may cause a microlesional effect, manifested by transient improvement in symptoms.

The DBS leads are then connected to external pulse generators and assessed for clinical benefits and

side effects. Amplitude, pulse width, and frequency are adjusted to test the therapeutic window of stimulation (clinical improvement thresholds versus side effect thresholds). Some PD patients develop dyskinesia during test stimulation, which may be a positive indicator for lead location. If good effects and a therapeutic window are observed, the location of the lead is considered to be satisfactory and the procedure is completed.

Pulse generator implantation

During the final step of surgery, performed under general anesthesia, the pulse generator is implanted. The extension cable that connects the DBS lead to the implantable pulse generator is tunneled subcutaneously, connecting the DBS lead to the pulse generator in the chest.

Intraoperative, real-time MRI stereotaxis

Real-time intraoperative MRI has become available for DBS implantation with devices recently cleared for use by the FDA. The procedure, typically performed in a diagnostic MRI suite, uses MR images acquired during surgery to guide DBS lead implantation in the target area and to verify implantation accuracy.⁸

REFERENCES

1. Rezaei AR, Machado AG, Azmi H, Kubu C, Boullis NM. Surgery for movement disorders. *Neurosurg* 2008; 62(SHC suppl 2): SHC809–SHC839.
2. Krack P, Batir A, Van Blercom N, et al. Five-year follow-up of bilateral stimulation of the subthalamic nucleus in advanced Parkinson's disease. *N Engl J Med* 2003; 349:1925–1934.
3. Machado A, Fernandez HH, Deogaonkar M. Deep brain stimulation: what can patients expect from it? *Cleve Clin J Med* 2012; 79:113–120.
4. Vidailhet M, Vercueil L, Houeto JL, et al. Bilateral deep-brain stimulation of the globus pallidus in primary generalized dystonia. *N Engl J Med* 2005; 352:459–467.
5. Kupsch A, Benecke R, Müller J, et al. Pallidal deep-brain stimulation in primary generalized or segmental dystonia. *N Engl J Med* 2006; 355:1978–1990.
6. Gruber D, Trottenberg T, Kivi A, et al. Long-term effects of pallidal deep brain stimulation in tardive dystonia. *Neurology* 2009; 73:53–58.
7. Gross RE, Sharan AD, Benabid AL. Deep brain stimulation for Parkinson's disease: surgical technique and perioperative management. *Mov Disord* 2006; 21(suppl 14):S247–S258.
8. Starr PA, Martin AJ, Ostrem JL, et al. Subthalamic nucleus deep brain stimulator placement using high-field interventional magnetic resonance imaging and a skull-mounted aiming device: technique and application accuracy. *J Neurosurg* 2010; 112:479–490.

Correspondence: Andre Machado, MD, PhD, Center for Neurological Restoration, Cleveland Clinic, 9500 Euclid Avenue, S31, Cleveland, OH 44195; machada@ccf.org