

TABLE OF CONTENTS

FROM THE EDITOR

The 'T' in ITP remains **595**

The "I" has changed its meaning and the "P" is not necessary to make the diagnosis, but the disease formerly known as idiopathic thrombocytopenic purpura (ITP) remains important to diagnose.

B.F. MANDELL

THE CLINICAL PICTURE

A woman with a swollen uvula **600**

A woman on patient-controlled analgesia with morphine suddenly develops shortness of breath because of uvular swelling obstructing the airway. What is the diagnosis?

S.A. PANDE, K. RAGHAV, S. MEHTA, G. BABBAR, AND S. KANDPAL

POINT AND COUNTERPOINT

The apples and oranges of cost-effectiveness: A rejoinder **608**

A recent *CCJM* commentary used straw men to indict cost-effectiveness research.

C.I. UDEH AND B.L. UDEH

The conundrum of cost-effectiveness **610**

The author of the commentary replies.

V. PRASAD

THE CLINICAL PICTURE

Flashing lights, floaters, and reduced vision **616**

A 62-year-old woman has numerous lobulated, yellowish, choroidal lesions in the left eye, and two similar but smaller lesions in the right eye. What is the cause?

A.H. ALRAIYES, M.C. ALRAIYES, F.A. ALMEIDA, AND A.D. SINGH



IM BOARD REVIEW

Fever, dyspnea, and hepatitis in an Iraq veteran **623**

About 8 weeks after returning home, he presents with a cough, myalgia, headaches, fever, chills, drenching night sweats, and dyspnea on exertion. What is the most likely diagnosis?

R.L. GUTIÉRREZ AND J.D. HARTZELL

CONTINUED ON PAGE 590

CLEVELAND CLINIC JOURNAL OF MEDICINE

Online Features

Free e-mail alerts

To receive your free e-mail Table of Contents (eTOC) when a new issue of the *Cleveland Clinic Journal of Medicine* is released, just click on "Alerts" from any page at www.ccm.org.

It is quick and easy. All you need is your e-mail address. No other registration information is required.

Social Networking

To post a *CCJM* article to Facebook or your favorite social networking site, just click on the icon at the bottom of any online article.



CONTINUED FROM PAGE 588

CME CREDIT REVIEW 631

The role of aldosterone receptor antagonists in the management of heart failure: An update

Spironolactone (Aldactone) and eplerenone (Inspra) are now part of standard therapy. Still, they must be used cautiously, as they can cause hyperkalemia.

V. NAGARAJAN, M. CHAMSI-PASHA, AND W.H.W. TANG

CME CREDIT REVIEW 641

Immune thrombocytopenia in adults: An update

Management has changed in the last decade, with new drugs and with increased awareness of treatment side effects.

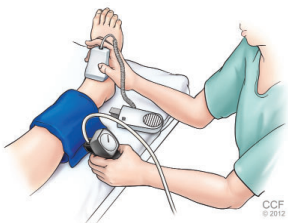
S. THOTA, G. KISTANGARI, H. DAW, AND T. SPIRO

CME CREDIT REVIEW 651

Using the ankle-brachial index to diagnose peripheral artery disease and assess cardiovascular risk

The authors seek to convince you to measure the ankle-brachial index in any patient you suspect may have peripheral artery disease, whether or not they have symptoms.

E.S.H. KIM, K. WATTANAKIT, AND H.L. GORNIK



DEPARTMENTS 594

CME Calendar

Directions for taking CME tests online 663

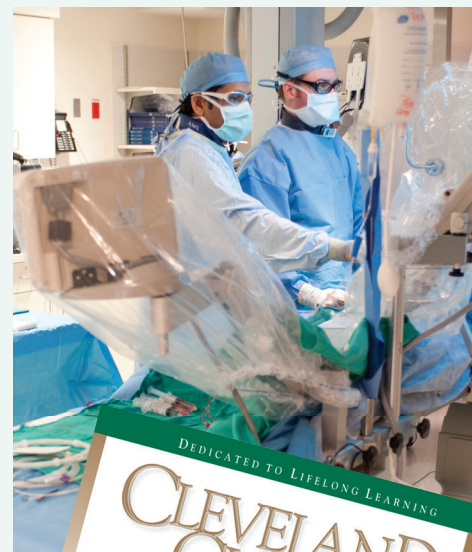To receive CME credit, read any or all of the CME-certified articles in this issue (those that carry the CME logo), then go to www.ccjm.org to take the test for the article or articles you select. It should take up to 1 hour to complete the activity for each article.

Release date: September 1, 2012

Expiration date: August 31, 2013

UPCOMING FEATURES

- Hypertension in the elderly: Practical considerations
- Chronic kidney disease in African Americans: Strategies for improving care
- Male hypogonadism is more than low testosterone
- Mild cognitive impairment: Hope for stability, plan for progression
- The adult Asperger patient in your waiting room
- Emergency contraception: Clarifying the myths
- Hereditary colorectal cancer: Recognizing and managing these syndromes in practice



DEDICATED TO LIFELONG LEARNING
CLEVELAND CLINIC JOURNAL OF MEDICINE