

SUPRAPUBIC PUNCTURE IN THE TREATMENT OF NEUROGENIC BLADDER

CHARLES C. HIGGINS, M.D.
W. JAMES GARDNER, M.D.
WM. A. NOSIK, M.D.

The treatment of "cord bladder", a disturbance of bladder function from disease or trauma of the spinal cord, can be a difficult problem. Until the recent publications of Munro, there was little physiological basis for whatever treatment was instituted. With the advent of tidal drainage and recognition of the various types or stages of a given cord bladder, more satisfactory results have been obtained.

In his excellent work on the cystometry of the bladder Munro^{1,2} classifies "cord bladders" into four groups:

1. Atonic — characterized by retention and extreme distention from lack of detrusor tone, lack of any activity of the external urethral sphincter, and complete lack of emptying contractions.

2. Autonomous — the detrusor and internal sphincter musculature show signs of reciprocal action of varying degree. There is an increase in detrusor muscle tone, and an inability to store an appreciable amount of urine without leakage. The condition of this bladder represents the end result in destructive lesions of the sacral segments or cauda equina.

3. Hypertonic — an expression of an uncontrolled spinal segmental reflex, characterized by a markedly increased detrusor muscle tone, almost constantly present emptying contractions, low residual urine, and impairment of control of the external sphincter.

4. Normal cord bladders — in transecting lesions above the sacral segments, consisting of two types which differ largely only in their cystometric findings:

- (a) Uninhibited cord bladder — an apparently normal bladder which empties itself quite regularly. The detrusor tone is still somewhat increased, emptying contractions are rhythmical, the residual is low, and the capacity is rather low.

- (b) Normal cord bladder — an apparently normal bladder with a return of subjective control. The tone of the detrusor muscle is only slightly increased, the capacity is greater, and a small amount of residual urine remains.

With the aid of the tidal drainage apparatus, and a knowledge of the various pressures applicable in promoting a more satisfactory recovery in the transitions of a given cord bladder through certain of the above stages, Munro reduced the incidence of bladder infection from

73 to 15 per cent. This is a remarkable advance in the treatment of a condition, in which infection was the chief cause of death. Since Munro's work deals essentially with observation and treatment of the acute spinal cord lesion, its applicability not only in the urological field but also in the neurosurgical becomes evident.

The relatively acute "cord bladder" in neurological cases, whether postoperative or caused by a rapidly progressing disease of the spinal cord, affords the most satisfactory application of this treatment.

It is felt that, as in other muscles affected by a lesion of the central nervous system, a certain progressive degenerative change in the involved portions of the genitourinary system occur³, and that proper drainage will favor such repair as is anatomically possible. It is well known that suprapubic cystotomy will adequately drain such a bladder for years⁴ with little regard for the possible maximum correction of a disturbed physiology, and with a very low incidence of infection. In the acute cord bladder the use of tidal drainage with the indwelling catheter, recommended by Munro, deals efficiently with the re-establishment of as normal a physiology as possible at once but possibly with the added risk of infection from its presence. The long-continued use of the indwelling catheter in even a very mildly septic prostate, bladder, or

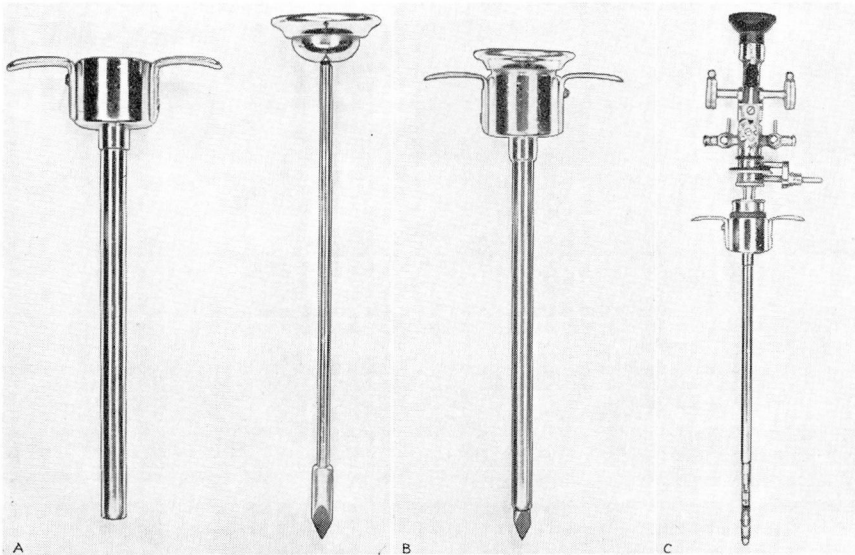


FIGURE 1: A. Cannula and trocar.
 B. Instrument assembled.
 C. The McCarthy Cystoscope is inserted into the cannula for visualization of the bladder.

urethra undergoing acute changes from disruption of nerve supply always will constitute a menace in a certain number of these cases. It seems that the problem is that of gaining efficient drainage of the bladder with the minimal risk of infection and still encouraging the resumption of as normal a physiology as the lesion of the central nervous sys-

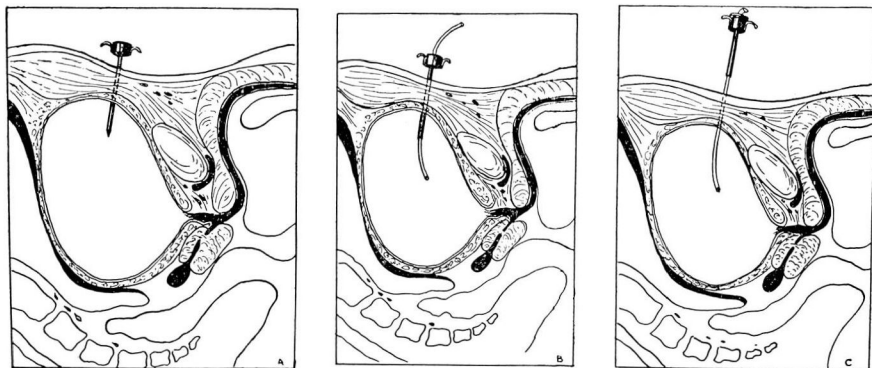


FIGURE 2: A. The trocar and cannula have been plunged into the bladder.
 B. The trocar has been removed, and a No. 18 catheter inserted through the cannula into the bladder.
 C. The cannula has been withdrawn, leaving the catheter in situ for suprapubic drainage.

tem permits. When this is accomplished, either natural or artificial drainage must continue to prevent pressure changes from occurring in the genitourinary system.

After experience with the indwelling catheter in the tidal drainage management of acute cord bladders at the Cleveland Clinic, it was decided that the use of the suprapubic catheter was worthy of a trial. This has been done in a series of cases with gratifying results from the standpoint of the patient, the surgeon, and those responsible for the nursing care.

CASE REPORTS

Case 1: A white man, 51 years of age, was admitted by ambulance after a rapidly progressive paraplegia developed following a lumbar puncture and lipiodol study. The neurological signs indicated an extramedullary cord tumor at the ninth dorsal vertebra. Complete urinary retention had been present since the lumbar puncture on the previous day, as well as marked uroepsis.

Operation: Under pentothal anesthesia a thoracic laminectomy was done and an extramedullary tumor (meningioma) was removed at the level of the ninth dorsal vertebra. The spinal cord was very edematous at the site of the tumor.

Progress: On the first postoperative day suprapubic puncture was decided upon because of the complete urinary retention. Under local anesthesia a small transverse incision was made above the symphysis and a trocar and cannula plunged into the bladder. A No. 18 catheter was inserted through the trocar and the trocar removed

TREATMENT OF THE NEUROGENIC BLADDER

after the catheter was fastened in place on the abdomen. The Munro tidal drainage apparatus was attached to the catheter.

Steady improvement in the patient's general condition then followed. There was marked improvement in the neurologic picture, and in three weeks the patient's bladder had changed from an atonic to an autonomous cord bladder. He was discharged after one month, still using the suprapubic tube to irrigate the bladder. The infection had subsided within a few days after instituting this regimen.

Case 2: A 46 year old white man was admitted with a complaint of rapidly progressive paresthesia and motor weakness from the chest downward. A small tumor of the chest wall had been removed one year previously. Pain in the back was a prominent feature of his illness for two months prior to admission. Two days before admission to the hospital an acute urinary retention developed suddenly, necessitating catheterization. The temperature from the cystitis was 102.4° F. on admission.

The neurologic signs indicated an extramedullary metastatic cord tumor at the level of the second or third dorsal vertebra. Lumbar puncture revealed a total block with a spinal fluid protein of 330 mg. Roentgenograms revealed a partial collapse of the third dorsal vertebra due to tumor.

Operation: Under avertin anesthesia a laminectomy was done from the sixth cervical to the fourth dorsal vertebrae and a soft vascular tumor was found extending the length of the exposure in the extradural space. A large portion of the tumor was removed and a decompression provided. The tumor was diagnosed as a sarcoma. Upon completion of the laminectomy a suprapubic puncture was done. The skin was prepared and infiltrated with 5 cc. of novocaine above the symphysis pubis. After nicking the skin, a trocar and cannula was plunged into the bladder. A No. 18 catheter was inserted through the trocar and the trocar removed. The catheter was fastened to the abdominal wall and the tidal drainage apparatus connected to the catheter.

Progress: The cystitis subsided moderately under treatment but an elevated temperature caused some concern. The laminectomy wound broke down on the twentieth postoperative day and discharged necrotic, purulent tissue. The wound was curetted and packed open. This improved gradually until at the time of discharge, two months after admission, the laminectomy wound had only a small sinus leading into it. The bladder had gone from an atonic to an autonomous cord bladder. Its further improvement to one of the anticipated "normal cord bladder" types was probably hindered by the urosepsis. Irrigation was continued at home after his discharge. He returned five months later for roentgen therapy to the affected regions. No further improvement was noted, the suprapubic tube still was in place, but there was no evidence of urinary tract infection.

The use of the suprapubic puncture in these two cases of acute cord bladder complicated by urosepsis, together with the use of the tidal drainage, presented a very satisfactory method of managing a difficult situation. Physiological conditions were maintained by the tidal drainage to regain as much as possible of the normal function of the bladder, while the suprapubic puncture afforded a clean and convenient method of drainage in the presence of infection. With this method of treatment bladder infection has been reduced to a minimum by avoiding the prolonged use of a urethral catheter. In like manner renal infection has not occurred in cases in which suprapubic puncture and the Munro tidal drainage apparatus has been employed.

CONCLUSION

The use of a suprapubic catheter to drain the bladder in conditions associated with disease or trauma of the spinal cord is followed by

fewer complications in the urinary tract than when prolonged urethral retention catheter drainage is used.

The Munro tidal drainage apparatus can be attached to the suprapubic catheter in the same manner as when a urethral catheter is employed.

The introduction of the catheter through the trocar can easily be accomplished under local anesthesia and obviates the necessity of a more extensive surgical procedure to expose the bladder and institute drainage.

REFERENCES

1. Munro, D.: "Cord bladder"—its definition, treatment and prognosis when associated with spinal cord injuries, *J. Urol.* 36:710-729, (December) 1936.
2. Munro, D.: "The cord bladder"—its definition, treatment and prognosis when associated with spinal cord injuries, *New England J. Med.* 215:766-777, (October 22) 1936.
3. Head, H. and Riddoch, G.: Sensory disturbances in hand following injuries of cerebral cortex, *Brit. M. J.* 2:782, (November 20) 1920.
4. Boyd, M. L.: Suprapubic cystotomy for drainage; technique and results, *J. Urol.* 36:740-755, (December) 1936.