

Q: Does massive hemoptysis always merit diagnostic bronchoscopy?

ABDUL HAMID ALRAIYES, MD

Pulmonary, Allergy, and Critical Care Medicine, Respiratory Institute, Cleveland Clinic

M. CHADI ALRAIYES, MD, FACP

Department of Medicine, Division of Cardiology, University of Minnesota, Minneapolis

MICHAEL S. MACHUZAK, MD, FCCP

Pulmonary, Allergy, and Critical Care Medicine, Respiratory Institute, Cleveland Clinic

A: Yes, all patients with massive hemoptysis should undergo diagnostic bronchoscopy. The procedure plays an important role in protecting the airway, maintaining ventilation, finding the site and underlying cause of the bleeding, and in some cases stopping the bleeding, either temporarily or definitively.

Frightening to patients, massive hemoptysis is a medical emergency and demands immediate attention by an experienced pulmonary team.¹ Hemoptysis can be the initial presentation of an underlying infectious, autoimmune, or malignant disorder (TABLE 1).² Fortunately, most cases of hemoptysis are not massive or life-threatening.¹

■ WHAT IS 'MASSIVE' HEMOPTYSIS?

Numerous studies have defined massive hemoptysis on the basis of the volume of blood lost over time, eg, more than 1 L in 24 hours or more than 400 mL in 6 hours.

Ibrahim³ has proposed that we move away from using the word “massive,” which is not useful, and instead think in terms of “life-threatening” hemoptysis, defined as any of the following:

- More than 100 mL of blood lost in 24 hours (a low number, but blood loss is hard to estimate accurately)

- Causing abnormal gas exchange due to airway obstruction
 - Causing hemodynamic instability.
- In this article, we use the traditional “massive” terminology.

■ BRONCHOSCOPY IS SUPERIOR TO IMAGING FOR DIAGNOSIS

Radiography can help identify the side or the site of bleeding in 33% to 82% of patients, and computed tomography can in 70% to 88.5%.⁴ Magnetic resonance imaging may also have a role; one study found it useful in cases of thoracic endometriosis during the quiescent stage.⁵ However, transferring a patient who is actively bleeding out of the intensive care unit for imaging can be challenging.

Flexible bronchoscopy is superior to radiographic imaging in evaluating massive hemoptysis: it can be performed at the bedside and can include therapeutic procedures to control the bleeding until the patient can undergo a definitive therapeutic procedure.⁶ It has been found helpful in identifying the side of bleeding in 73% to 93% of cases of massive hemoptysis.⁶

However, one should consider starting the procedure with a rigid bronchoscope, which protects the airway better and allows for better ventilation during the procedure than a flexible one. One can use it to isolate the nonbleeding lung and to apply pressure to the bleeding site if it is in the main bronchus.⁷ Measuring 12 mm in diameter, a rigid scope cannot go as far into the lung as a flexible bronchoscope (measuring 6.4 mm), but a flexible bronchoscope can be introduced through the rigid bronchoscope to go further in.

Bronchoscopy enables procedures to control bleeding until the patient can undergo a definitive procedure

doi:10.3949/ccjm.81a.13145

TABLE 1

Causes of massive hemoptysis

Pulmonary

Bronchiectasis
Pulmonary embolism
Cystic fibrosis
Bullous emphysema

Iatrogenic

Bronchoscopy (transbronchial biopsy)
Swan-Ganz catheter-induced infarction
Pulmonary artery rupture
Transtracheal aspiration
Lymphangiography

Vascular

Pulmonary hypertension
Arteriovenous malformation
Aortic aneurysm

Drugs or toxins

Anticoagulants
Penicillamine
Trimellitic anhydride
Solvents
Crack cocaine
Aspirin
Thrombolytic agents

Hematologic

Coagulopathy
Disseminated intravascular coagulation
Thrombocytopenia
Platelet dysfunction
von Willebrand disease

Infectious

Lung abscess
Mycetoma
Necrotizing pneumonia
Parasitic
Fungal or tuberculous
Viral

Neoplastic

Bronchial adenoma
Bronchogenic carcinoma
Metastatic cancer

Traumatic

Blunt or penetrating chest injury
Ruptured bronchus
Fat embolism
Tracheo-innominate artery fistula

Systemic diseases

Goodpasture syndrome
Granulomatosis with polyangiitis
Systemic lupus erythematosus
Vasculitis
Behçet disease
Idiopathic pulmonary hemosiderosis

MANAGEMENT OPTIONS

The management team should include an anesthesiologist, an intensivist, a thoracic surgeon, an interventional radiologist, and an interventional pulmonologist.

In the intensive care unit, the patient should be placed in the lateral decubitus position on the bleeding side. To maintain ventilation, the nonbleeding lung should be intubated with a large-bore endotracheal

tube (internal diameter 8.5–9.0 mm) or, ideally, with a rigid bronchoscope.⁶ Meanwhile, the patient's circulatory status should be stabilized with adequate fluid resuscitation and transfusion of blood products, with close monitoring.

Once the bleeding site is found, a bronchoscopic treatment is selected based on the cause of the bleeding. Massive hemoptysis usually arises from high-pressure bronchial

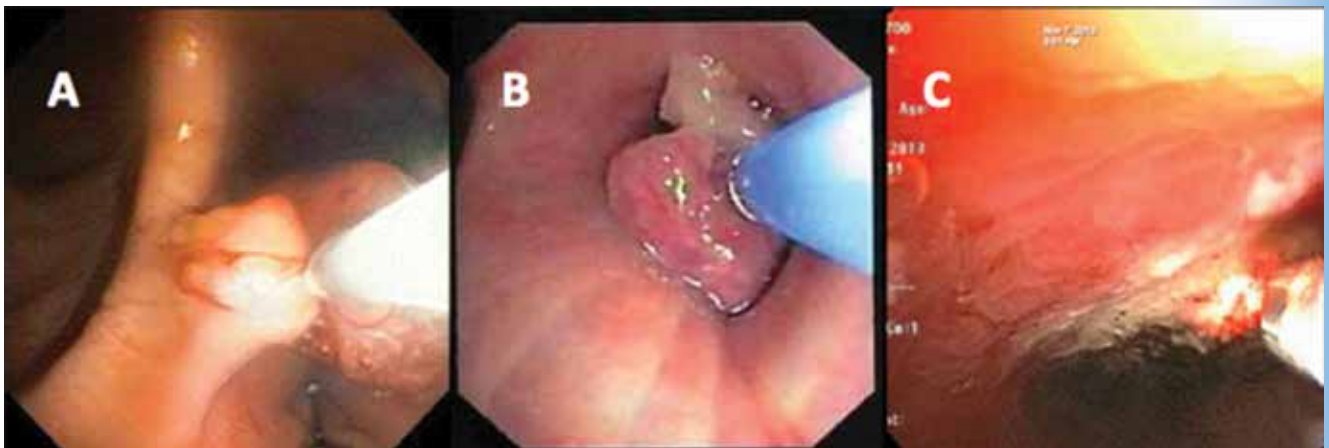


FIGURE 1. Flexible bronchoscopic views showing: A, clot desiccation using argon plasma coagulation; B, a frozen clot using cryotherapy; and C, hemostasis achieved by neodymium-yttrium-aluminum perovskite laser.

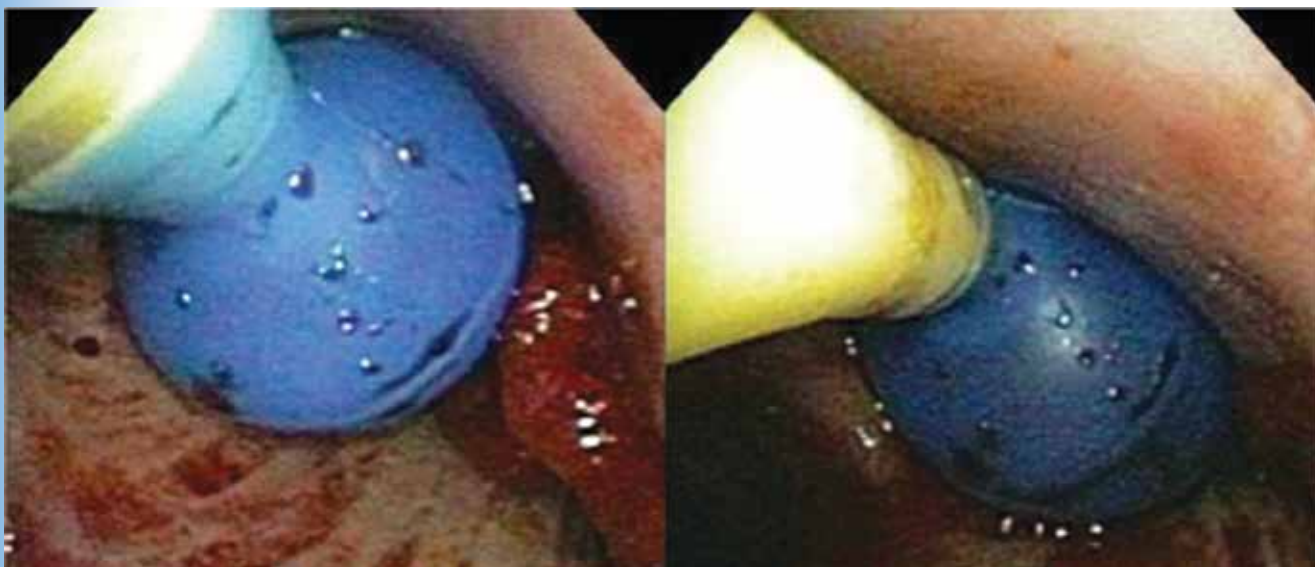


FIGURE 2. An endobronchial blocker is placed via the flexible bronchoscope.

vessels (90%) or, less commonly, from non-bronchial vessels or capillaries (10%).⁸ A variety of agents (eg, cold saline lavage, epinephrine 1:20,000) can be instilled through the bronchoscope to slow the bleeding and offer better visualization of the airway.⁶

If a bleeding intrabronchial lesion is identified, such as a malignant tracheobronchial tumor, local coagulation therapy can be applied through the bronchoscope. Op-

tions include laser treatment, argon plasma coagulation, cryotherapy, and electrocautery (**FIGURE 1**).^{9,10}

If the bleeding persists or cannot be localized to a particular subsegment, an endobronchial balloon plug can be placed proximally (**FIGURE 2**). This can be left in place to isolate the bleeding and apply tamponade until a definitive procedure can be performed, such as bronchial artery embolization, radiation therapy, or surgery. ■

REFERENCES

1. Jean-Baptiste E. Clinical assessment and management of massive hemoptysis. *Crit Care Med* 2000; 28:1642–1647.
2. Abi Khalil S, Gourdier AL, Aoun N, et al. Cystic and cavitary lesions of the lung: imaging characteristics and differential diagnosis [in French]. *J Radiol* 2010; 91:465–473.
3. Ibrahim WH. Massive haemoptysis: the definition should be revised. *Eur Respir J* 2008; 32:1131–1132.
4. Khalil A, Soussan M, Mangiapan G, Fartoukh M, Parrot A, Carette MF. Utility of high-resolution chest CT scan in the emergency management of haemoptysis in the intensive care unit: severity, localization and aetiology. *Br J Radiol* 2007; 80:21–25.
5. Cassina PC, Hauser M, Kad G, Imthurn B, Schröder S, Weder W. Catamenial hemoptysis. Diagnosis with MRI. *Chest* 1997; 111:1447–1450.
6. Sakr L, Dutau H. Massive hemoptysis: an update on the role of bronchoscopy in diagnosis and management. *Respiration* 2010; 80:38–58.
7. Conlan AA, Hurwitz SS. Management of massive haemoptysis with the rigid bronchoscope and cold saline lavage. *Thorax* 1980; 35:901–904.
8. Deffebach ME, Charan NB, Lakshminarayan S, Butler J. The bronchial circulation. Small, but a vital attribute of the lung. *Am Rev Respir Dis* 1987; 135:463–481.
9. Morice RC, Ece T, Ece F, Keus L. Endobronchial argon plasma coagulation for treatment of hemoptysis and neoplastic airway obstruction. *Chest* 2001; 119:781–787.
10. Sheski FD, Mathur PN. Cryotherapy, electrocautery, and brachytherapy. *Clin Chest Med* 1999; 20:123–138.

ADDRESS: Abdul Hamid Alraiyes, MD, Pulmonary, Allergy, and Critical Care Medicine, Respiratory Institute, A90, Cleveland Clinic, 9500 Euclid Avenue, Cleveland, OH 44195; e-mail: al_rayes@yahoo.com