

THE CLINICAL PICTURE

CYNTHIA H. HO, MD

Assistant Professor of Clinical Medicine and Pediatrics, Los Angeles County and University of Southern California Medical Center, Keck School of Medicine, Los Angeles, CA

JAMIE LIN, MD

Glendale Adventist Medical Center, Glendale, CA

The Clinical Picture

An 18-year-old woman with hepatic cysts

AN 18-YEAR-OLD WOMAN presents with 3 days of epigastric abdominal pain, with no fever or constitutional symptoms. She was born in the United States and reports yearly trips since age 3 to her family's farm in a rural area of Mexico, where she is exposed to dogs and horses.

Ultrasonography reveals two large hepatic cysts measuring $5.8 \times 6.8 \times 5.4$ cm and $5.3 \times 4.9 \times 7$ cm, with thickened walls and internal debris (FIGURE 1). The debris moves to dependent areas when the patient is asked to move onto her side.

Laboratory values at the time of presentation are as follows:

- White blood cell count $11.9 \times 10^9/L$ (reference range 4.5–11.0), with 20% eosinophils
- Alkaline phosphatase 116 U/L (30–100)
- Total protein 7.3 g/dL (6.0–8.0)
- Albumin 4.3 g/dL (3.5–5.0)
- Aspartate aminotransferase (AST) 19 U/L (10–40)
- Alanine aminotransferase (ALT) 18 U/L (5–40)
- Total bilirubin 0.2 mg/dL (0.3–1.2)
- Direct bilirubin 0.1 mg/dL (0.1–0.3)
- *Echinococcus* antibody (IgG) testing is positive.

■ CYSTIC ECHINOCOCCOSIS

The two clinically relevant species of *Echinococcus* that cause human infection are *E granulosus* (in cystic echinococcosis) and *E multilocularis* (in alveolar echinococcosis). Based on clinical and radiographic findings, hepatic hydatid disease from cystic echinococcosis can usually be differentiated from the alveolar form.

E granulosus is a parasitic tapeworm that requires an intermediate host (sheep, goats, cows) and a definite host (dogs, foxes, and related species) for its life cycle. Humans become infected when they ingest food contaminated with feces that contain the eggs of the tapeworm or when they handle carnivorous animals, usually

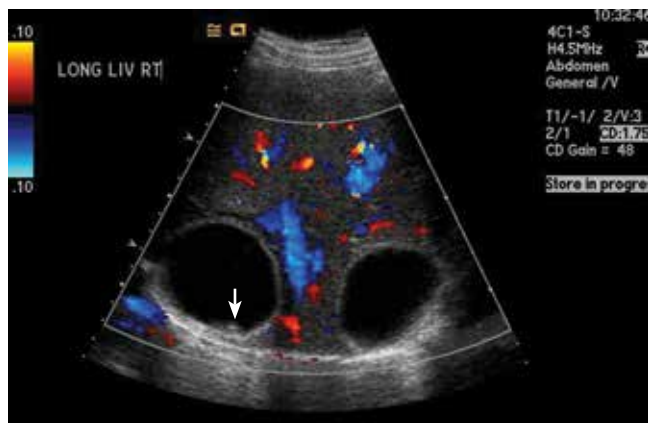


FIGURE 1. Ultrasonography of the liver shows two large, anechoic hepatic cysts with thickened walls and internal debris (arrow).

dogs, and accidentally ingest the tapeworm eggs. Once ingested, the egg releases an oncosphere that penetrates the intestinal wall, enters the circulation, and develops into a cyst, most often in the liver and the lungs.¹ Human-to-human transmission does not occur.²

Hydatid cysts grow slowly, at a rate of 1 to 50 mm per year,³ so most patients remain asymptomatic for several years. Symptoms occur when a cyst ruptures or impinges on structures.³ Fever and constitutional symptoms usually occur only if there is rupture or bacterial superinfection of the cyst. Tests of liver function tend to be normal unless a cyst obstructs biliary flow. Eosinophilia occurs in 25% of patients.¹ Eosinophilia along with the abrupt onset of abdominal pain suggests cyst rupture.

Making the diagnosis

Diagnosis is made by characteristic ultrasonographic findings and by serologic testing. Antibody assays for *Echinococcus* include indirect hemagglutination, enzyme-linked immunosorbent assay, and latex agglutination. However, these serologic antibody assays for immunoglobulin G

doi:10.3949/ccjm.81a.13059

cross-react to different echinococcal species as well as to other helminthic infections. Specific serologic studies such as an enzyme-linked immunosorbent assay for *E multilocularis* are available to confirm the species of *Echinococcus* but are only used to distinguish cystic echinococcosis from alveolar echinococcosis.

Treatment options

Treatment options include surgery, percutaneous procedures, drug therapy, and observation.

Currently, there is no clear consensus on treatment. To guide treatment decisions, the World Health Organization Informal Working Group on Echinococcosis (WHO-IWGE) recommends management of hepatic hydatid cysts based on classification, size, symptoms, location, and available resources.³

Two percutaneous treatments are aspiration, injection, and re-aspiration to destroy the germinal matrix, and percutaneous therapy to destroy the endocyst. Percutaneous aspiration, injection, and re-aspiration is increasingly used as the first-line treatment for single or easily accessible cysts and for patients who cannot undergo surgery. Surgery is considered for multiple cysts, large cysts, and cysts not easily accessible with a percutaneous technique.³ Complication rates and length of hospital stay with percutaneous aspiration are lower than with surgery.⁴ Observation is recommended for small, asymptomatic, inactive cysts.

Leakage of cyst contents during surgical or percutaneous intervention or spontaneous rupture can cause a recurrence,⁵ and anaphylaxis is a potential complication of cyst rupture.¹ For this reason, giving oral albendazole (Albenza) is recommended before any intervention. Sterilization of the cyst contents with a protoscolicidal agent (20% NaCl) before evacuation of cyst contents is also standard practice.

The rate of cyst recurrence is 16.2% with open surgery and 3.5% with percutaneous intervention.⁶

REFERENCES

1. McManus DP, Gray DJ, Zhang W, Yang Y. Diagnosis, treatment, and management of echinococcosis. *BMJ* 2012; 344:e3866.
2. McManus DP, Zhang W, Li J, Bartley PB. Echinococcosis. *Lancet* 2003; 362:1295–1304.
3. Brunetti E, Kern P, Vuitton DA; Writing Panel for the WHO-IWGE. Expert consensus for the diagnosis and treatment of cystic and alveolar echinococcosis in humans. *Acta Trop* 2010; 114:1–16.
4. Khuroo MS, Wani NA, Javid G, et al. Percutaneous drainage compared with surgery for hepatic hydatid cysts. *N Engl J Med* 1997;

A higher incidence of recurrence in patients who undergo surgical cystectomy likely reflects the more complicated and active nature of the cysts in patients who undergo surgery.⁶

Albendazole is the drug of choice for hepatic hydatid disease.³ The optimal duration of treatment is unclear but should be guided by a combination of clinical response, medication side effects, serologic titers, and imaging. The most common adverse effects of albendazole are hepatotoxicity, abdominal pain, and nausea.

OUR PATIENT'S DIAGNOSIS AND TREATMENT

In our patient, ultrasonography confirmed the diagnosis of cystic echinococcosis by the finding of active anechoic cysts with echogenic internal debris and with a well-delineated cyst wall. The WHO-IWGE classification was CE1, ie, active anechoic cysts with internal echogenic debris.

Our patient underwent surgical rather than percutaneous cystectomy because of concern about possible cyst leakage, since she had presented with the acute onset of pain and eosinophilia. We were also concerned about the subdiaphragmatic location of the larger cyst, which could have been difficult to reach percutaneously.

Open total pericystectomy involved opening the cyst cavity, sterilizing the contents with 20% NaCl, evacuating the cyst contents, and removing the cyst tissue. Two large cysts were excised and sent for histologic examination, which confirmed *E granulosus*. Percutaneous aspiration was necessary 4 months later because of a recurrence, and albendazole 400 mg twice daily was continued for another 5 months. Ultrasonography 3 years later showed no evidence of echinococcal cysts, and her antibody titers remain undetectable.

337:881–887.

5. Kayaalp C, Sengul N, Akoglu M. Importance of cyst content in hydatid liver surgery. *Arch Surg* 2002; 137:159–163.
6. Yagci G, Ustunsoz B, Kaymakcioglu N, et al. Results of surgical, laparoscopic, and percutaneous treatment for hydatid disease of the liver: 10 years experience with 355 patients. *World J Surg* 2005; 29:1670–1679.

ADDRESS: Cynthia H. Ho, MD, Los Angeles County and University of Southern California Medical Center, 2020 Zonal Avenue, IRD Room 109, Los Angeles, CA 90033; e-mail: cynho@usc.edu