

TABLE OF CONTENTS

FROM THE EDITOR

Polycystic kidney disease: Molecular understanding dictating management **516**

It was the early 1980s, I was a resident in the emergency room, and the patient had fever, flank pain, hypotension, and a normal urinalysis.

B.F. MANDELL

THE CLINICAL PICTURE

Hypertrophic cardiomyopathy apical variant **517**

When a professional soccer player required ankle surgery, his electrocardiogram showed several abnormalities.

A.M.-H. HO, P.T. CHUI, A.P.W. LEE, AND S. WAN

THE CLINICAL PICTURE

'Allergic to the sun' **520**

A homeless man presents with burning pain and lesions in his arm for the past 2 to 3 days.

N.M. RAJAN AND C.L. ELLIS

THE CLINICAL PICTURE

Erythema and atrophy on the tongue **523**

Oral abnormalities can result from nutritional deficiencies and a host of other conditions.

E. GÓMEZ-MOYANO, L.M. PÉREZ-BELMONTE, L. MARTÍNEZ-PILAR, AND D.J. GODOY-DÍAZ

1-MINUTE CONSULT

Can we reduce the risk of readmission for a patient with an exacerbation of COPD? **525**

The risk can be reduced by using a checklist before discharge and by implementing outpatient programs that continue patient education and provide rapid access to medical support if needed.

M.B. AYACHE, S. BOYAJI, AND J.C. PILE

COMMENTARY

To improve our patients' health, look beyond reducing readmissions **528**

Focusing on the readmission rate diverts attention from more proactive ways to improve safety, quality, and value.

A.J. WARMUTH AND S.C. PHILLIPS

CONTINUED ON PAGE 515

Online Features

Free e-mail alerts

To receive your free e-mail Table of Contents (eTOC) when a new issue of the *Cleveland Clinic Journal of Medicine* is released, just click on "Alerts" from any page at www.ccm.org.

It is quick and easy. All you need is your e-mail address. No other registration information is required.

Social Networking

To post a *CCJM* article to Facebook or your favorite social networking site, just click on the icon at the bottom of any online article.



Upcoming Features

- New oral anticoagulants: Perioperative management
- Why study cardiovascular outcomes in type 2 diabetes?
- Managing snoring: When to consider surgery
- Testosterone replacement: The knowns and unknowns
- Do all patients need an ECG before noncardiac surgery?
- IL28B polymorphisms and hepatitis C treatment
- Caring for women with HIV
- Help your patients quit smoking
- Screening tests: What's recommended? What's controversial?



DEDICATED TO LIFELONG LEARNING
CLEVELAND CLINIC JOURNAL OF MEDICINE

SEPTEMBER 2014

CONTINUED FROM PAGE 514

REVIEW **CME CREDIT**
Hand, foot, and mouth disease: Identifying and managing an acute viral syndrome **537**

This is typically a benign childhood infection—except when it isn't so benign or when it occurs in an adult.

G.L. REPASS, W.C. PALMER, AND F.F. STANCAMPIANO

MEDICAL GRAND ROUNDS **CME CREDIT**
Advances in autosomal dominant polycystic kidney disease—2014 and beyond **545**

An overview of its pathogenesis, diagnosis, management, complications, and future possible treatment.

W.E. BRAUN

REVIEW **CME CREDIT**
The protein-sparing modified fast for obese patients with type 2 diabetes: What to expect **557**

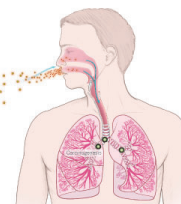
Committed patients can lose weight and control their diabetes, but they need encouragement and close supervision.

J. CHANG AND S.R. KASHYAP

REVIEW **CME CREDIT**
Radon and lung cancer: Assessing and mitigating the risk **567**

Radon exposure is the second most common cause of lung cancer, but the evidence so far does not support screening for lung cancer in people exposed to it.

H. CHOI AND P. MAZZONE



DEPARTMENTS
CME Calendar **544**

Letters to the editor **576**

A reader comments on stress testing in asymptomatic patients at low risk (July 2014).

Directions for CME **Inside back cover**

To receive CME credit, read any or all of the CME-certified articles in this issue (those that carry the CME logo), then go to www.ccm.org to take the test for the article or articles you select. It should take up to 1 hour to complete the activity for each article.

Release date: September 1, 2014
 Expiration date: August 31, 2015