

THE CLINICAL PICTURE

ANTHONY M.-H. HO, MD, FRCPC, FCCP

Professor, Department of Anesthesiology and Perioperative Medicine, Queen's University and Kingston General Hospital, Kingston, ON, Canada

PO T. CHUI, MBBS, FANZCA

Consultant, Department of Anaesthesia and Intensive Care, Prince of Wales Hospital, Shatin, NT, Hong Kong

ALEX P. W. LEE, MBChB, MRCP

Assistant Professor, Division of Cardiology, Department of Medicine and Therapeutics, The Chinese University of Hong Kong, Shatin, NT, Hong Kong

SONG WAN, MD, FRCS

Professor, Division of Cardiothoracic Surgery, Department of Surgery, The Chinese University of Hong Kong, Shatin, NT, Hong Kong

Hypertrophic cardiomyopathy apical variant

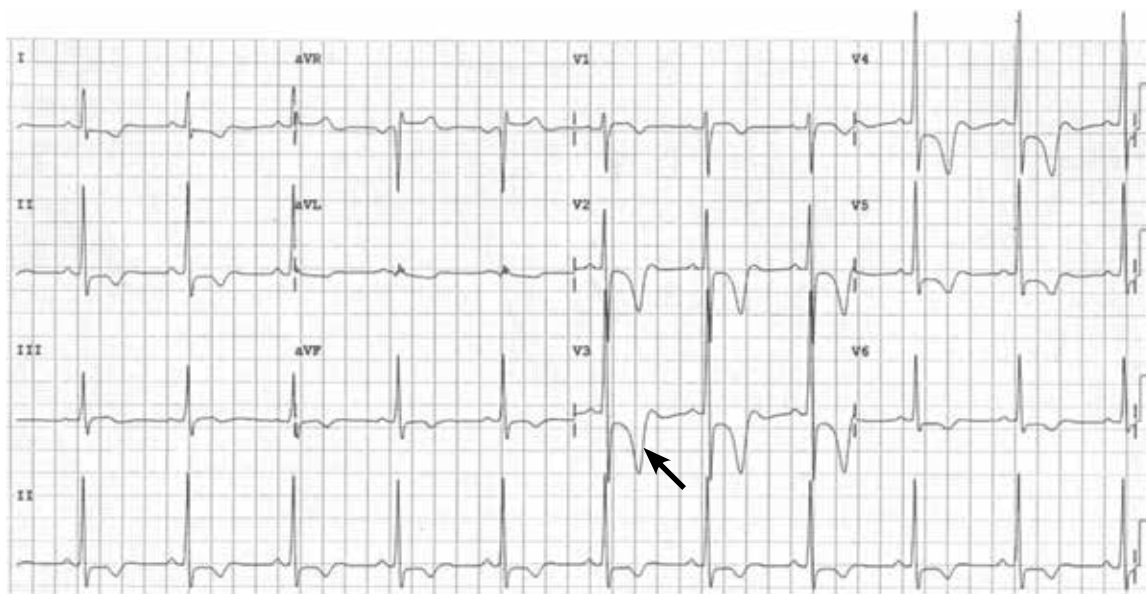


FIGURE 1. In this patient with apical hypertrophic cardiomyopathy, electrocardiography shows a loss of septal Q waves, high QRS voltage, and repolarization abnormalities with deep T-wave inversion, especially in lead V_3 (arrow). This is particularly reflective of an apical electrical cardiac event. Such abnormalities are also evident in the neighboring leads V_2 and V_4 .

A 37-YEAR-OLD Chinese professional soccer player with an abnormal electrocardiogram (FIGURE 1) required ankle surgery.

He had had an isolated syncopal episode while intensely training a year ago, but his medical history was otherwise unremarkable.

On examination, he appeared fit. His vital signs were normal. The apical pulse was sustained on palpation and was not displaced. Auscultation revealed an S4 heart sound.

Transthoracic echocardiography revealed apical hypertrophic cardiomyopathy (FIGURES 2 AND 3) and absence of regional wall-motion abnormalities. He underwent uneventful ankle surgery.

■ HYPERTROPHIC CARDIOMYOPATHY: THE APICAL VARIANT

The prevalence of hypertrophic cardiomyopathy is 0.2% to 0.5%; the apical variant constitutes about 15% to 25% of cases in Chinese and Japanese cohorts and about 3% of cases in American cohorts.¹⁻³

In typical hypertrophic cardiomyopathy, the left ventricle, especially the interventricular septum, is thickened, but the left ventricular chamber size is normal or small. In severe cases, the left ventricular outflow tract can become very narrowed, resulting in accelerated blood flow, which may further increase in the presence of hypovolemia, peripheral vasodilation, and increased cardiac contractility. The Venturi effect thus created may entrain a typically malformed anterior mitral valve leaf-

doi:10.3949/ccjm.81a.13127

Parasternal short-axis views

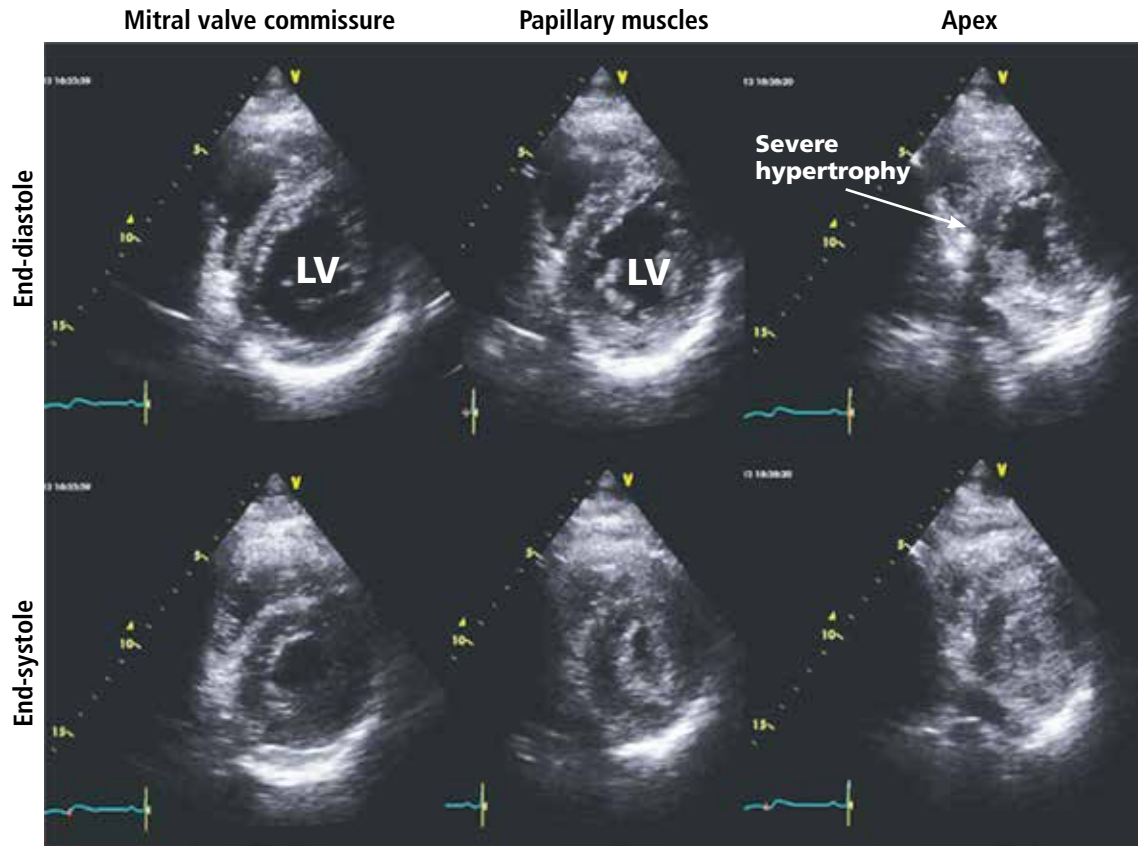


FIGURE 2. On transthoracic echocardiography, parasternal short-axis views show gross hypertrophy of the apex with relatively normal thickness of the left ventricle (LV) at the level of the mitral valve. The apex is so hypertrophied that it is obliterated at end-systole. This does not occur at the mitral level in the apical variant of hypertrophic cardiomyopathy.

Recent data challenge the conventional wisdom that the apical variant has a benign prognosis

let toward the aortic valve (systolic anterior motion), causing mitral insufficiency and exacerbating obstruction of the left ventricular outflow tract. Systolic anterior motion may play an important role in exercise-induced syncope and sudden death in young people with hypertrophic cardiomyopathy.⁴

In the apical variant, hypertrophy is confined to the left ventricular apex.¹⁻³ There is no dynamic outflow tract obstruction. Still, unexplained syncope has been reported, and recent data challenge the conventional wisdom that the apical variant of hypertro-

phic cardiomyopathy has a benign prognosis.² In patients without a history of recurrent syncope, chest pain, or heart failure, perioperative risk is probably not significantly increased. The differential diagnosis includes myocardial ischemia or infarction, electrolyte disturbances, effects of drugs (eg, digoxin), and subarachnoid hemorrhage.^{1-3,5} Plain or contrast-enhanced echocardiography or cardiac magnetic resonance imaging, or both, can help confirm the diagnosis. Long-term management should be guided by the patient's symptoms. ■

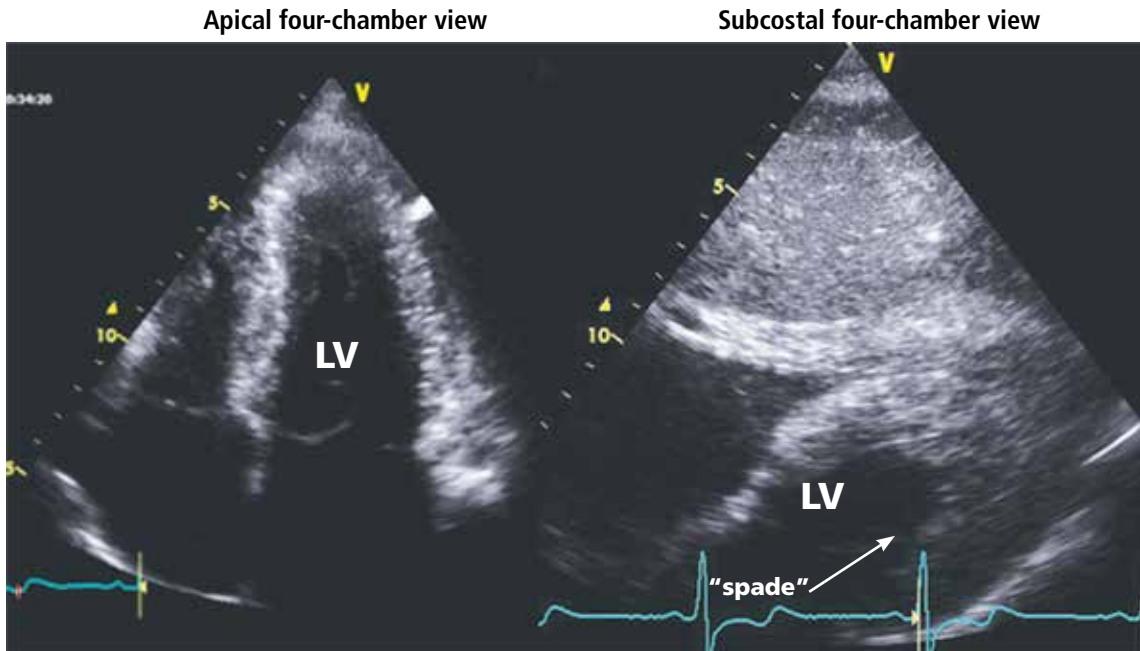


FIGURE 3. On transthoracic echocardiography, the apical four-chamber view (left) shows apical hypertrophy. The subcostal four-chamber view (right) shows apical hypertrophy only at the left ventricular apex, with the classic “spade” sign visible in the left ventricle (LV).

REFERENCES

1. Eriksson MJ, Sonnenberg B, Woo A, et al. Long-term outcome in patients with apical hypertrophic cardiomyopathy. *J Am Coll Cardiol* 2002; 39:638–645.
2. Kasirye Y, Manne JR, Epperla N, Bapani S, Garcia-Montilla R. Apical hypertrophic cardiomyopathy presenting as recurrent unexplained syncope. *Clin Med Res* 2012; 10:26–31.
3. Lee CH, Liu PY, Lin LJ, Chen JH, Tsai LM. Clinical features and outcome of patients with apical hypertrophic cardiomyopathy in Taiwan. *Cardiology* 2006; 106:29–35.
4. Nishimura RA, Holmes DR Jr. Clinical practice. Hypertrophic obstructive cardiomyopathy. *N Engl J Med* 2004; 350:1320–1327.
5. Lin CS, Chen CH, Ding PY. Apical hypertrophic cardiomyopathy mimicking acute myocardial infarction. *Int J Cardiol* 1998; 64:305–307.

ADDRESS: Anthony M.-H. Ho, MD, FRCP, FCCP, Department of Anesthesiology and Perioperative Medicine, Victory 2, Kingston General Hospital, 76 Stuart Street, Kingston, ON, Canada, K7L 2V7; e-mail: hoamh@hotmail.com