

MICHAEL S. BENNINGER, MD

Chairman, Head and Neck Institute, Cleveland Clinic;
Professor of Surgery, Cleveland Clinic Lerner College
of Medicine of Case Western Reserve University

LIBBY J. SMITH, DO, FAOCO

Associate Professor, Department of Otolaryngology,
University of Pittsburgh School of Medicine UPMC
Voice Center, PA

Noncosmetic uses of botulinum toxin in otolaryngology

ABSTRACT

Botulinum toxin has several noncosmetic uses in otolaryngology. It is the primary treatment for spasmodic dysphonia and may be effective in select patients who have essential tremor of the voice. It may also be used to treat swallowing difficulties caused by cricopharyngeal dysfunction.

KEY POINTS

Botulinum toxin can be injected with a variety of approaches directly into the affected muscle exhibiting abnormal contractions.

Depending on the muscles involved, side effects may include breathiness or difficulty swallowing for a period soon after injection.

Injections can be repeated as needed as the toxin wears off.

Some conditions are more amenable to treatment than others. Benefit can be enhanced by altering the dosage or injection site.

BOTULINUM TOXIN is commonly used to treat movement disorders of the head and neck. It was first used to treat focal eye dystonia (blepharospasm) and laryngeal dystonia (spasmodic dysphonia) and is now also used for other head and neck dystonias, movement disorders, and muscle spasticity or contraction.

This article reviews the use of botulinum toxin for primary disorders of the laryngopharynx—adductor and abductor spasmodic dysphonias, laryngopharyngeal tremor, and cricopharyngeus muscle dysfunction—and its efficacy and side effects for the different conditions.

■ ABNORMAL MUSCLE MOVEMENT

Dystonia is abnormal muscle movement characterized by repetitive involuntary contractions. Dystonic contractions are described as either sustained (tonic) or spasmodic (clonic) and are typically induced by conscious action to move the muscle group.^{1,2} Dystonia can be categorized according to the amount of muscle involvement: generalized (widespread muscle activity), segmental (involving neighboring groups of muscles), or focal (involving only one or a few local small muscles).³ Activity may be associated with gross posturing and disfigurement, depending on the size and location of the muscle contractions, although the muscle action is usually normal during rest.

The cause of dystonia has been the focus of much debate and investigation. Some types of dystonia have strong family inheritance patterns, but most are sporadic, possibly brought on by trauma or infection. In most cases, dystonia is idiopathic, although it may be associated with other muscle group dystonias, tremor, neurologic injury or insults, other neurologic

doi:10.3949/ccjm.82a.14096

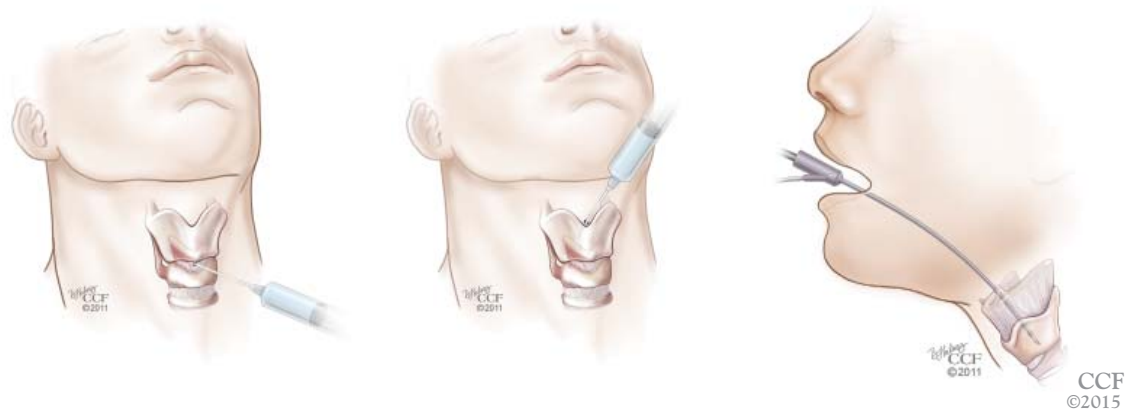

FIGURE 1. In the treatment of adductor spasmodic dysphonia, botulinum toxin is injected into the thyroarytenoid muscle via the cricothyroid membrane (left), the most common approach, as well as through the thyrohyoid membrane (middle) and through the mouth (right).

diseases and neurodegenerative disorders, or tardive syndromes.¹ Because of the relationship with other neurologic diseases, consultation with a neurologist should be considered.

Treatment of the muscle contractions of the various dystonias includes drug therapy and physical, occupational, and voice therapy. Botulinum toxin is a principal treatment for head and neck dystonias and works by blocking muscular contractions.⁴ It has the advantages of having few side effects and predictable results for many conditions, although repeat injections are usually required to achieve a sustained effect.

■ LARYNGEAL DYSTONIAS CAUSE VOICE ABNORMALITIES

The most common laryngeal dystonia is spasmodic dysphonia, a focal dystonia of the larynx. It is subdivided into two types according to whether spasm of the vocal folds occurs during adduction or abduction.

Adductor spasmodic dysphonia accounts for 80% to 90% of cases. It is characterized by irregular speech with pitch breaks and a strained or strangled voice. It was formerly treated by resection of the nerve to the vocal folds, but results were neither consistent nor persistent. Currently, the primary treatment is injection of botulinum toxin, which has a high success rate,⁵ with patients reporting about a 90% return of normal function.

Abductor spasmodic dysphonia accounts

for 10% to 20% of cases.⁶ Patients have a breathy quality to the voice with a short duration of vocalization due to excessive loss of air on phonation. This is especially noticeable when the patient speaks words that begin with a voiceless consonant followed by a vowel (eg, pat, puppy). Response to botulinum toxin injection is more variable,⁶ possibly because of the pathophysiology of the disorder or because of the technical challenges of administering the injection.

Fewer than 1% of patients have both abductor and adductor components, and their treatment can be particularly challenging.

Adductor spasmodic dysphonia: Treatment usually successful

Botulinum toxin can be injected for adductor spasmodic dysphonia via a number of approaches, the most common being through the cricothyroid membrane (**Figure 1**). Injections can be made into one or both vocal folds and can be performed under guidance with laryngeal electromyography or with a flexible laryngoscope to visualize the larynx.

Patients typically experience breathiness beginning 1 or 2 days after the injection, and this effect may last for up to 2 weeks. During that time, the patient may be more susceptible to aspiration of thin liquids and so is instructed to drink cautiously. Treatment benefits typically last for 3 to 6 months. As the botulinum toxin wears off, the patient notices a gradual increase in vocal straining and effort.

**Dystonia is
most often
idiopathic**

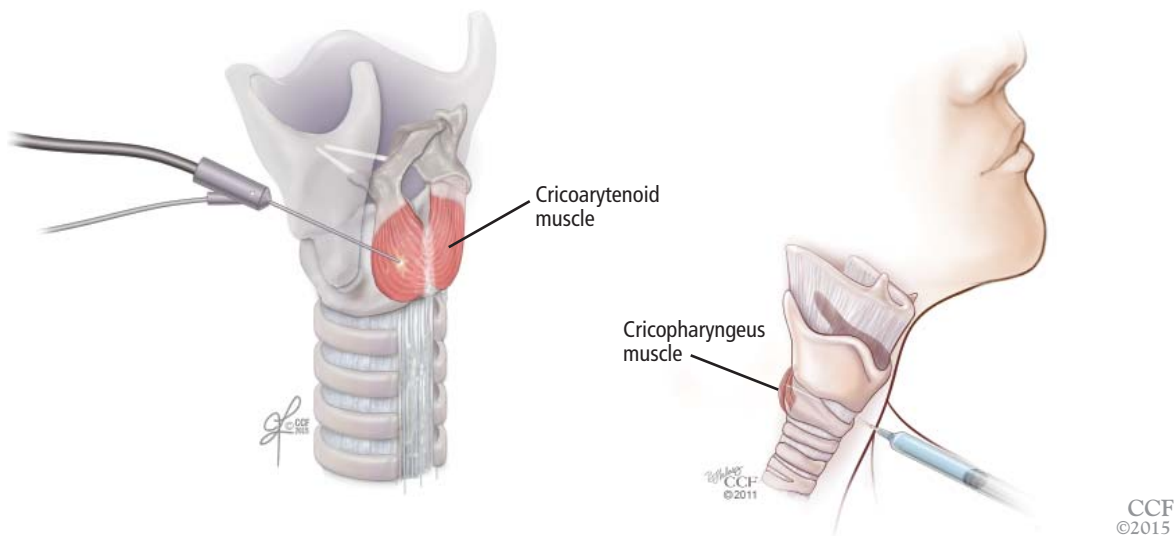


FIGURE 2. In the treatment of abductor spasmodic dysphonia (left), botulinum toxin is injected into the posterior cricoarytenoid muscle from the side. In the treatment of difficulty swallowing due to cricopharyngeus muscle dysfunction (right), botulinum toxin is injected directly into the cricopharyngeus muscle. This is most effective if done bilaterally.

Dosages of botulinum toxin for subsequent treatments are adjusted by balancing the period of benefit with postinjection breathiness. The desire of the patient should be paramount. Some are willing to tolerate more side effects to avoid frequent injections, so they can be given a larger dose. Others cannot tolerate the breathiness but are willing to accept more frequent injections, so they should be given a smaller dose. In rare cases, patients have significant breathiness from even small doses; they may be helped by injecting into only one vocal fold or, alternatively, into a false vocal fold, allowing diffusion of the toxin down to the muscle of the true vocal fold.

Abductor spasmodic dysphonia: Treatment more challenging

The success of botulinum toxin treatment for abductor spasmodic dysphonia is more variable than for the adductor type. The injections are made into the posterior cricoarytenoid muscle (**Figure 2**); because this muscle cannot be directly visualized, this procedure requires guidance with laryngeal electromyography. Most patients note improvement, and about 20% have a good response.⁶ Most require a second injection about 1 month later, often on the other side. Bilateral injections at one sitting may compromise the airway,

and vocal fold motion should be evaluated at the time of the contralateral injection to assess airway patency. Interest has increased in simultaneous bilateral injections with lower doses of botulinum toxin, and this approach has been shown to be safe.⁷

■ ESSENTIAL TREMOR OF THE VOICE

Essential tremor is an action tremor that can occur with voluntary movement. It can occur anywhere in the body, often the head or hand, but the voice can also be affected. About half of cases are hereditary. Essential tremor of the voice causes a rhythmic oscillation of pitch and intensity.

Consultation with a neurologist is recommended to evaluate the cause, although voice tremor is often idiopathic and occurs in about 30% of patients with essential tremor in the arms or legs, as well as in about 30% of patients with spasmodic dysphonia. Extremity tremor can usually be successfully managed medically, but this is not true for voice tremor.

Botulinum toxin injection is the mainstay of treatment for essential tremor of the voice, although its success is marginal. About two-thirds of patients have some degree of improvement from traditional botulinum toxin injections in the true vocal fold.⁸

Patients almost always require repeat injections to obtain a sustained effect

The results of treatment are likely to be inconsistent because tremor tends to involve several different muscles used in voice production, commonly in the soft palate, tongue base, pharyngeal walls, strap muscles, false vocal folds, and true vocal folds. A location-oriented tremor scoring system⁹ can help identify the involved muscles to guide injections. Treatment is less likely to be successful in patients with multiple sites of voice tremor. Injection into the false vocal fold, true vocal fold, and interarytenoid muscle¹⁰ can safely be performed; injections into the palate, tongue base, and strap muscles are to be avoided because of the high risk of postinjection aspiration.

Patients who have good results can have repeat treatments as needed. The dosage of botulinum toxin is adjusted according to response, side effects (eg, breathy voice, dysphagia), and patient preference.

■ CRICOPHARYNGEUS MUSCLE DYSFUNCTION: TROUBLE SWALLOWING

Dysfunction of the cricopharyngeus muscle causes difficulty swallowing, especially swallowing solid foods. It can be attributed to a mechanical stricture or to hyperfunction (spasm).

Mechanical stricture at the esophageal inlet frequently occurs in patients who have had a total laryngectomy for advanced laryngeal cancer. Fibrosis tends to be worse in patients who have also undergone radiation therapy.

Stricture can be treated with botulinum

toxin injections and dilation. Conservative treatment is preferred to surgical myotomy for patients with complex postlaryngectomy anatomy and scarring from radiation therapy.

Cricopharyngeus muscle spasm or hyperfunction can be an important cause of dysphagia, especially in the elderly. Patients should be evaluated with barium esophagography or a modified barium swallow. The finding of a cricopharyngeal "bar" provides evidence of contraction of the muscle that impedes the passage of food.

Botulinum toxin injections for cricopharyngeus muscle dysfunction (**Figure 2**) can be effective in some cases, especially if the toxin is injected bilaterally. However, because the cricopharyngeus muscle plays an important role in preventing esophageal reflux into the laryngopharynx, botulinum toxin injection in patients with substantial hiatal hernia or laryngopharyngeal reflux disease should only be done with caution. In addition, treatment of reflux disease should be considered in any patient undergoing botulinum toxin injection for cricopharyngeus muscle dysfunction.

Most patients require repeat injections when the toxin wears off, although occasionally one or two injections provide long-term or permanent relief. Dosages are adjusted for the patient's age, the presence of other swallowing problems, and reflux. Patients may experience increased difficulty swallowing for 1 or 2 weeks after the procedure and so should be counseled to eat slowly and carefully. ■

■ REFERENCES

1. Cultrara A, Chitkara A, Blitzer A. Botulinum toxin injections for the treatment of oromandibular dystonia. *Oper Tech Otolaryngol Head Neck Surg* 2004; 15:97–102.
2. Fahn S. The varied clinical expressions of dystonia. *Neurol Clin* 1984; 2:541–554.
3. Fahn S. Concept and classification of dystonia. *Adv Neurol* 1988; 50:1–8.
4. Benninger MS, Knott PD. Techniques of botulinum toxin injections in the head and neck. San Diego, CA: Plural Publishing, Inc; 2012.
5. Benninger MS, Gardner G, Grywalski C. Outcomes of botulinum toxin treatment for spasmodic dysphonia. *Arch Otolaryngol Head Neck Surg* 2001; 127:1083–1085.
6. Blitzer A, Brin MF, Stewart CF. Botulinum toxin management of spasmodic dysphonia (laryngeal dystonia): a 12-year experience in more than 900 patients. *Laryngoscope* 1998; 108:1435–1441.
7. Klein AM, Stong BC, Wise J, DelGaudio JM, Hapner ER, Johns MM 3rd. Vocal outcome measures after bilateral posterior cricoarytenoid muscle botulinum toxin injections for abductor spasmodic dysphonia. *Otolaryngol Head Neck Surg* 2008; 139:421–423.
8. Hertegård S, Granqvist S, Lindestad PA. Botulinum toxin injections for essential voice tremor. *Ann Otol Rhinol Laryngol* 2000; 109:204–209.
9. Bové M, Daamen N, Rosen C, Wang CC, Sulica L, Gartner-Schmidt J. Development and validation of the vocal tremor scoring system. *Laryngoscope* 2006; 116:1662–1667.
10. Kendall KA, Leonard RJ. Interarytenoid muscle Botox injection for treatment of adductor spasmodic dysphonia with vocal tremor. *J Voice* 2001; 25:114–119.

ADDRESS: Michael S. Benninger, MD, Head and Neck Institute, A71, Cleveland Clinic, 9500 Euclid Avenue, Cleveland, OH 44195; e-mail: benninm@ccf.org

Treatment benefits typically last for 3 to 6 months in adductor spasmodic dysphonia