

TABLE OF CONTENTS

FROM THE EDITOR

Diagnostic uncertainty and the eosinophil **72**

Eosinophilic esophagitis can mimic gastroesophageal reflux disease, especially early in its course.

B.F. MANDELL

COMMENTARY

The health care 'iron triangle' and the Patient Protection and Affordable Care Act **73**

There is no way to increase access, improve quality, and decrease costs all at the same time.

E.P. LEHMAN IV

THE CLINICAL PICTURE

Syncope from a twiddled ICD **81**

A patient playing ("twiddling") with his or her implanted cardioverter-defibrillator can dislodge the lead.

F. ADHI, G. SINGH, W. TSUANG, AND E. MIRELES-CABODEVILA



MEDICAL GRAND ROUNDS

The 'skinny' on eosinophilic esophagitis **83**

Often starting in childhood, this disease progresses until the esophagus is visibly narrowed on radiography.

D.A. KATZKA

1-MINUTE CONSULT

Should patients stop taking aspirin for primary prevention? **91**

In view of the evidence, routine use of aspirin for primary prevention is not recommended, even in patients with diabetes.

J.P. DEPTA AND D.L. BHATT

CONTINUED ON PAGE 71



Online Features

Access

Cleveland Clinic Journal of Medicine content is readily available to all and is free of charge at www.ccjm.org.

On your first visit, we will ask you to take a few minutes to register, but subsequent visits will be unencumbered except for an occasional request for your e-mail address when you visit using another device (eg, mobile phone, tablet).

Services

- Navigate quickly to articles in current and past issues via links on the home page and pull-down menus at the top of the page. Use the search function to find a specific article, or browse by topic or article type.

- Continuing medical education activities are accessible from article links and from a CME pull-down menu on the home page. Participation is free.

- Follow links on the home page to news, summaries of recent scientific meetings, and interactive quizzes.

- Click on the PDF symbol at the top of any online article to read, download, or print the article in PDF format.

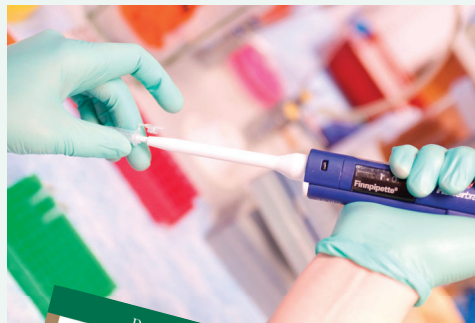Social Networking

To post a *CCJM* article to Facebook or Twitter, just click on the icon at the top of any online article.

www.ccjm.org

Upcoming Features

- Marijuana goes mainstream: Should we worry?
- Appendage closure for atrial fibrillation
- Bye-bye, Papanicolaou: HPV-only screening
- Subarachnoid hemorrhage: Management takes a team
- Mammograms at age 40–50: Helpful or harmful?
- Is triglyceride therapy worth the effort?
- When O₂ saturation trumps arterial blood gas
- Managing medications during transitions of care
- Targeted therapies for psoriasis, melanoma, basal cell carcinoma



DEDICATED TO LIFELONG LEARNING
CLEVELAND CLINIC JOURNAL OF MEDICINE

FEBRUARY 2015

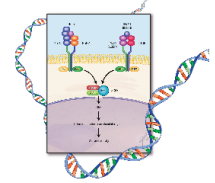
CONTINUED FROM PAGE 70

REVIEW 97

Genetics and hepatitis C: It's good to be 'CC'

In hepatitis C, people born with the *IL28B* CC genotype can count themselves luckier than those born with CT or TT.

J. MARI PARUNGAO, I.A. HANOUNEH, B. JOHN, N. ALKHOURI, AND N.N. ZEIN



CURRENT DRUG THERAPY 105

Denosumab: A novel antiresorptive drug for osteoporosis

What denosumab is, how it works, how well it works, and practical prescribing tips.

E. SURESH AND B. ABRAHAMSEN

REVIEW 115

Cystic lung disease: Systematic, stepwise diagnosis

One can arrive at the likely diagnosis in most cases on the basis of the clinical and radiographic features.

D. HA, R. YADAV, AND P.J. MAZZONE

DEPARTMENTS 128

CME Calendar

Corrections 114

Directions for CME

Inside back cover

To receive CME credit, read any or all of the CME-certified articles in this issue (those that carry the CME logo), then click on the CME link at www.ccm.org to access the test for the article or articles you select. It should take up to 1 hour to complete the activity for each article.

Release date: February 1, 2015

Expiration date: January 31, 2016