

Online Features

Access

Cleveland Clinic Journal of Medicine content is readily available to all and is free of charge at www.ccm.org. On your first visit, we will ask you to take a few minutes to register, but subsequent visits will be unencumbered except for an occasional request for your e-mail address when you visit using another device (eg, mobile phone, tablet).

Services

- Navigate quickly to articles in current and past issues via links on the home page and pull-down menus at the top of the page. Use the search function to find a specific article, or browse by topic or article type.
- Continuing medical education activities are accessible from article links and from a CME pull-down menu on the home page. Participation is free.
- Follow links on the home page to news, summaries of recent scientific meetings, and interactive quizzes.
- Click on the PDF symbol at the top of any online article to read, download, or print the article in PDF format.

Social Networking

To post a *CCJM* article to Facebook or Twitter, just click on the icon at the top of any online article.

www.ccm.org

MAY 2015

TABLE OF CONTENTS

FROM THE EDITOR	
Pericarditis as a window into the mind of the internist	266
In looking for an underlying cause, we need to be thorough but also contain costs and avoid harm from overtesting.	
B.F. MANDELL	
THE CLINICAL PICTURE	
A lump in the umbilicus	270
An estimated 1% to 3% of patients with cancer in the abdomen or pelvis present with a nodule in the umbilicus.	
H. MIRFAZALIAN, A. MOSALEI, S. NEGAHBAN, A. ALEDAVOOD, AND Y. DANESHBOD	
POINT AND COUNTERPOINT	
Annual mammography starting at age 40: More talk, less action?	272
In view of the potential harm, we question annual screening starting at age 40.	
P. BATUR AND J.M.E. WALSH	
POINT AND COUNTERPOINT	
Screening mammography starting at age 40: Still relevant	276
In women in their 40s, the incidence of breast cancer is low but the risk of a tumor being aggressive is especially high.	
K. GHOSH, D. WAHNER-ROEDLER, AND K. BRANDT	
THE CLINICAL PICTURE	
Light-headedness and bradycardia in a 72-year-old woman	280
Complete heart block is a form of atrioventricular (AV) dissociation, but not all AV dissociation is complete heart block.	
B. PATEL, C. WIEMANN, AND D.P. SHAH	
THE CLINICAL PICTURE	
Morphea-like plaques, induration of the extremities, and eosinophilia	283
Eosinophilic fasciitis is suspected in a patient with eosinophilia and characteristic cutaneous features.	
C. MAGRO-CHECA, J. ORGAZ-MOLINA, S.R. LAFÈBRE, J.L. ROSALES-ALEXANDER, S. ARIAS-SANTIAGO, AND E. RAYA	

CONTINUED ON PAGE 264

CONTINUED FROM PAGE 263

1-MINUTE CONSULT

When does pericarditis merit a workup for autoimmune or inflammatory disease? 285

Further evaluation is required for recurrent pericarditis resistant to conventional therapy or for manifestations of systemic disease.

M.C. ALRAIES, M. BAIBARS, AND A.L. KLEIN

IM BOARD REVIEW

A 79-year-old with acute portal vein thrombosis 287

The patient, who had a history of polymyalgia rheumatica treated with corticosteroids, presented with chills and fever.

L. ZHU, H. GORNIK, AND J.H. ISAACSON

CME CREDIT REVIEW

Penicillin allergy: A practical guide for clinicians 295

Clinical presentation is key in classifying reactions as either mediated by immunoglobulin E or not.

A. GONZALEZ-ESTRADA AND C. RADOJICIC

CME CREDIT REVIEW

Stand by me! Reducing the risk of injurious falls in older adults 301

Practitioners can reduce falls by yearly screening and evidence-based interventions.

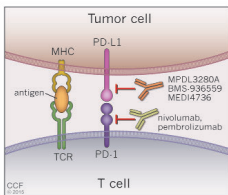
L. BEEGAN AND B.J. MESSINGER-RAPPORT

CME CREDIT MEDICAL GRAND ROUNDS

Dermatology update: The dawn of targeted treatment 309

New, targeted therapies are changing the way advanced basal cell carcinoma, psoriasis, and metastatic melanoma are treated.

A.P. FERNANDEZ



DEPARTMENTS

CME Calendar 267

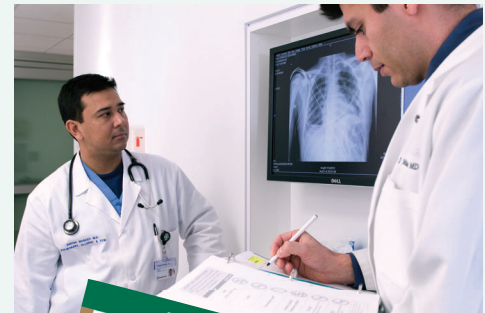Letters to the Editor 268

Readers comment on warfarin pharmacogenomics (August 2013).

CME Directions Inside back cover

Upcoming Features

- Marijuana goes mainstream: Should we worry?
- HIV: A disease of the elderly
- Managing medications during transitions of care
- Not all ST elevation is myocardial infarction
- Long-term problems of liver transplant recipients
- Vaccinations in special populations
- E-cigarettes: Gateway drug or nicotine replacement?
- Ceftaroline: A beta-lactam with anti-MRSA activity
- Botulinum toxin injection for urologic conditions



DEDICATED TO LIFELONG LEARNING
CLEVELAND CLINIC JOURNAL OF MEDICINE