

THE CLINICAL PICTURE

BRIJESH PATEL, DO

Department of Internal Medicine,
Providence Hospital and Medical Center,
Southfield, MI

CHARLOTTE WIEMANN, MD

Department of Internal Medicine,
Providence Hospital and Medical Center,
Southfield, MI

DIPAK P. SHAH, MD

Department of Cardiology,
Electrophysiology Section,
Providence Hospital and Medical Center,
Southfield, MI

Light-headedness and bradycardia in a 72-year-old woman

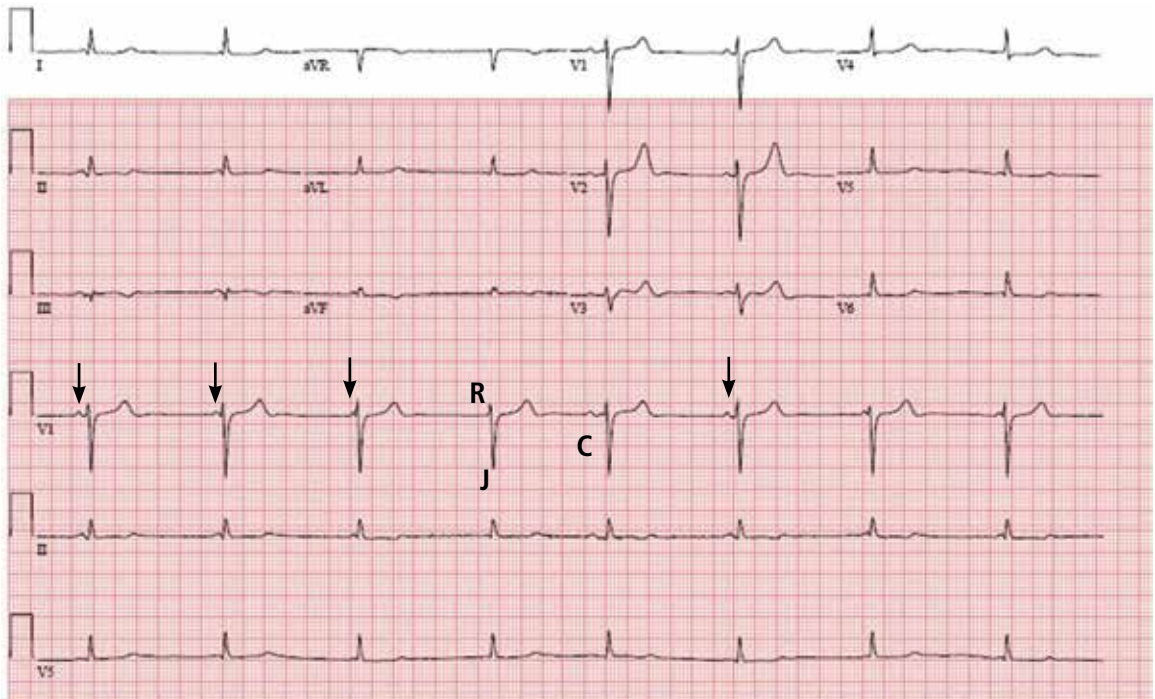


FIGURE 1. The initial electrocardiogram shows interference dissociation with an underlying junctional rhythm. The atrial rate (arrows refer to P waves) is approximately 46 bpm, and the ventricular rate is 48 bpm. The letter "R" denotes a P wave in the refractory period caused by the junction impulse "J." The letter "C" denotes a presumably normal conducted impulse (or captured beat). The corrected QT interval is 428 msec.

A 72-YEAR-OLD WOMAN came to the emergency department because of persistent light-headedness. Her medical history included end-stage renal disease, hypertension, peripheral vascular disease, and diabetes mellitus. She said she had experienced similar symptoms before, but they had gone away.

She reported no visual changes, no loss of consciousness, and no history of seizures, syncope, chest pain, palpitations, or diaphoresis. She was not taking a beta-blocker, calcium channel blocker, or digoxin.

doi:10.3949/ccjm.82a.14019

Her blood pressure was 75/44 mm Hg, heart rate 44 beats per minute, respiratory rate 16 breaths per minute, and oxygen saturation 97% while receiving oxygen at 3 L per minute. An electrolyte panel was normal except for an elevated creatinine level secondary to end-stage renal disease.

In view of her symptoms and bradycardia, she was admitted to the hospital. The initial electrocardiogram (FIGURE 1) showed an atrial rate of approximately 46 beats per minute, a ventricular rate of approximately 48 beats per minute, and a P wave in the refractory

period caused by a junction impulse.

These findings pointed to atrioventricular (AV) dissociation, a term commonly applied to arrhythmias in which the atria and ventricles are rhythmically detached.

■ ATRIOVENTRICULAR DISSOCIATION

AV dissociation is often used interchangeably with complete heart block, but this is incorrect¹; though complete heart block is a form of AV dissociation, not all AV dissociation is complete heart block. In complete heart block, there is no rhythmic relationship between the atria and ventricles, as they beat independently with no influence on each other. On the other hand, when a “blockade” is created by the physiologic refractory period of the atria (sinus node or atrial ectopic focus) and ventricles, *interference dissociation* can result.² In this condition, when the ventricles are not in a refractory period, an atrial impulse may be conducted through the AV node, resulting in an atrial-driven beat. Simply put, a P wave has the potential to be conducted in AV dissociation if there is an opportunity, but in complete heart block it does not.¹

AV dissociation is a secondary manifestation of a primary disorder or rhythm disturbance. In general, any rhythm that competes against an atrial impulse and inhibits its conduction through the AV node can cause AV dissociation. Common examples include junctional escape or accelerated rhythms, premature ventricular beats or ventricular tachycardia, and accelerated idioventricular rhythms. It also can be caused by drugs (eg, digoxin) or an increase in vagal tone.²

In normal myocardium, the sinus node has a higher impulse rate than the subordinate pacemaker (AV node or ventricular pacemaker). Generally, the atrial rate is higher than the ventricular rate in complete heart block, whereas in AV dissociation the ventricular rate is higher than the atrial rate.³

Thus, AV dissociation can result from one of the following mechanisms⁴:

- Slowing of the dominant pacemaker (sinus or atrial pacemaker)
- Acceleration or overtaking of the sinus node (or atrial focus) by a subordinate pacemaker (eg, a junctional or ventricular pacemaker)

- A block within the AV node that prevents an impulse generated by the dominant pacemaker (sinus or atrial focus) from crossing the AV node
- A combination of these mechanisms.

Another form of AV dissociation is isorhythmic dissociation. In this subtype, atrial and ventricular impulses occur at the same rate. This type of dissociation is most commonly confused with third-degree (or complete) heart block. It may be difficult to distinguish one from the other, but at higher sinus (or atrial) rates the difference becomes obvious—properly timed P waves may be conducted through the AV node in isorhythmic dissociation.¹

The prevalence of AV dissociation is thought to be 0.48% to 0.68%,³ but it could be more common since it is underdiagnosed.⁵

Treatment should be directed at the primary disorder.⁴ The need for a pacemaker depends on the condition causing the AV dissociation. In conditions that slow the sinus node, such as increased vagal tone, patients may benefit from medications that decrease parasympathetic activity or increase adrenergic activity in the AV node (eg, isoproterenol, atropine).⁶

■ OUR PATIENT

Our patient’s electrocardiogram showed interference dissociation from competing junctional rhythms. Possibly, she had sinus node disease, explaining why the sinus node was not the dominant pacemaker. She had symptomatic hypotension, requiring dopamine for pressure support. She was started on intravenous isoproterenol, which eventually restored sinus rhythm.

During the same hospitalization, she was diagnosed with osteomyelitis of the left foot, without bacteremia. She was treated for her infection and later received a pacemaker. She was discharged to a rehabilitation facility.

■ TAKE-AWAY POINTS

- When an occasional impulse is conducted through the AV node, AV dissociation is most likely interference dissociation.
- AV dissociations are often confused with complete heart block.

In AV dissociation, the ventricular rate is higher than the atrial rate

- In AV dissociation, the ventricular rate is higher than the atrial rate.
- Complete heart block is a form of AV dissociation, but not all AV dissociation is complete heart block.
- AV dissociation can be caused by three main mechanisms or by a combination of them.
- AV dissociation is secondary to a primary rhythm disorder.
- Adrenergic drugs may help to correct the AV dissociation, but not always completely.

REFERENCES

1. **Goldberger AL.** Atrioventricular conduction abnormalities: delays, blocks, and dissociation syndromes. In: Goldberger AL, Goldberger ZD, Shvilkin A, eds. *Clinical Electrocardiography: A Simplified Approach*. 8th ed. Philadelphia, PA: Elsevier/Saunders; 2012:159–169.
2. **Wang K, Benditt DG.** AV dissociation, an inevitable response. *Ann Noninvasive Electrocardiol* 2011; 16:227–231.
3. **Harrigan RA, Perron AD, Brady WJ.** Atrioventricular dissociation. *Am J Emerg Med* 2001; 19:218–222.
4. **Jeffrey O, Zipes DP.** Specific arrhythmias: diagnosis and treatment. In: Bonow RO, Mann DL, Zipes DP, Libby P, eds. *Braunwald's Heart Disease: A Textbook of Cardiovascular Medicine*. 9th ed. Philadelphia, PA: Elsevier/Saunders; 2011.
5. **Singh GD, Wong GB, Southard JA, Amsterdam EA.** Food for thought: atrioventricular dissociation. *Am J Med* 2013; 126:1050–1053.
6. **Vavetsi S, Nikolaou N, Tsarouhas K, et al.** Consecutive administration of atropine and isoproterenol for the evaluation of asymptomatic sinus bradycardia. *Europace* 2008; 10:1176–1181.

.....
ADDRESS: Brijesh Patel, DO, Department of Internal Medicine, Providence Hospital and Medical Center, 16001 W. Nine Mile Road, Southfield, MI 48075; e-mail b2patel@gmail.com