

## Online Features

### Access

*Cleveland Clinic Journal of Medicine* content is readily available to all and is free of charge at [www.ccmj.org](http://www.ccmj.org). On your first visit, we will ask you to take a few minutes to register, but subsequent visits will be unencumbered except for an occasional request for your e-mail address when you visit using another device (eg, mobile phone, tablet).

### Services

- Navigate quickly to articles in current and past issues via links on the home page and pull-down menus at the top of the page. Use the search function to find a specific article, or browse by topic or article type.
- Continuing medical education activities are accessible from article links and from a CME pull-down menu on the home page. Participation is free.
- Follow links on the home page to news, summaries of recent scientific meetings, and interactive quizzes.
- Click on the PDF symbol at the top of any online article to read, download, or print the article in PDF format.

### Social Networking

To post a *CCJM* article to Facebook or Twitter, just click on the icon at the top of any online article.

[www.ccmj.org](http://www.ccmj.org)

JULY 2015

## TABLE OF CONTENTS

### FROM THE EDITOR .....

**The cohabitation of art and genomic science 394**  
Genomic-based dosing of azathioprine makes scientific sense, but is it truly a clinical game-changer?

B.F. MANDELL

### THE CLINICAL PICTURE.....

**Electrocardiographic changes in amitriptyline overdose 396**

A 49-year-old woman was unresponsive after taking an unknown quantity of amitriptyline.

F. MBUVAH, F. PETROSYAN, N. THIRUCHELVAM, AND G. KISTANGARI

### THE CLINICAL PICTURE.....

**Umbilical hernia in a patient with cirrhosis 404**

Ascites is the major predisposing factor, since it causes muscle wasting and increases intra-abdominal pressure.

P. MARTENS AND W. LALEMAN

### THE CLINICAL PICTURE.....

**An unusual cause of vitamin B<sub>12</sub> and iron deficiency 406**

Testing for ova and parasites was negative, but video capsule endoscopy revealed a tapeworm in the distal duodenum.

S. MAITHEL, A.K. DUONG, J. ZHANG, AND D.L. NGUYEN

### 1-MINUTE CONSULT .....

**Should thiopurine methyltransferase (TPMT) activity be determined before prescribing azathioprine, mercaptopurine, or thioguanine? 409**

Testing can identify patients at risk of life-threatening myelosuppression on these drugs.

J. DIPIERO, K. TENG, AND J.K. HICKS

### CARDIOVASCULAR BOARD REVIEW.....

**A continuous cardiac murmur 414**

A 45-year-old woman presents with progressive shortness of breath and a continuous murmur over the entire precordium.

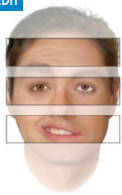R. NAPIER, J.D. GARDNER, S. NOE, AND J.B. CALKINS JR.

CONTINUED ON PAGE 392

CONTINUED FROM PAGE 391



**REVIEW** .....



**Bell palsy:  
Clinical examination and management** **419**

Bell palsy is characterized by acute facial mononeuropathy of unclear cause presenting with unilateral facial weakness.

D.K. PATEL AND K.H. LEVIN



**REVIEW** .....

**Cannabinoid hyperemesis syndrome:  
Marijuana is both antiemetic and proemetic** **429**

Chronic marijuana use can have an emetic effect. Patients shower or bathe in extremely hot water to relieve the symptoms.

M.L.R.Y. LU AND M.D. AGITO



**CURRENT DRUG THERAPY** .....

**Ceftaroline fosamil:  
A super-cephalosporin?** **437**

Ceftaroline fosamil is the first beta-lactam with clinically useful activity against methicillin-resistant *Staphylococcus aureus*.

R.J. GHAMRAWI, E. NEUNER, AND S.J. REHM



**REVIEW** .....

**Care of the aging HIV patient** **445**

Today, more than 50% of all HIV-infected people in the United States are over age 50.

J.M. BLAYLOCK AND G.W. WORTMANN

**REVIEW** .....

**Urologic applications of botulinum toxin** **456**

Botulinum toxin is approved for neurogenic detrusor overactivity and overactive bladder refractory to drug therapy.

A. KING, A. QUIROUET, AND C.K. MOORE

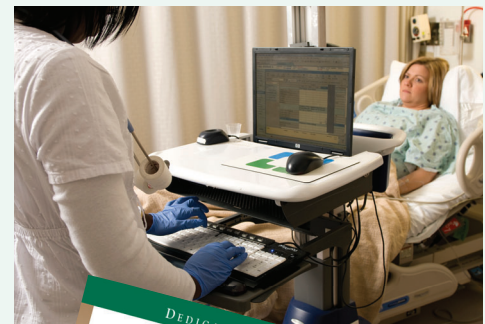
**DEPARTMENTS** .....

**CME Calendar** **428**

**CME Directions** **Inside back cover**

# Upcoming Features

- E-cigarettes: Nicotine replacement or gateway drug?
- When COPD or asthma and sleep apnea overlap
- ABCs of GERD: Treating the burn
- Should renal artery stenosis be stented?
- When should insulin be started in type 2 diabetes?
- Wound malodor deserves treatment
- Thiazides: Still useful, not the same
- Mild cognitive impairment: What can we offer?
- A new family of heart failure drugs



DEDICATED TO LIFELONG LEARNING  
**CLEVELAND  
 CLINIC  
 JOURNAL OF  
 MEDICINE**