

TABLE OF CONTENTS

FROM THE EDITOR

Perioperative MI: Data, practice, and questions **552**

What should be done when an elevated troponin is detected in a postoperative patient who is otherwise doing perfectly well?

B.F. MANDELL

MEDICAL GRAND ROUNDS

2015 Update on Parkinson disease **563**

An improved understanding of the disease is leading to new diagnostic tools and treatments.

H.H. FERNANDEZ

1-MINUTE CONSULT

What is the difference between palliative care and hospice care? **569**

The two have different indications and goals and are often provided in different settings.

M.P. DAVIS, T. GUTGSELL, AND P. GAMIER

THE CLINICAL PICTURE

Occult satellite metastasis of an auricular melanoma **577**

Satellite lesions are a sign of aggressive disease and require a thorough evaluation for metastases.

P. KOLTSIDPOULOS AND C. SKOULAKIS

THE CLINICAL PICTURE

Herpes zoster triplex **579**

A 77-year-old man presented with painful eruptions on the left chest, right lower groin, and left thigh.

S. TAKASHIMA AND M. OTA

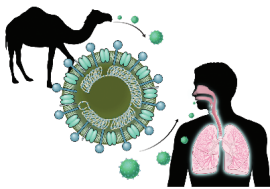
REVIEW



Middle East respiratory syndrome: SARS redux? **584**

Prompt identification and isolation of infected patients is critical to limiting the spread of infection.

G. WORTMANN



CONTINUED ON PAGE 551

Online Features

Access

Cleveland Clinic Journal of Medicine content is readily available to all and is free of charge at www.ccmj.org. On your first visit, we will ask you to take a few minutes to register, but subsequent visits will be unencumbered except for an occasional request for your e-mail address when you visit using another device (eg, mobile phone, tablet).

Services

- Navigate quickly to articles in current and past issues via links on the home page and pull-down menus at the top of the page. Use the search function to find a specific article, or browse by topic or article type.
- Continuing medical education activities are accessible from article links and from a CME pull-down menu on the home page. Participation is free.
- Follow links on the home page to news, summaries of recent scientific meetings, and interactive quizzes.
- Click on the PDF symbol at the top of any online article to read, download, or print the article in PDF format.

Social Networking

To post a *CCJM* article to Facebook or Twitter, just click on the icon at the top of any online article.

www.ccmj.org

Upcoming Features

- A new drug class for heart failure
- GERD: Diagnosing, treating the burn
- Malpractice: A defense attorney's perspective
- When COPD or asthma and sleep apnea overlap
- Recognizing, treating alcohol withdrawal syndrome
- Advances in treating dyslipidemia
- Most preoperative testing is unnecessary
- Contraception: Don't be the barrier
- Recreational marijuana use: How benign?



DEDICATED TO LIFELONG LEARNING
**CLEVELAND
 CLINIC
 JOURNAL OF
 MEDICINE**

SEPTEMBER 2015

CONTINUED FROM PAGE 550

REVIEW

Troponin elevation after noncardiac surgery: Significance and management 595



Patients with elevations are at higher risk of morbidity and death, but current guidelines provide few recommendations.

S. HERR, G. REED, AND V. MENON

EDITORIAL

Postoperative troponin surveillance: A diagnostic dilemma 603

Postoperative troponin elevations are linked to bad outcomes. But does screening for troponin elevations improve outcomes?

S.L. COHN

IM BOARD REVIEW

Ankle pain in a young woman with Gaucher disease 607

Gaucher disease causes hepatomegaly, splenomegaly, bone marrow disease, bone pain, bone infarcts, and lytic lesions.

A.J. KATTOOR, T.W. BAUER, M. BERKOWITZ, J.M. POLSTER, AND A.E. LICHTIN

REVIEW

Lactic acidosis: Clinical implications and management strategies 615



In hospitalized patients, elevated lactate is both a marker of risk and a target of therapy.

A.J. REDDY, S.W. LAM, S.R. BAUER, AND J.A. GUZMAN

DEPARTMENTS

CME Calendar 554

Letters to the Editor 555

Readers comment on obstructive sleep apnea (August 2014) and on writing better consult notes (January 2015).

CME Test Directions Inside back cover