

THE CLINICAL PICTURE

SOUMYA CHATTERJEE, MD, MS, FRCP

Associate Professor of Medicine, Cleveland Clinic Lerner College of Medicine of Case Western Reserve University, Cleveland, OH, and Staff, Department of Rheumatologic and Immunologic Diseases, Orthopaedic and Rheumatologic Institute, Cleveland Clinic

Bony bumps in the mouth

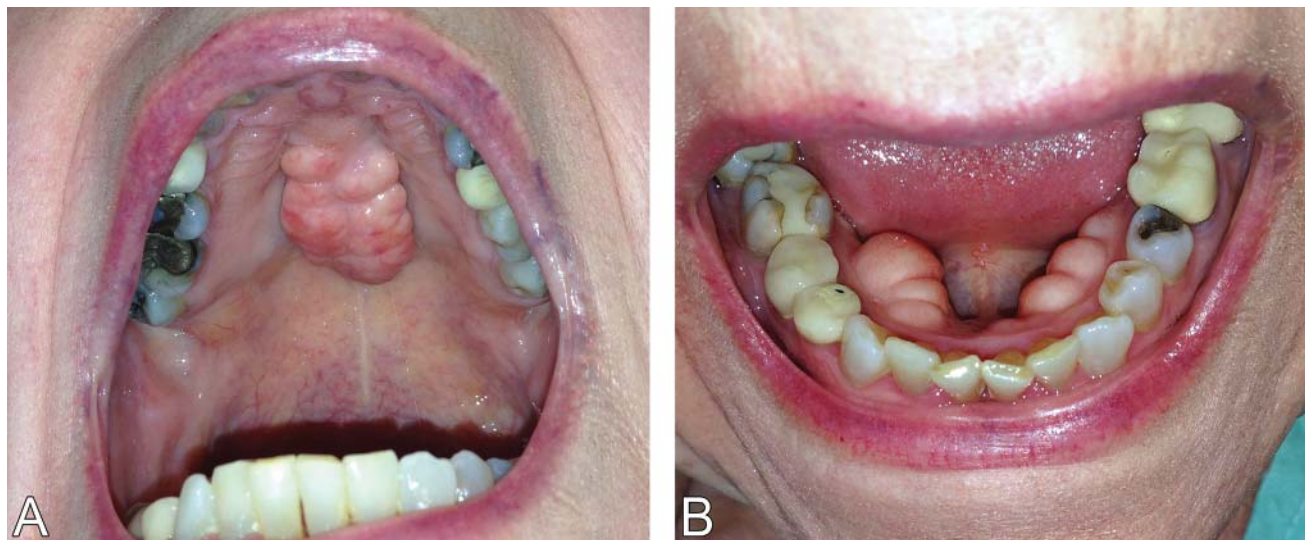


FIGURE 1. Torus palatinus (left) is an exostosis arising from the median raphe of the palatine bone, whereas torus mandibularis (right) arises in the premolar area of the lingual surface of the mandible. These bony excrescences are benign, are usually asymptomatic, and require no treatment.

A 79-YEAR-OLD WOMAN with a long history of limited scleroderma was being evaluated in the rheumatology clinic. During routine examination of the oral cavity, masses were noted on her hard palate and on the lingual surface of both sides of the mandible (**Figure 1**). The masses had a bony consistency. The patient said that she had had these lumps for as long as she could remember, and that they were painless and had never caused any discomfort.

The masses were diagnosed as torus palatinus and torus mandibularis, localized benign overgrowths of cortical bone. The patient was reassured about the benign nature of these masses, and as they were asymptomatic, no further action was considered necessary.

■ TORUS PALATINUS AND TORUS MANDIBULARIS

Torus palatinus and torus mandibularis are common exostoses of the mouth, ie, localized benign bony overgrowths arising from cortical bone.¹ They are occasionally found incidentally during routine examination of the oral cavity. Patients should be reassured about the nonpathologic nature of this condition.

The condition is thought to be multifactorial, with causal factors including autosomal dominant inheritance, trauma, and lifestyle factors² such as vitamin deficiency,³ a calcium-rich diet,³ fish consumption,^{4,5} and chewing on dry, raw, or frozen meat (as in Eskimo cultures).³ Masticatory hyperfunction and bruxism are thought to be risk factors.^{2,3}

Epidemiologic studies indicate that oral tori are more common in women, and the prevalence varies considerably between geo-

doi:10.3949/ccjm.83a.15033

graphic areas and ethnic groups.³ It is more common in Native Americans, Eskimos, Norwegians, and Thais.⁴

Torus palatinus is the most prevalent oral torus, occurring in 20% of the US population.⁶ It arises from the median raphe of the palatine bone and can vary in shape and size. Torus mandibularis is a protuberance arising in the premolar area of the lingual surface of the mandible.³ This form is much less common than torus palatinus, with a prevalence of 6%, and is bilateral in about 80% of cases.

Microscopic examination of tori reveal a mass of dense, lamellar, cortical bone with a small amount of fibrofatty marrow.¹ An inner zone of trabecular bone may also be present.¹

■ DIFFERENTIAL DIAGNOSIS

Oral tori must be differentiated from other growths in the mouth including fibromas, mucocles, osteomas, osteochondromas, and osteoid osteomas.⁴ However, oral tori can usually be distinguished from other conditions on the basis of clinical findings alone. Biopsy may be warranted if there is doubt.⁴

Tori tend to grow gradually throughout life and do not have potential for malignant transformation.⁴ Although they are typically asymptomatic, removal is sometimes warranted for proper fitting of prostheses or for use in autogenous cortical bone grafting.⁵ ■

■ REFERENCES

1. Neville BW, Douglas DD, Carl MA, Bouquot J. Developmental defects of the oral and maxillofacial region. In: Neville BW, Douglas DD, Carl MA, Bouquot J, eds. *Oral and Maxillofacial Pathology*. 3rd ed. St. Louis, MO: WB Saunders; 2009:1–53.
2. Eggen S. Torus mandibularis: an estimation of the degree of genetic determination. *Acta Odontol Scand* 1989; 47:409–415.
3. Loukas M, Hulsberg P, Tubbs RS, et al. The tori of the mouth and ear: a review. *Clin Anat* 2013; 26:953–960.
4. Ladizinski B, Lee KC. A nodular protuberance on the hard palate. *JAMA* 2014; 311:1558–1559.
5. García-García AS, Martínez-González JM, Gómez-Font R, Soto-Rivadeneira A, Oviedo-Roldán L. Current status of the torus palatinus and torus mandibularis. *Med Oral Patol Oral Cir Bucal* 2010; 15:e353–e360.
6. Larheim TA, Westesson PL. Facial growth disturbances. In: *Maxillofacial Imaging*. Berlin/Heidelberg: Springer-Verlag, 2008:231.

ADDRESS: Soumya Chatterjee, MD, MS, FRCP, Department of Rheumatologic and Immunologic Diseases, A50, Cleveland Clinic, 9500 Euclid Avenue, Cleveland, OH 44195; e-mail: chattes@ccf.org

Removal may be warranted for proper fitting of prostheses or for use in autogenous cortical bone grafting