

TABLE OF CONTENTS

FROM THE EDITOR

There may be zebras running with the horses **697**
 Common diseases are indeed common, but patients with less-common ones do find their way into our practices.

B.F. MANDELL

THE CLINICAL PICTURE.....

Air leakage in multiple compartments after endoscopy **705**
 An attempt to cannulate the common bile duct led to abdominal pain and distention and crepitus of the right chest wall.

A. GRIPPEN GODDARD, B. McCONOMY, G. BATHLA, M. FURQAN, AND W.B. SILVERMAN

THE CLINICAL PICTURE.....

Concurrent uvulitis and epiglottitis **712**
 A 66-year-old woman presented with fever, cough, odynophagia, and anterior neck pain.


W. SHOMALI AND K. HOLMAN

THE CLINICAL PICTURE.....

Eruptive xanthoma: Warning sign of systemic disease **715**
 Initial laboratory testing showed a triglyceride level of 5,742 mg/dL.


G. ROGA AND M. JITHENDRIYA

REVIEW

 **Update in perioperative cardiac medicine** **723**
 Risk assessment, risk reduction, antiplatelet therapy after stent placement, and bridging anticoagulation.

S.L. COHN, S. DUTTA, B.A. SLAWSKI, P.J. GRANT, AND G.W. SMETANA

REVIEW

 **Skin findings associated with nutritional deficiencies** **731**
 Reviewing the dermatologic effects of deficiencies of zinc and vitamins A, B₂, B₃, B₆, and C.

F. GALIMBERTI AND N.A. MESINKOVSKA

CONTINUED ON PAGE 696



Online Features

Access

Cleveland Clinic Journal of Medicine content is readily available to all and is free of charge at www.ccjm.org. On your first visit, we will ask you to take a few minutes to register, but subsequent visits will be unencumbered except for an occasional request for your e-mail address when you visit using another device (eg, mobile phone, tablet).

Services

- Navigate quickly to articles in current and past issues via links on the home page and pull-down menus at the top of the page. Use the search function to find a specific article, or browse by topic or article type.
- Continuing medical education activities are accessible from article links and from a CME pull-down menu on the home page. Participation is free.
- Follow links on the home page to news, summaries of recent scientific meetings, and interactive quizzes.
- Click on the PDF symbol at the top of any online article to read, download, or print the article in PDF format.

Social Networking

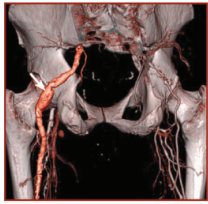
To post a *CCJM* article to Facebook or Twitter, just click on the icon at the top of any online article.

www.ccjm.org

CONTINUED FROM PAGE 694



REVIEW



Nonatherosclerotic limb ischemia: Prompt evaluation and diagnosis 741

Symptoms of ischemia may be difficult to recognize in younger patients, thus delaying diagnosis.

J.C. EUN, W.R. HIATT, AND N.O. GLEBOVA



REVIEW

The ABCs of managing systolic heart failure: Past, present, and future 753

Digitalis, diuretics, and bedrest have given way to neurohormonal blockade and physical rehabilitation.

I.S. OKWUOSA, O. PRINCEWILL, C. NWABUEZE, L. MATHEWS, S. HSU, N.A. GILOTRA, S. LEWSEY, R.S. BLUMENTHAL, AND S.D. RUSSELL

EDITORIAL

Evolution of heart failure management: Miles to go 766

Despite progress, too many patients still suffer, too many die too young, and the costs are still too great.

J.B. YOUNG

DEPARTMENTS

CME Calendar 702

Letters to the Editor 703

A reader comments on obstructive sleep apnea (January 2016).

Correction 739

An error appeared in "Anemia of chronic kidney disease: Treat it, but not too aggressively" by Drs. Georges Nakhoul and James F. Simon (Cleve Clin J Med 2016; 83:613–624).

CME Test Directions Inside back cover

Upcoming Features

- Chronic opioid therapy: Breaking the pain contract
- Radiation-induced heart disease
- Pulmonary embolism: Which patients benefit from thrombolysis?
- Bedbugs: A practical review
- Managing benign prostatic hyperplasia in primary care
- Lipids, statins, and the frail elderly
- Taurine, energy drinks, and neuroendocrine effects
- What is the role of roflumilast in COPD?
- Blood transfusion: Is less really more?

