

## Online Features

### Access

Cleveland Clinic Journal of Medicine content is readily available to all and is free of charge at [www.ccjm.org](http://www.ccjm.org). On your first visit, we will ask you to take a few minutes to register, but subsequent visits will be unencumbered except for an occasional request for your e-mail address when you visit using another device (eg, mobile phone, tablet).

### Services

- Navigate quickly to articles in current and past issues via links on the home page and pull-down menus at the top of the page. Use the search function to find a specific article, or browse by topic or article type.
- Continuing medical education activities are accessible from article links and from a CME pull-down menu on the home page. Participation is free.
- Follow links on the home page to news, summaries of recent scientific meetings, and interactive quizzes.
- Click on the PDF symbol at the top of any online article to read, download, or print the article in PDF format.

### Social Networking

To post a *CCJM* article to Facebook or Twitter, just click on the icon at the top of any online article.

[www.ccjm.org](http://www.ccjm.org)

# TABLE OF CONTENTS

## FROM THE EDITOR .....

**Hiding in clear sight: Complications of immunosuppressive therapies** 862  
Immunosuppressive drugs can mask the signs of deep infection and thus delay its diagnosis.

B.F. MANDELL

## THE CLINICAL PICTURE.....

**Phlegmasia cerulea dolens from radiation-induced venous stenosis** 865  
The patient had received pelvic radiation 10 years earlier for prostate cancer.

S. PAUL AND M. SHEIKH

## THE CLINICAL PICTURE.....

**Abdominal pain under immunosuppressive conditions** 874  
A cancer patient receiving corticosteroids for a brain metastasis developed emphysematous cystitis and psoas muscle abscess.

T. OTA, M. NAKANO, N. TANAKA, T. SUZUMURA, N. MIYATAKE, Y. HASEGAWA, T. OZAKI, H. TSUKUDA, AND M. FUKUOKA

## THE CLINICAL PICTURE.....

**Minocycline-induced hyperpigmentation** 876  
The patient presented with extensive bluish skin discoloration that had started 1 year earlier as a small area and then spread.

M. ABDELGHANY AND A.J. KIVITZ

## SMART TESTING .....

**What stool testing is appropriate when diarrhea develops in a hospitalized patient?** 882  
Most cases are not due to infection, but *Clostridium difficile* is the most common infectious cause.

S.K. RAMDEEN AND G.W. WORTMANN

## 1-MINUTE CONSULT .....

**When should an indwelling pleural catheter be considered for malignant pleural effusion?** 891  
Consider catheter placement if symptoms and effusions recur or if pleurodesis fails.

A.H. ALRAIYES, K. HARRIS, AND T.R. GILDEA

CONTINUED ON PAGE 860

CONTINUED FROM PAGE 855

REVIEW .....

**Taurine, energy drinks, and neuroendocrine effects** 895

Taurine is a major ingredient in popular energy drinks, but little is known about its neuroendocrine effects.

J.J. CAINE AND T.D. GERACIOTI



REVIEW .....

**Women's health 2016: An update for internists** 905

Important studies of urinary tract infections, bisphosphonates, ovarian cancer screening, and contraception.

P. BATUR, E.B. SCHWARZ, J.M.E. WALSH, AND K.M. JOHNSON



REVIEW .....

**Radiation-induced heart disease: A practical guide to diagnosis and management** 914

Unfortunately, radiotherapy for breast cancer or lymphoma can damage the heart.

E. DONNELLAN, D. PHELAN, P. COLLIER, M. DESAI, AND B. GRIFFIN

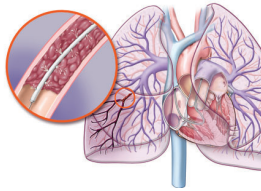


REVIEW .....

**Do patients with submassive pulmonary embolism benefit from thrombolytic therapy?** 923

The risk of hemorrhage is significant, and the benefit is unclear. A one-treatment-for-all approach cannot be applied.

A. ATAYA, J. COPE, A. SHAHMOHAMMADI, AND H. ALNUAIMAT



EDITORIAL .....

**Thrombolysis in submassive pulmonary embolism: Finding the balance** 933

In massive pulmonary embolism, thrombolytic therapy is usually indicated; in submassive cases the decision is not so clear.

C.L. ALVIAR AND G.A. HERESI

DEPARTMENTS .....

**CME Calendar** 854

**CME Test Directions** Inside back cover

# Upcoming Features

- Postexposure management of infectious diseases
- Managing benign prostatic hyperplasia in primary care
- Statins and the frail elderly: When is it time to forgo?
- What is the role of roflumilast in COPD?
- Blood transfusion: Is less really more?
- Vulvovaginitis: Not only infectious causes
- Diagnosing acid-base disorders in 5 easy steps
- Staying afloat in a sea of information
- Female sexual dysfunction: Common and complex

