

# Phlegmasia cerulea dolens from radiation-induced venous stenosis

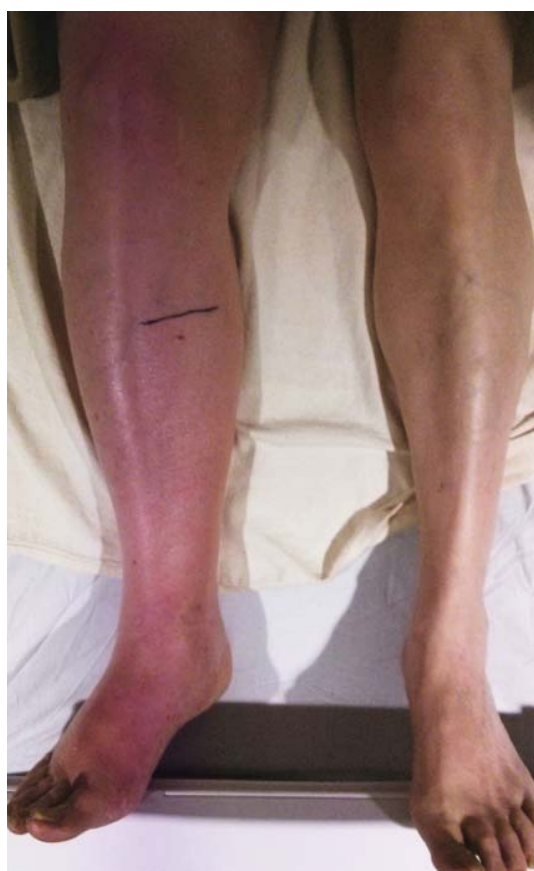**A** 77-YEAR-OLD MAN presented with a 5-day history of painful swelling of his right leg. He reported no trauma, no recent surgery, no history of thrombophilic disorder, and no prolonged immobilization. However, he had a history of prostate cancer, treated 10 years earlier with pelvic radiation.

Examination revealed massive right leg swelling extending from the thigh to the ankle, along with bluish-red skin discoloration (Figure 1). Doppler ultrasonography demonstrated acute thrombosis involving the right iliofemoral veins. These findings were consistent with phlegmasia cerulea dolens.

Urgent percutaneous catheter-directed thrombolysis was performed. Venography revealed extensive thrombosis of the femoral vein (Figure 2A) extending into the right external iliac vein. This was treated with catheter-directed pharmacomechanical thrombectomy.

Venography after this procedure showed significant improvement in venous blood flow (Figure 2B). However, stenosis of the right external iliac vein was also noted (Figure 2C) and was treated with balloon angioplasty (Figure 2D) followed by placement of a stent (14 × 40 mm).

In the immediate postprocedural period, there was marked reduction in swelling and normalization of skin color (Figure 3). The patient did not experience significant bleeding during or after the procedure. Treatment with intravenous unfractionated heparin was continued during the hospital stay, and he was discharged on warfarin with a therapeutic international normalized ratio. At a follow-up visit 3 months later, he was asymptomatic.

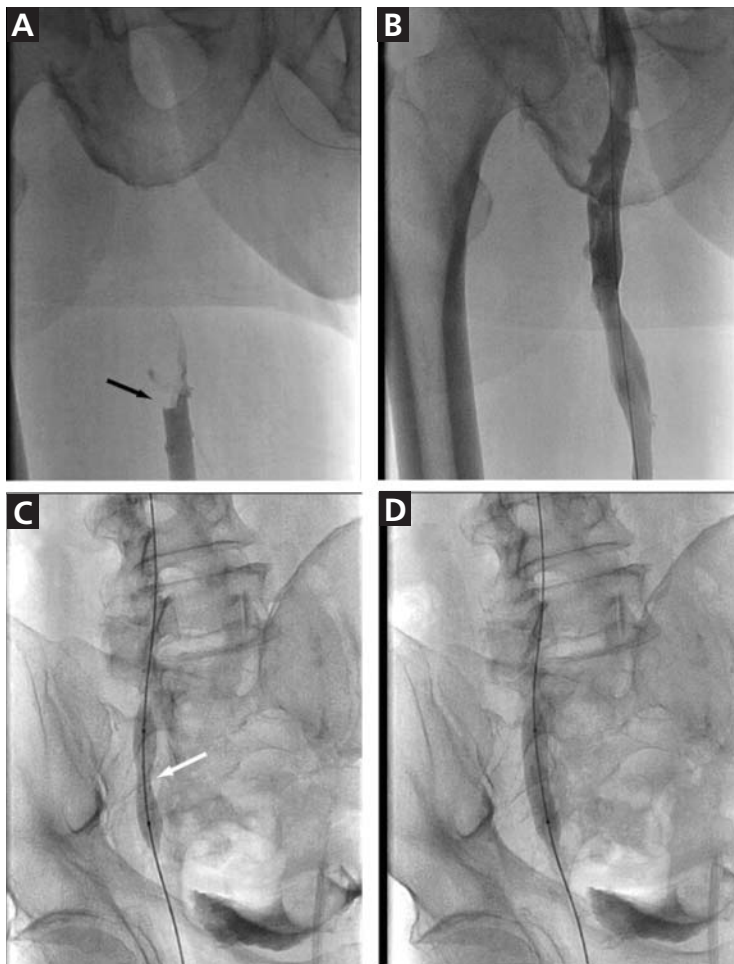


**An urgent  
cardiovascular  
interventional  
consultation  
is required**

**FIGURE 1.** The patient had painful swelling and bluish-red discoloration of the right leg at the time of presentation.

## ■ A RARE BUT SEVERE TYPE OF ACUTE DEEP VEIN THROMBOSIS

Phlegmasia cerulea dolens (painful cyanotic swollen leg) is a rare and severe form of acute deep vein thrombosis (DVT) characterized by marked limb pain, swelling, and blue discoloration.<sup>1</sup> DVT is the most common cause of

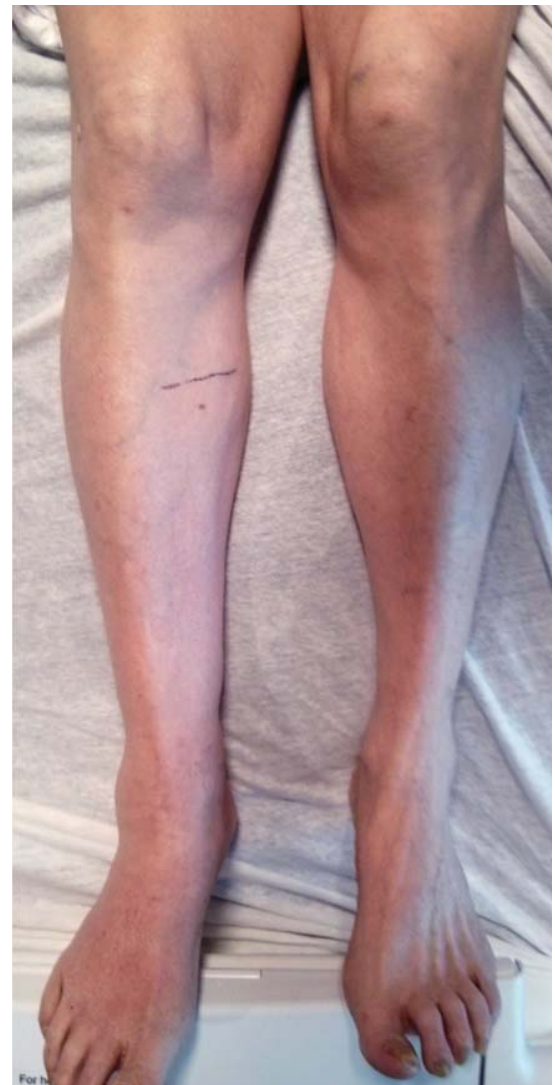

**FIGURE 2.** Venography (A) showed obstruction of venous flow in the right femoral vein (black arrow). After catheter-directed pharmacomechanical thrombectomy (B), venous flow was restored. Stenosis of the right external iliac vein (C) caused indentation of the expanding balloon (white arrow) during angioplasty. Panel D shows the external iliac vein after balloon dilation.

acute-onset unilateral leg pain, swelling, and skin discoloration.<sup>2</sup>

### The differential diagnosis

The differential diagnosis includes infection (cellulitis, necrotizing fasciitis), compartment syndrome from limb injury, musculoskeletal conditions such as ruptured Baker cyst, venous stasis due to external compression (May-Thurner syndrome, iliac vein compression syndrome, pelvic tumor), acute limb ischemia from arterial obstruction, and complex regional pain syndrome (reflex sympathetic dystrophy).



**FIGURE 3.** After pharmacomechanical thrombectomy and placement of an iliac vein stent, the skin color returned to normal and the swelling resolved.

### Management recommendations

As in most cases of DVT, initial treatment of phlegmasia cerulea dolens involves systemic anticoagulation with heparin, elevation of the affected extremity, and fluid resuscitation if the patient is hypotensive. However, phlegmasia cerulea dolens is a major indication for catheter-directed thrombolysis,<sup>3,4</sup> so an urgent vascular surgery or interventional cardiology consultation is also required. The American College of Chest Physicians recommends catheter-directed thrombolysis for acute DVT of the iliofemoral veins in patients with symp-

toms for less than 14 days, good functional capacity, and a life expectancy beyond 1 year.<sup>5</sup> This intervention results in reduced incidence of postthrombotic syndrome and improved quality of life<sup>5,6</sup> compared with anticoagulation therapy alone.

### Who is at risk?

Risk factors for phlegmasia cerulea dolens include a history of malignancy, inherited or acquired thrombophilia, surgery, radiation therapy, trauma, placement of an inferior vena cava filter, and pregnancy. In our patient, the iliac vein stenosis most likely was the result of the radiation therapy he had undergone for prostate cancer.

Arterial stenosis is a well-known complication of radiation therapy and is associated with

an increased risk of cardiovascular events.<sup>7,8</sup> Radiation induces endothelial damage followed by proliferation of smooth muscle cells, resulting in luminal stenosis and thrombosis. At the cellular level, radiation leads to an acute increase in pro-inflammatory cytokines and endothelial adhesion molecules, causing the recruitment of inflammatory cells to radiation-exposed vessels and chronic activation of transcription factor NF-kappa B, leading to long-term inflammation and angiogenesis.<sup>9</sup>

Carotid, coronary, and iliac artery stenosis are known to occur around 10 years after radiation therapy to the head, neck, breast, and pelvis. Radiation-induced iliac vein stenosis is rare and can manifest as acute proximal DVT. ■

### REFERENCES

1. Mumoli N, Invernizzi C, Luschi R, Carmignani G, Camaiti A, Cei M. Phlegmasia cerulea dolens. *Circulation* 2012; 125:1056–1057.
2. Ely JW, Osheroff JA, Chambliss ML, Ebell MH. Approach to leg edema of unclear etiology. *J Am Board Fam Med* 2006; 19:148–160.
3. Casey ET, Murad MH, Zumaeta-Garcia M, et al. Treatment of acute iliofemoral deep vein thrombosis. *J Vasc Surg*. 2012; 55:1463–1473.
4. Chinsakchai K, Ten Duis K, Moll FL, de Borst GJ. Trends in management of phlegmasia cerulea dolens. *Vasc Endovascular Surg* 2011; 45:5–14.
5. Kearon C, Kahn SR, Agnelli G, Goldhaber S, Raskob GE, Comerota AJ; American College of Chest Physicians. Antithrombotic therapy for venous thromboembolic disease: American College of Chest Physicians Evidence-Based Clinical Practice Guidelines (8th Edition). *Chest* 2008; 133(suppl 6):454S–545S.
6. Enden T, Haig Y, Kløw NE, et al; CaVenT Study Group. Long-term outcome after additional catheter-directed thrombolysis versus standard treatment for acute iliofemoral deep vein thrombosis (the CaVenT study): a randomised controlled trial. *Lancet* 2012; 379:31–38.
7. Hoening MJ, Botma A, Aleman BM, et al. Long-term risk of cardiovascular disease in 10-year survivors of breast cancer. *J Natl Cancer Inst* 2007; 99:365–375.
8. Weintraub NL, Jones WK, Manka D. Understanding radiation-induced vascular disease. *J Am Coll Cardiol* 2010; 55:1237–1239.
9. Halle M, Gabrielsen A, Paulsson-Berne G, et al. Sustained inflammation due to nuclear factor-kappa B activation in irradiated human arteries. *J Am Coll Cardiol* 2010; 55:1227–1236.

ADDRESS: Suman Paul, MBBS, PhD, Department of Internal Medicine, MS 1150, University of Toledo, 3000 Arlington Avenue, Toledo, OH 43614; [suman.paul@utoledo.edu](mailto:suman.paul@utoledo.edu)