

## Online Features

### Access

Cleveland Clinic Journal of Medicine content is readily available to all and is free of charge at [www.ccjm.org](http://www.ccjm.org). On your first visit, we will ask you to take a few minutes to register, but subsequent visits will be unencumbered except for an occasional request for your e-mail address when you visit using another device (eg, mobile phone, tablet).

### Services

- Navigate quickly to articles in current and past issues via links on the home page and pull-down menus at the top of the page. Use the search function to find a specific article, or browse by topic or article type.
- Continuing medical education activities are accessible from article links and from a CME pull-down menu on the home page. Participation is free.
- Follow links on the home page to news, summaries of recent scientific meetings, and interactive quizzes.
- Click on the PDF symbol at the top of any online article to read, download, or print the article in PDF format.

### Social Networking

To post a *CCJM* article to Facebook or Twitter, just click on the icon at the top of any online article.

[www.ccjm.org](http://www.ccjm.org)

# TABLE OF CONTENTS

## FROM THE EDITOR .....

**The people behind the *Journal* really matter 631**  
This month, the *Journal* bids farewell to sales and marketing director Joe Dennehy and deputy editor Jim Pile.

B.F. MANDELL

## THE CLINICAL PICTURE .....

**'Air-raising': An air-fluid level in the right subphrenic region 638**

Plain chest radiography showed dramatic elevation of the right hemidiaphragm with a large subphrenic air-fluid level.

A. GUPTA AND O. EPELBAUM

## THE CLINICAL PICTURE .....

**A man with HIV and papules and nodules on the knees 641**

Erythema elevatum diutinum may be confused with Sweet syndrome, Kaposi sarcoma, or bacillary angiomatosis.

A.M. VICTORIA-MARTÍNEZ, L. CUBELLS-SÁNCHEZ, L. MARTÍNEZ-LEBORANS, J.L. SÁNCHEZ-CARAZO, AND V.A. DE MIQUEL

## THE CLINICAL PICTURE .....

**An abnormal peripheral blood smear and altered mental status 643**

Therapeutic plasma exchange has greatly increased the survival rate in thrombotic thrombocytopenic purpura.

S. WONGRAKPANICH, M. SALAHUDDIN, AND P. MITTAR

## 1-MINUTE CONSULT .....

**Are there alternatives to surgery for Zenker diverticulum? 645**

High rates of complications in elderly patients have led to the development of endoscopic procedures.

N. AGGARWAL AND P.N. THOTA

## IM BOARD REVIEW .....

**Erythrocytosis due to presumed polycythemia vera 648**



Erythrocytosis has a variety of potential causes.

R. PATELL, K. THEIL, AND A. LICHTIN

CONTINUED ON PAGE 630

CONTINUED FROM PAGE 629

**CME CREDIT** REVIEW ..... 655

**Managing irritable bowel syndrome: The low-FODMAP diet**

A diet low in fermentable oligosaccharides, disaccharides, monosaccharides, and polyols (FODMAPs) reduces symptoms.

M. DUGUM, K. BARCO, AND S. GARG

**EDITORIAL** ..... 663

**Diet in the pathophysiology and management of irritable bowel syndrome**

Diet plays an important role in the pathophysiology of this disorder and is an effective tool in managing it.

M. EL-SALHY

**CME CREDIT** ADDRESSING DISPARITIES IN HEALTHCARE ..... 665

**Gout and African Americans: Reducing disparities**

African Americans are more likely to suffer from gout and are less likely to receive optimal treatment for it.

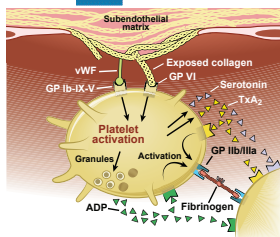
B. KUMAR AND P. LENERT

**CME CREDIT** CURRENT DRUG THERAPY ..... 675

**Dual antiplatelet therapy for acute coronary syndromes: How long to continue?**

After drug-eluting stent placement, at least 12 months of dual antiplatelet therapy is recommended. Would longer be better?

M. HALKAR AND A.M. LINCOFF



**DEPARTMENTS** ..... 633

**CME Calendar** ..... 633

**Correction** ..... 644

An error appeared in the article “Total pancreatectomy and islet cell autotransplantation: Definitive treatment for chronic pancreatitis” (Arce KM, Lin YK, Stevens T, Walsh RM, Hatipoglu BA. *Cleve Clin J Med* 2016; 83:435–442.)

**CME Test Directions** ..... **Inside back cover**

# Upcoming Features

- Update in perioperative cardiac medicine
- The ABCs of managing systolic heart failure
- Breaking the pain contract for chronic opioid therapy
- Dermatologic signs of nutritional deficiencies
- Serotonin syndrome: Not just from SSRIs
- Taurine energy drinks: Any risks? Benefits?
- Benign prostatic hyperplasia: Primary care management
- Give thrombolysis for submassive pulmonary embolism?
- Iodine deficiency: Clinical implications
- Bedbugs: A practical review

