ANUPAM GUPTA, MD
Division of Pulmonary and Critical Care Medicine, Elmhurst Hospital Center, Icahn School of Medicine at Mount Sinai, Elmhurst, NY

OLEG EPELBAUM, MD
Division of Pulmonary and Critical Care Medicine, Elmhurst Hospital Center, Icahn School of Medicine at Mount Sinai, Elmhurst, NY

'Air-raising': An air-fluid level in the right subphrenic region

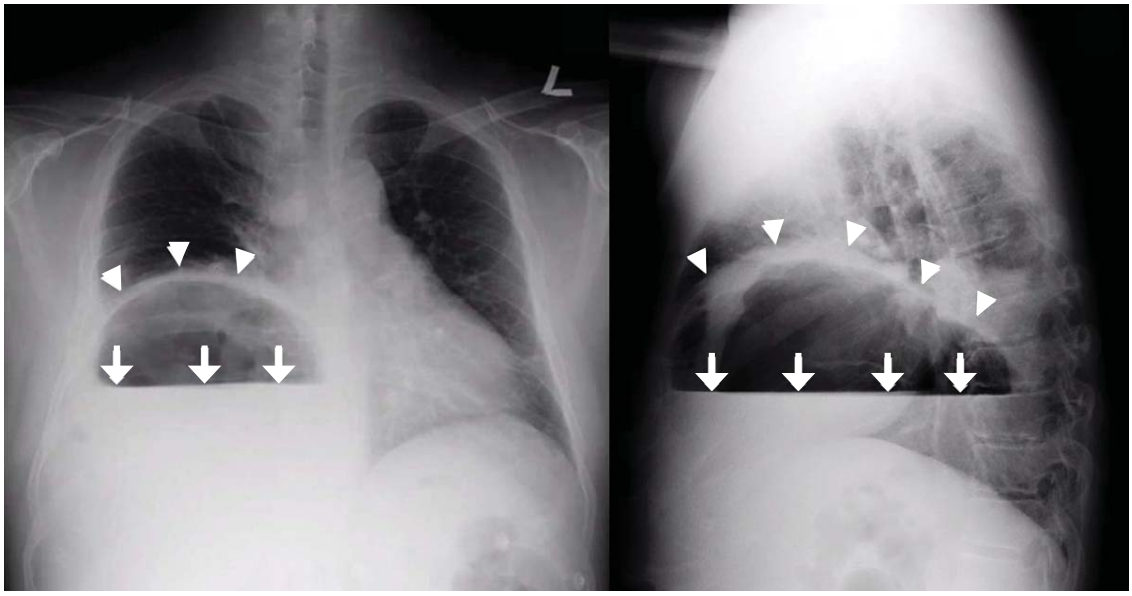

FIGURE 1. Plain chest radiography showed a dramatic elevation of the right hemidiaphragm (arrowheads), with a large subphrenic air-fluid level (arrows). The air-fluid level was characterized by a sharp horizontal demarcation between the lighter gas component floating at the top and the heavier fluid component settling on the bottom.

A 39-year-old Filipino man presented with nausea, vomiting, and abdominal pain of 2 weeks' duration. He did not report trauma, and he had no history of medical illness or surgery.

On arrival, his blood pressure was 123/83 mm Hg, pulse 122 beats per minute, respiratory rate 18 breaths per minute, and temperature 100.7°F (38.1°C). On physical examination, he exhibited marked tenderness of the right upper quadrant on palpation. The abdomen was otherwise soft with no guarding or rebound tenderness.

doi:10.3949/ccjm.83a.15162

Results of initial laboratory testing were as follows:

- Leukocyte count 17.0 × 10^9/L (reference range 4.5–11.0)
- Serum glucose 558 mg/dL without ketoacidosis
- Aspartate aminotransferase 109 U/L (2–40)
- Alanine aminotranferase 28 U/L (2–50)
- Total serum bilirubin 4.0 mg/dL (0.0–1.5).

Plain chest radiography showed dramatic elevation of the right hemidiaphragm with a large subphrenic air-fluid level (**Figure 1**). Abdominal computed tomography (CT) demonstrated a multiloculated hepatic abscess 18 × 13.5 cm subjacent to the diaphragm (**Figure 2**). Cultures

Downloaded from www.ccjm.org on April 20, 2024. For personal use only. All other uses require permission.

of blood and the abscess yielded *Klebsiella pneumoniae*. The patient recovered after percutaneous drainage and a course of ceftriaxone.

PRIMARY *KLEBSIELLA* LIVER ABSCESS

K pneumoniae, a gram-negative aerobic encapsulated bacillus of the normal human intestinal flora, is closely related to *Escherichia coli*, historically the most frequent bacterial cause of pyogenic liver abscess.[1] Over the last 30 years, *K pneumoniae* has eclipsed *E coli* as the most common causative agent, with the epicenter of this trend being located in Taiwan and South Korea, perhaps because rates of fecal *Klebsiella* carriage in that region are particularly high.[1,2]

Concurrently, there has been increasing recognition—initially across Asia, but lately in Europe and the Western Hemisphere—of the so-called invasive *Klebsiella* liver abscess (KLA) syndrome, virtually unique to the hypervirulent K1 and K2 capsular serotypes of *K pneumoniae* prevalent in Asia.[3–6] This community-acquired syndrome is characterized by hematogenous deposition of the organism at distant sites, such as the lung, soft tissues, central nervous system, and eyes. Impairment of phagocytic function, as occurs in diabetes mellitus, and the resistance to phagocytosis conferred by the K1 and K2 serotypes have been identified as predisposing factors for dissemination.[7,8] The mucoid phenotype of *K pneumoniae*, very common in Asian isolates of the K1 and K2 serotypes, is also associated with hypervirulence and extrahepatic spread, presumably through evasion of phagocytosis and complement-mediated opsonization.[2,9]

Our patient's risk factors for KLA were his Asian origin and uncontrolled diabetes. No evidence of remote infection was detected during his hospitalization.

HEMIDIAPHRAGM ELEVATION

Acquired hemidiaphragm elevation is most commonly unilateral and typically represents an incidental radiologic finding attributable to paralysis of the corresponding diaphragm after phrenic nerve injury caused by trauma, surgery, or infection. Unilateral diaphragmatic paralysis is classically confirmed by performing a fluoroscopic sniff test, which is positive if the affected hemidiaphragm is observed in real time to paradoxically move upward during forced inhalation.[10] This condition is usually asymptomatic at rest but could cause exertional dyspnea and contribute to ventilatory failure when pulmonary disease coexists.[11]

FIGURE 2. Abdominal computed tomography showed a multiloculated hepatic abscess 18 × 13.5 cm subjacent to the diaphragm (arrow).

Occasionally, as in our patient, hemidiaphragm elevation is part of the presentation of active abdominal pathology that displaces the corresponding hemidiaphragm cephalad by mass effect. Examples of such space-occupying abdominal lesions include infections, malignancy, hepatosplenomegaly, and pneumoperitoneum from a ruptured viscus. Pneumoperitoneum is suggested by the presence of an air crescent immediately subjacent to the affected hemidiaphragm on an upright radiograph accompanied by peritoneal signs.

Although there was subphrenic air on this patient's initial chest radiograph, it was actually part of an air-fluid level without associat-

The subphrenic air on chest radiography was actually part of an air-fluid level without associated peritoneal signs

Downloaded from www.ccjm.org on April 20, 2024. For personal use only. All other uses require permission.

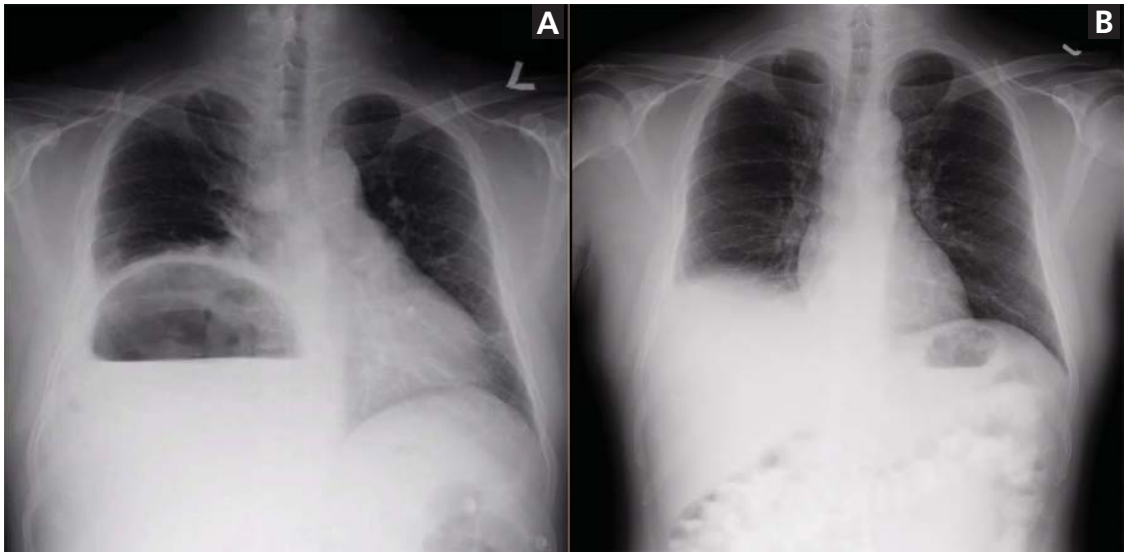

FIGURE 3. Compared with the initial radiograph (A), the subsequent frontal radiograph (B) shows the reduction in the height of the right hemidiaphragm after drainage of the abscess.

ed peritoneal signs. An air-fluid level is characterized by a sharp horizontal demarcation between the lighter gas component floating at the top and the heavier fluid component settling on the bottom (**Figure 1**). The subsequent CT excluded free intra-abdominal air while identifying a large hepatic abscess as the cause of hemidiaphragm elevation. In trauma victims, CT is also helpful in ruling out diaphragmatic rupture, which can have a similar radiographic appearance.[12]

Our patient's presentation was a reminder that an elevated hemidiaphragm may reflect abdominal pathology and that subphrenic air in this context need not be either "free" or a surgical emergency. Drainage of the abscess restored the normal position of our patient's right hemidiaphragm (**Figure 3**).

REFERENCES

1. **Huang CJ, Pitt HA, Lipsett PA, et al**. Pyogenic hepatic abscess: changing trends over 42 years. Ann Surg 1996; 223:600–607.
2. **Lin YT, Siu LK, Lin JC, et al**. Seroepidemiology of *Klebsiella pneumoniae* colonizing the intestinal tract of healthy Chinese and overseas Chinese adults in Asian countries. BMC Microbiol 2012; 12:13.
3. **Wang JH, Liu YC, Lee SS, et al**. Primary liver abscess due to *Klebsiella pneumoniae* in Taiwan. Clin Infect Dis 1998; 26:1434–1438.
4. **Pastagia M, Arumugam V**. *Klebsiella pneumoniae* liver abscesses in a public hospital in Queens, New York. Travel Med Infect Dis 2008; 6:228–233.
5. **Rahimian J, Wilson T, Oram V, Holzman RS**. Pyogenic liver abscess: recent trends in etiology and mortality. Clin Infect Dis 2004; 39:1654–1659.
6. **Moore R, O'Shea D, Geoghegan T, Mallon PW, Sheehan G**. Community-acquired *Klebsiella pneumoniae* liver abscess: an emerging infection in Ireland and Europe. Infection 2013; 41:681–686.
7. **Lecube A, Pachón G, Petriz J, Hernández C, Simó R**. Phagocytic activity is impaired in type 2 diabetes mellitus and increases after metabolic improvement. PLoS One 2011; 6:e23366.
8. **Lin JC, Siu LK, Fung CP, et al**. Impaired phagocytosis of capsular serotypes K1 or K2 *Klebsiella pneumoniae* in type 2 diabetes mellitus patients with poor glycemic control. J Clin Endocrinol Metab 2006; 91:3084–3087.
9. **Siu LK, Yeh KM, Lin JC, Fung CP, Chang FY**. *Klebsiella pneumoniae* liver abscess: a new invasive syndrome. Lancet Infect Dis 2012; 12:881–887.
10. **Gierada DS, Slone RM, Fleishman MJ**. Imaging evaluation of the diaphragm. Chest Surg Clin North Am 1998; 8:237–280.
11. **Qureshi A**. Diaphragm paralysis. Semin Respir Crit Care Med 2009; 30:315–320.
12. **Havens JM, Kelly E, Patel V**. A 78-year-old man with an elevated hemidiaphragm following trauma. Chest 2008; 134:1336–1339.

***ADDRESS**: Anupam Gupta, MD, Department of Pulmonary and Critical Care, Icahn School of Medicine at Mount Sinai, 79-01 Broadway, Suite D6-4, Elmhurst, NY 11373; guptaa16@nychhc.org*

Downloaded from www.ccjm.org on April 20, 2024. For personal use only. All other uses require permission.