

THE CLINICAL PICTURE

ANAHY M. BRANDY-GARCÍA

Servicio de Reumatología, Hospital Universitario Central de Asturias Oviedo, Spain

IVAN CABEZAS-RODRIGUEZ

Servicio de Reumatología, Hospital Universitario Central de Asturias, Oviedo, Spain

LUIS CAMINAL-MONTERO

Consulta-Unidad Enfermedades Autoinmunes Sistémicas, Unidad Clínica de Medicina Interna Hospital Universitario Central de Asturias, Oviedo, Spain

CARLOS SUAREZ-CUERVO

Department of General Medicine, Borders General Hospital, Melrose, Scotland, UK

PILAR REDONDO-BUIL

Servicio de Radiología, Hospital Universitario Central de Asturias, Oviedo, Spain

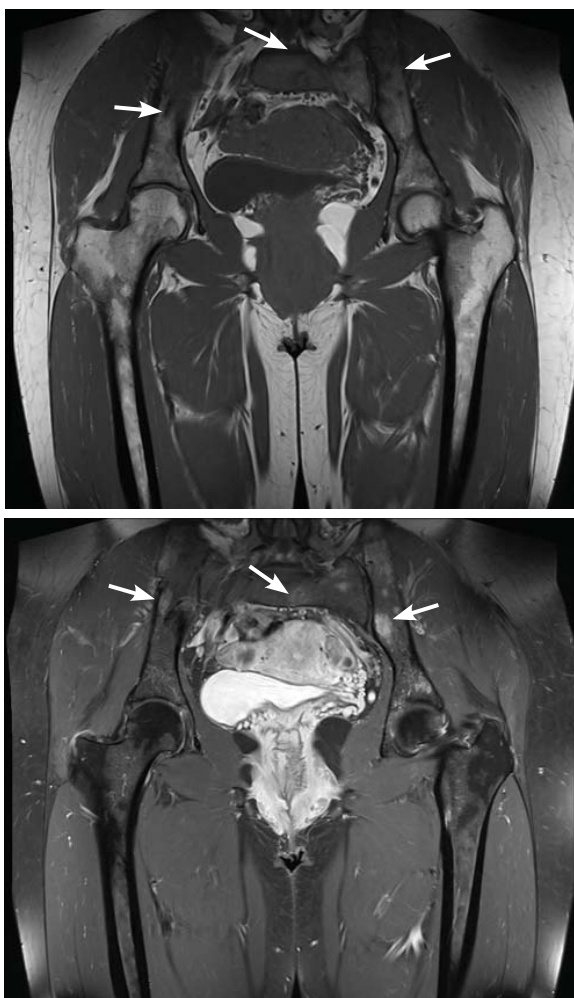
Sarcoidosis mimicking lytic osseous metastases

A 41-YEAR-OLD WOMAN PRESENTED with coughing, wheezing, and painful subcutaneous nodules on her legs. She had presented 6 years ago with similar nodules and enlarged retroauricular, occipital, and maxillary lymph nodes. At that time, biopsy study of submaxillary lymph nodes and skin showed nonnecrotizing granulomas, with negative microbiology studies. Chest radiography and spirometry were normal. A diagnosis of sarcoidosis was made. Treatment was offered but refused.

Based on this history, computed tomography of the thorax and abdomen was performed and showed mediastinal and hilar lymphadenopathy, small bilateral lung nodules, and osseous cystic areas in both iliac blades. Magnetic resonance imaging (MRI) showed numerous discrete lesions in both iliac bones (**Figure 1**). Biopsy study of iliac bone revealed preserved architecture with no evidence of malignancy or granulomas.

Radiography of the hands showed an osseous lytic lesion in the third proximal phalanx of the right hand. No other radiographic abnormalities were noted.

The clinical and radiographic features and the patient's clinical course were consistent with osseous sarcoidosis. She was started on methotrexate and a low-dose corticosteroid and was symptom-free at 12-month follow-up. Follow-up MRI showed reduction in the lymphadenopathies and stabilization of the bone lesions.



Skeletal involvement has been reported in 1% to 14% of patients with sarcoidosis

FIGURE 1. Magnetic resonance imaging revealed low-intensity lesions (arrows) on T1-weighted sequences (upper panel) and high-intensity lesions on short tau inversion recovery sequences (lower panel). The lesions have defined borders, no cortical disruption, and no mass effect, features suggesting that the lesions are benign. Lack of signal homogeneity suggests chronic lesions.

doi:10.3949/ccjm.84a.16108

■ SARCOIDOSIS AND BONE

Sarcoidosis is a systemic granulomatous disease that involves the lung in more than 90% of cases. Skeletal involvement has been reported in 1% to 14% of patients.^{1,2} Typical osseous involvement is cystic osteitis of the phalangeal bones of the hands and feet, but any part of the skeleton may be involved.³

Bone sarcoidosis is usually asymptomatic and is discovered incidentally. The diagnosis of sarcoidosis has usually been established clinically before bone lesions are detected

on MRI. However, sarcoidosis-related bone lesions resembling bone metastases on MRI may be the initial presentation. The presence of intralesional fat has been described as a feature that excludes malignancy.

No treatment has been shown to be of benefit.⁴ Sarcoidosis is a diagnosis of exclusion and radiographic lytic bone features are not specific, so a neoplastic cause (such as primary osteoblastoma, metastasis, or multiple myeloma) must always be ruled out, as well as other bone conditions such as osteomyelitis or bone cyst. ■

■ REFERENCES

1. **Valeyre D, Prasse A, Nunes H, Uzunhan Y, Brillet PY, Müller-Quernheim J.** Sarcoidosis. *Lancet* 2014; 383:1155–1167.
2. **James DG, Neville E, Carstairs LS.** Bone and joint sarcoidosis. *Semin Arthritis Rheum* 1976; 6:53–81.
3. **Moore SL, Kransdorf MJ, Schweitzer ME, Murphey MD, Babb JS.** Can sarcoidosis and metastatic bone lesions be reliably differentiated on routine MRI? *AJR Am J Roentgenol* 2012; 198:1387–1393.
4. **Hamoud S, Srour S, Fruchter O, Vlodaysky E, Hayek T.** Lytic bone lesion: presenting finding of sarcoidosis. *Isr Med Assoc J* 2010; 12:59–60.

ADDRESS: Anahy M. Brandy-García, Servicio de Reumatología, Hospital Universitario Central de Asturias, Av Roma s/n, 33011 Asturias, Spain; anahymbg@gmail.com