

THE CLINICAL PICTURE

HSIU-CHIEN YANG, MD

Department of Internal Medicine, Division of Nephrology, Tri-Service General Hospital, National Defense Medical Center, Taipei, Taiwan; and Division of Nephrology, Department of Internal Medicine, Zuoying Branch of Kaohsiung Armed Forces General Hospital, Kaohsiung, Taiwan

CHANG-HAN LO, MD

Department of Internal Medicine, Division of Nephrology, Tri-Service General Hospital, National Defense Medical Center, Taipei, Taiwan

CHUN-CHI CHEN, MD

Department of Internal Medicine, Division of Nephrology, Tri-Service General Hospital, National Defense Medical Center, Taipei, Taiwan

CHIA-CHAO WU, MD, PhD

Department of Internal Medicine, Division of Nephrology, Tri-Service General Hospital, National Defense Medical Center, Taipei, Taiwan

Porcelain heart in a uremic patient

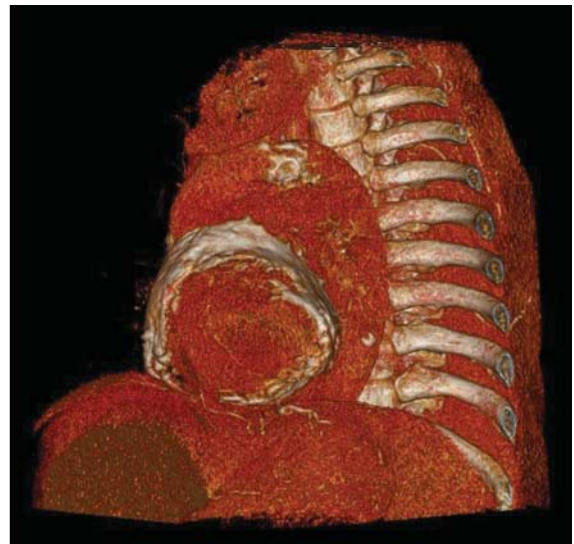
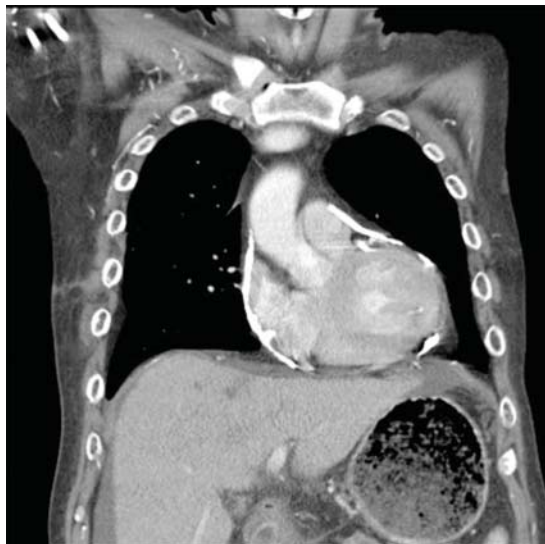

FIGURE 1. Thoracic computed tomography revealed calcified pericardium with heart encasement in the coronal view (left) and sagittal view (right).

Constrictive pericarditis occurs in up to 4% of patients with end-stage renal disease

A 58-YEAR-OLD MAN with end-stage renal disease due to diabetic nephropathy was admitted with aggravated exertional dyspnea and intermittent chest pain for 1 week. He had been on hemodialysis for 15 years.

His blood pressure was 124/69 mm Hg, pulse 96 beats per minute, and temperature 35.8°C. On physical examination, he had bilateral diffuse crackles, elevated jugular venous pressure (9.5 cm H₂O) with positive hepatojugular reflux, and apparent dependent pedal edema. The Kussmaul sign was not observed.

Cardiac enzymes were in the normal range (creatinine kinase 73 U/L, troponin I 0.032 ng/mL), but the brain-natriuretic peptide level was elevated at 340 pg/mL. Other laboratory findings included calcium 9 mg/dL (reference range 8.4–10.2 mg/dL), inorganic phosphate 5 mg/dL (2.5–4.5 mg/dL), and intact parathyroid hormone 1,457 pg/mL (10–69 pg/mL).

Electrocardiography showed sinus tachy-

cardia with low voltage in diffuse leads and generalized flattening of the T wave. Chest radiography showed a bilateral reticulonodular pattern, mild costophrenic angle obliteration, and notable calcifications along the cardiac contour. Thoracic computed tomography showed a porcelain-like encasement of the heart (**Figure 1**). Transthoracic echocardiography showed thickened pericardium, pericardial calcification, and mild interventricular septal bounce in diastole, with no dyskinesia of ventricular wall motion. We decided not to perform an invasive hemodynamic assessment.

■ CAUSES OF PERICARDIAL CALCIFICATION

Pericardial calcification, abnormal calcium deposits in response to inflammation,¹ has become more widely reported as the use of chest computed tomography has become more widespread. The common identifiable causes of pericardial calcification include recurrent or chronic

doi:10.3949/ccjm.84a.15177

pericarditis, radiation therapy for Hodgkin lymphoma or breast cancer, tuberculosis, and end-stage kidney disease.^{2,3} Other possible causes are retention of uremic metabolites, metastatic calcification induced by secondary hyperparathyroidism, and calcium-phosphate deposition induced by hyperphosphatemia.⁴

In chronic kidney disease, the amount of pericardial fluid and fibrinous pericardial deposition is thought to contribute to increased pericardial thickness and constriction. In some patients, pericardial calcification and thickening would lead to constrictive pericarditis, which could be confirmed by echocardiography and cardiac catheterization. About 25% to 50% of cases of pericardial calcification are complicated by constrictive pericarditis.^{5,6} Constrictive pericarditis occurs in up to 4% of patients with end-stage renal disease, even with successful dialysis.⁷

Partial clinical improvement may be obtained with intensive hemodialysis, strict volume control, and decreased catabolism in patients with multiple comorbidities.⁸ However, the definite treatment is total pericardiectomy, which reduces symptoms substantially and offers a favorable long-term outcome.⁷

■ SECONDARY HYPERPARATHYROIDISM

Secondary hyperparathyroidism is a common complication in patients with end-stage renal disease and is characterized by derangements in the homeostasis of calcium, phosphorus, and vitamin D.⁹

Because renal function is decreased, phosphate is retained and calcitriol synthesis is reduced, resulting in hypocalcemia, which induces parathyroid gland hyperplasia and parathyroid hormone secretion.¹⁰ Moreover, some patients with long-standing secondary hyperparathyroidism may develop tertiary hyperparathyroidism associated with autonomous parathyroid hormone secretion, hypercalcemia, and hyperphosphatemia.¹¹

The Kidney Disease: Improving Global Outcomes (KDIGO) Work Group recommends screening for and managing secondary hyperparathyroidism in all patients with stage 3 chronic kidney disease (estimated glomerular filtration rate < 60 mL/min). In patients with stage 5 chronic kidney disease or on dialysis, the serum calcium and phosphorus levels should be monitored every 1 to 3 months and the parathyroid hormone levels every 3 to 6 months.¹²

According to KDIGO guidelines, the target level of calcium is less than 10.2 mg/dL, and the target phosphorus level is less than 4.6 mg/dL. The level of parathyroid hormone should be maintained at 2 to 9 times the upper limit of normal for the assay.

The management of secondary hyperparathyroidism includes a low-phosphorus diet, calcium-containing or calcium-free phosphate binders, a calcitriol supplement, and calcimimetics. If medical treatment fails and manifestations are significant, parathyroidectomy may be indicated.¹³

■ REFERENCES

1. Alpert MA, Ravenscraft MD. Pericardial involvement in end-stage renal disease. *Am J Med Sci* 2003; 325:228–236.
2. Gowda RM, Box LM. Calcifications of the heart. *Radiol Clin North Am* 2004; 42:603–617.
3. Kleynberg RL, Kleynberg VM, Kleynberg LM, Farahmandian D. Chronic constrictive pericarditis in association with end-stage renal disease. *Int J Nephrol* 2011; 2011:469602.
4. Rao N, Crail S. Metastatic calcification and long-term hemodialysis. *N Engl J Med* 2013; 368:2415.
5. Ling LH, Oh JK, Schaff HV, et al. Constrictive pericarditis in the modern era: evolving clinical spectrum and impact on outcome after pericardiectomy. *Circulation* 1999; 100:1380–1386.
6. Bergman M, Vitrai J, Salman H. Constrictive pericarditis: a reminder of a not so rare disease. *Eur J Intern Med* 2006; 17:457–464.
7. Szabó G, Schmack B, Bulut C, et al. Constrictive pericarditis: risks, aetiologies and outcomes after total pericardiectomy: 24 years of experience. *Eur J Cardiothorac Surg* 2013; 44:1023–1028.
8. Feldman V, Dovrish Z, Weisenberg N, Neuman Y, Amital H. Uremic pericarditis. *Isr Med Assoc J* 2011; 13:256–257.
9. Levin A, Bakris GL, Molitch M, et al. Prevalence of abnormal serum vitamin D, PTH, calcium, and phosphorus in patients with chronic kidney disease: results of the study to evaluate early kidney disease. *Kidney Int* 2007; 71:31–38.
10. Martin KJ, Gonzalez EA. Metabolic bone disease in chronic kidney disease. *J Am Soc Nephrol* 2007; 18:875–885.
11. Kerby J, Rue LW, Blair H, Hudson S, Sellers MT, Diethelm AG. Operative treatment of tertiary hyperparathyroidism: a single-center experience. *Ann Surg* 1998; 227:878–886.
12. Kidney Disease: Improving Global Outcomes (KDIGO) CKD-MBD Work Group. KDIGO clinical practice guideline for the diagnosis, evaluation, prevention, and treatment of chronic kidney disease—mineral and bone disorder (CKD-MBD). *Kidney Int Suppl* 2009; 76:S1–130.
13. National Kidney Foundation. K/DOQI clinical practice guidelines for bone metabolism and disease in chronic kidney disease. *Am J Kidney Dis* 2003; 42(suppl 3):S1–201.

ADDRESS: Chia-Chao Wu, MD PhD, Division of Nephrology, Department of Medicine, Tri-Service General Hospital, No. 325, Section 2, Cheng-Kung Road, Neihu 114, Taipei, Taiwan; wucc@mail.ndmctsgh.edu.tw