

## THE CLINICAL PICTURE

**TELMA AZEVEDO, MD**  
Department of Infectious Disease and Tropical Medicine, Centro Hospitalar de Lisboa Ocidental, Hospital de Egas Moniz, Lisboa, Portugal

**ALEXANDRE CATARINO, MD**  
Department of Dermatology, Centro Hospitalar de Lisboa Ocidental, Hospital de Egas Moniz, Lisboa, Portugal

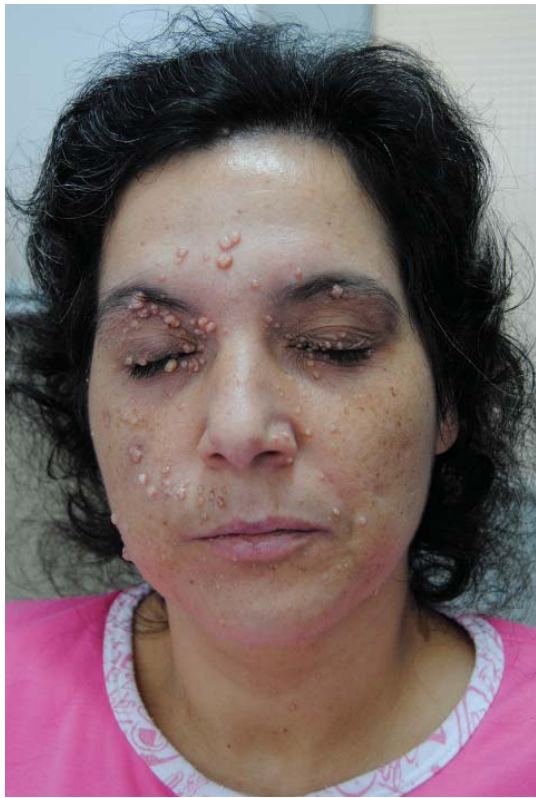**LURDES FERREIRA, MD**  
Department of Dermatology, Centro Hospitalar de Lisboa Ocidental, Hospital de Egas Moniz, Lisboa, Portugal

**FERNANDO BORGES, MD**  
Department of Infectious Disease and Tropical Medicine, Centro Hospitalar de Lisboa Ocidental, Hospital de Egas Moniz, Lisboa, Portugal

**KAMAL MANSINHO, MD**  
Director, Department of Infectious Disease and Tropical Medicine, Centro Hospitalar de Lisboa Ocidental, Hospital de Egas Moniz, Lisboa, Portugal

# Disseminated molluscum contagiosum lesions in an HIV patient

**Molluscum contagiosum lesions in an adult may indicate a high level of immune suppression**



**FIGURE 1.** The patient had multiple lesions on the face, abdomen, and genital area.

**A** 37-YEAR-OLD WOMAN with a 3-month history of disorientation and depression was admitted to the infectious disease unit. In addition, she had had multiple painless exophytic lesions on the face, abdomen, and genital area for the past 3 years.

Physical examination revealed multiple waxy lesions, which were skin-colored dome-shaped papules with an umbilicated top, with diameters of 2 to 10 mm (**Figure 1**).

doi:10.3949/ccjm.84a.16070

Skin biopsy study (**Figure 2**) showed lobulated endophytic hyperplasia with an intra-dermal pseudotumor (Henderson-Paterson bodies). Dimorphic fungal infection with *Cryptococcus* species was excluded. A final diagnosis of molluscum contagiosum was made based on the clinical appearance of the lesions and the histologic findings.

The patient was known to be positive for human immunodeficiency virus (HIV) and to have discontinued medications and follow-up visits in 2011. She was severely immunodepressed, at stage C3 (the worst stage) in the US Centers for Disease Control and Prevention classification. Her CD4 cell count was  $26 \times 10^6/L$  (reference range 533–1,674) and 11% (34%–61%); her viral load was 252,085 copies/mm<sup>3</sup>.

Subsequently, she was diagnosed with HIV-related encephalopathy and disseminated *Mycobacterium tuberculosis* infection. Highly active antiretroviral therapy (HAART) and tuberculosis treatment were started.

## ■ LINKED TO IMMUNOCOMPROMISE

Molluscum contagiosum virus is an important human skin pathogen. Transmitted through direct skin-to-skin contact, it can cause disfigurement and suffering in affected patients. It often affects children, but abundant or atypical lesions in an adult usually indicate underlying immunodeficiency<sup>1</sup> and are usually related to impaired cell-mediated immunity.<sup>2</sup>

In the mid-1980s, atypical molluscum contagiosum was recognized as a feature of HIV infection,<sup>3</sup> but with widespread use of HAART, lesions are now less frequently observed in Western countries. Cases of molluscum contagiosum have also been reported in patients receiving immunosuppressive drugs

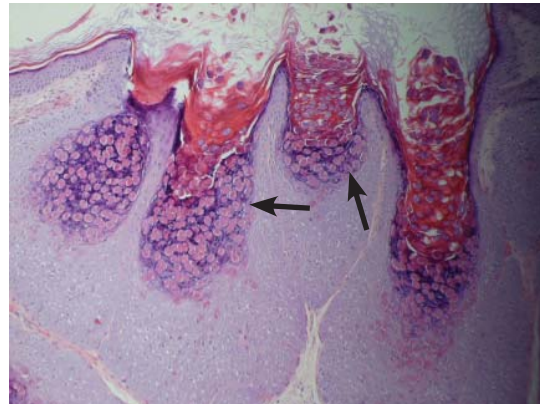
such as methotrexate and tumor necrosis factor alpha inhibitors.<sup>4</sup> A high burden of lesions such as our patient had is uncommon.

Optimal treatment in HIV patients is restoration of immunologic competence with HAART. Adjunctive treatment with surgical excision, curettage, cryotherapy, and various chemical removal methods can also be applied.<sup>4,5</sup> Severe infection secondary to iatrogenic immunosuppression may be resistant to standard therapy, and when the condition does not respond to combination treatment, withdrawal of immunosuppressive therapies may be necessary.<sup>4</sup>

**The bottom line.** Molluscum contagiosum is less frequently seen in the HAART era; however, when present it usually indicates a high level of immunosuppression. Clinicians need to keep the relation in mind. ■

## REFERENCES

1. Chen X, Anstey AV, Bugert JJ. Molluscum contagiosum virus infection. *Lancet Infect Dis* 2013; 13:877–888.
2. Jung AC, Paauw DS. Diagnosing HIV-related disease: using the CD4 count as a guide. *J Gen Intern Med* 1998; 13:131–136.
3. Beutler BD, Cohen PR. Molluscum contagiosum of the eyelid: case report in a man receiving methotrexate and literature review of molluscum contagiosum in patients who are immunosuppressed secondary to methotrexate or HIV infection. *Dermatol Online J* 2016; 22:pii:13030/qt8vz669cj.
4. Gur I. The epidemiology of Molluscum contagiosum in HIV-seropositive patients: a unique entity or insignificant finding? *Int J STD AIDS* 2008; 19:503–506.
5. Filo-Rogulska M, Pindycka-Piaszczyńska M, Januszewski K, Jarzab J. Disseminated atypical molluscum contagiosum as a presenting symptom of HIV infection. *Postepy Dermatol Alergol* 2013; 30:56–58.



**FIGURE 2.** Histologic study of a lesion showed Henderson-Paterson bodies (arrows), confirming molluscum contagiosum virus infection (hematoxylin and eosin, × 100).

**ACKNOWLEDGMENT:** We thank Dr. Isabel Faro Viana for the histologic image.

**ADDRESS:** Telma Azevedo, MD, Department of Infectious Disease and Tropical Medicine, Centro Hospitalar de Lisboa Ocidental, Hospital de Egas Moniz, Calçada de Santo Amaro, n24, 1 dir, 1300-515 Lisboa, Portugal; telma.uwcad@gmail.com