

Online Features

Access

Cleveland Clinic Journal of Medicine content is readily available to all and is free of charge at www.ccjm.org. On your first visit, we will ask you to take a few minutes to register, but subsequent visits will be unencumbered except for an occasional request for your e-mail address when you visit using another device (eg, mobile phone, tablet).

Services

- Navigate quickly to articles in current and past issues via links on the home page and pull-down menus at the top of the page. Use the search function to find a specific article, or browse by topic or article type.
- Continuing medical education activities are accessible from article links and from a CME pull-down menu on the home page. Participation is free.
- Follow links on the home page to news, summaries of recent scientific meetings, and interactive quizzes.
- Click on the PDF symbol at the top of any online article to read, download, or print the article in PDF format.

Social Networking

To post a *CCJM* article to Facebook or Twitter, just click on the icon at the top of any online article.

www.ccjm.org

TABLE OF CONTENTS

FROM THE EDITOR

Fighting the reflux reflex **419**

We should think twice when making a clinical diagnosis of gastroesophageal reflux disease.

B.F. MANDELL

COMMENTARY

The USPSTF and screening for obstructive sleep apnea: Dispelling misconceptions **429**

Their finding of insufficient evidence might be misinterpreted and needs to be put into context.

R. MEHRA AND N. FOLDVARY-SCHAEFER

THE CLINICAL PICTURE

Black hairy tongue cured concurrently with respiratory infection **434**

Proposed causes include medications, hyposalivation, poor oral hygiene, smoking, and infection.

F. TOUS-ROMERO, S. BURILLO-MARTÍNEZ, M. PRIETO-BARRIOS, AND L. MAROÑAS-JIMÉNEZ

THE CLINICAL PICTURE

A 68-year-old man with a blue toe **436**

The patient had undergone coronary artery bypass grafting, which caused cholesterol crystal embolism.

K. SHIKINO, T. OTA, T. UEHARA, AND M. IKUSAKA

THE CLINICAL PICTURE

A dermatosis of pregnancy **440**

Eight days after giving birth, a 33-year-old woman presented with pruritic erythematous papules and plaques on the abdomen.

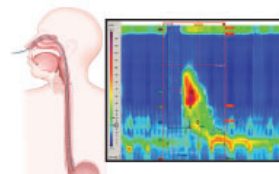
S. BRÁS, A. OLIVEIRA, P. MENDES-BASTOS, AND C. AMARO

IM BOARD REVIEW

A man with progressive dysphagia **443**

Difficulty swallowing can be caused by problems in the oropharynx or in the esophagus.

A.J. KICHLER AND S. GABBARD



CME
CREDIT

CONTINUED ON PAGE 416

CONTINUED FROM PAGE 415

REVIEW

**Apps and fitness trackers that measure sleep: 451
Are they useful?**

In general, they have major shortcomings and limited utility.

M.P. MANSUKHANI AND B.P. KOLLA



REVIEW

**Is there a doctor on board? 457
In-flight medical emergencies**

Although not legally required to render assistance, physicians have an ethical obligation to do so and should be prepared.

J.V. NABLE, C.L. TUPE, B.D. GEHLE, AND W.J. BRADY



REVIEW

**ERAs for menopause treatment: 463
Welcome the 'designer estrogens'**

These drugs stimulate estrogen receptors in some tissues and inhibit them in others, enabling tailored treatment.

H.D. HIRSCH, E. SHIH, AND H.L. THACKER



REVIEW

**Autosomal dominant polycystic kidney 471
disease and the heart and brain**

Early-onset hypertension is common. Other complications include heart disease and intracranial aneurysm.

V. KRISHNAPPA, P. VINOD, D. DEVERAKONDA, AND R. RAINA

DEPARTMENTS

CME Calendar 417

Letter to the Editor 428

Readers comment on fungal organisms in the brain (February 2017).

CME instructions 483

Upcoming Features

- Antibiotic stewardship: Why we must, how we can
- Tick-borne diseases: More than Lyme disease
- Venous thromboembolism: Optimal diagnosis
- Living with hematologic cancer
- Labels matter: Challenging conversations or challenging patients?
- Oral contraceptives and migraine: An update
- ADHD: Better diagnosis and management
- Antipsychotics for delirium in the hospital
- Will digital breast tomosynthesis improve mammography?

