

Online Features

Access

Cleveland Clinic Journal of Medicine content is readily available to all and is free of charge at www.ccjm.org. On your first visit, we will ask you to take a few minutes to register, but subsequent visits will be unencumbered except for an occasional request for your e-mail address when you visit using another device (eg, mobile phone, tablet).

Services

- Navigate quickly to articles in current and past issues via links on the home page and pull-down menus at the top of the page. Use the search function to find a specific article, or browse by topic or article type.
- Continuing medical education activities are accessible from article links and from a CME pull-down menu on the home page. Participation is free.
- Follow links on the home page to news, summaries of recent scientific meetings, and interactive quizzes.
- Click on the PDF symbol at the top of any online article to read, download, or print the article in PDF format.

Social Networking

To post a *CCJM* article to Facebook or Twitter, just click on the icon at the top of any online article.

www.ccjm.org

TABLE OF CONTENTS

FROM THE EDITOR

Appropriate diagnosis of tickborne infections 506

Fear of undertreatment of early infection can morph into unwarranted treatment of nonexistent chronic infection.

B.F. MANDELL

THE CLINICAL PICTURE

Swelling of both arms and chest after push-ups 508

Symptoms of rhabdomyolysis: myalgia, muscle weakness, dark urine, and, in some, muscle swelling.

K. SHIKINO, Y. HIROTA, AND M. IKUSAKA

THE CLINICAL PICTURE

Secondary syphilis 510

A 39-year-old man presents with generalized weakness, headache, nausea, and migratory arthralgia.

E. COLEMAN, A. FIAHLO, AND A. BRATEANU

EDITORIAL

Syphilis 100 years later: Another lost opportunity? 514

A century of progress and then backward steps on syphilis and other sexually transmitted diseases.

K.A. ENGLUND

THE CLINICAL PICTURE

A large mass in the right ventricle: Tumor or thrombus? 517

A 69-year-old woman with ovarian cancer presents with worsening dyspnea, lower-extremity edema, and dizziness.

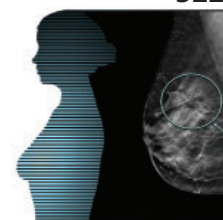
S. PATNAIK, M. SHAH, S. SHARMA, P. RAM, H.S. RAMMOHAN, AND A. RUBIN

REVIEW

Breast cancer screening: Does tomosynthesis augment mammography? 522

This technology may reduce recall rates and increase cancer detection rates, but outcome studies are needed.

T.A. TAKAHASHI, C.I. LEE, AND K.M. JOHNSON



CONTINUED ON PAGE 496

CONTINUED FROM PAGE 495

REVIEW

Living with hematologic cancer: Recommendations, solutions **528**

Once-terminal diagnoses are now chronic conditions. Survivors need a plan.

B. FAIMAN AND M. FAIMAN

CME CREDIT REVIEW

Patients with challenging behaviors: Communication strategies **535**

Having a plan to deal with difficult personality types leads to better communication and outcomes—and less stress.

I.N. SCHUERMEYER, E. SIEKE, L. DICKSTEIN, T. FALCONE, AND K. FRANCO

EDITORIAL

Labels matter: Challenging conversations or challenging people? **543**

Caring for patients is a complex, intricate, intimate privilege. To characterize it otherwise is to not fully understand it.

A. BOISSY

CME CREDIT REVIEW

Optimizing diagnostic testing for venous thromboembolism **545**

A thoughtful approach to diagnosing venous thromboembolism and screening for thrombophilic disorders.

P. RENDON, A.E. BURNETT, J. ZIMMERBERG-HELMS, T. GOOT, AND M.B. STREIFF

CME CREDIT REVIEW

Tickborne diseases other than Lyme in the United States **555**

Consider them in patients with known or potential tick exposure and fever or vague constitutional symptoms.

C. EICKHOFF AND J. BLAYLOCK

DEPARTMENTS

CME Calendar **497**

CME instructions **568**

Upcoming Features

- Antibiotic stewardship: Why we must, how we can
- Reimbursable obesity counseling in 20 minutes
- Antipsychotics for delirium in the hospital
- Contraceptives, stroke risk, and migraine with aura
- Concussion: Evaluation and management
- PCI for stable angina: Why do we still do it?
- Cardiovascular risk management in the frail elderly
- Is spirometry necessary to diagnose asthma?
- Cardiovascular outcomes of diabetes drugs

