

## THE CLINICAL PICTURE

**MOIZ SALAHUDDIN, MD**

Department of Internal Medicine,  
Albert Einstein Medical Center,  
Philadelphia, PA

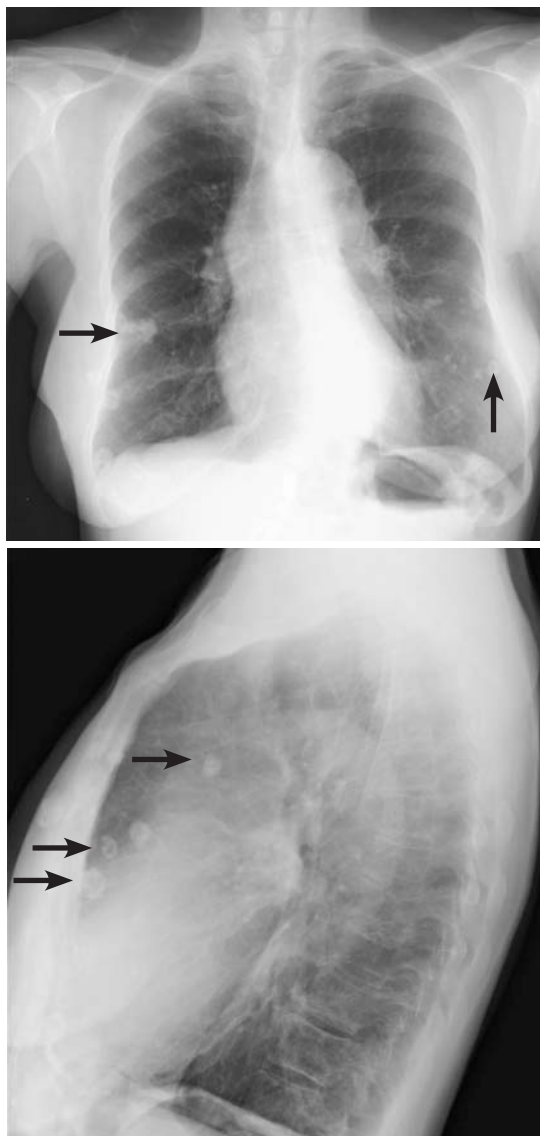
**THOMAS REILLY, MD**

Department of Internal Medicine,  
Albert Einstein Medical Center,  
Philadelphia, PA

**JORGE MORA, MD**

Department of Internal Medicine,  
Albert Einstein Medical Center,  
Philadelphia, PA

# Breast calcifications mimicking pulmonary nodules



**FIGURE 1.** Chest radiography frontal and lateral views showed lesions suggesting pulmonary nodules.

Including calcifications in the differential diagnosis can avoid unnecessary evaluations, save costs, and reduce radiation exposure

**A**N 80-YEAR-OLD WOMAN presented with dyspnea on exertion, present for the last 2 years. She said she became short of breath after walking 1 block. Her medical history was significant only for 35 pack-years of smoking.

On examination, her lung fields were clear, with no audible murmurs, and she had no lower-extremity edema. Her oxygen saturation was 98% on room air.

Chest radiography as part of the initial evaluation showed lesions on both sides that looked like pulmonary nodules. The locations of the lesions were similar on frontal and lateral views (**Figure 1**). No previous imaging was available for comparison. However, computed tomography (CT) showed numerous, rounded, coarse calcifications scattered throughout the breasts, likely representing degenerating fibroadenomas, consistent with the nodules on chest radiography. Mammography confirmed these findings (**Figure 2**).

### ■ BREAST CALCIFICATIONS CAN MIMIC PULMONARY NODULES

Diffuse bilateral calcifications on mammography are typically benign and represent either dermal calcification (spherical lucent-centered calcification that develops from a degenerative metaplastic process) or fibrocystic changes.<sup>1</sup> Up to 10% of women have fibroadenomas, and 19% of fibroadenomas have microcalcifications.<sup>2-4</sup> Therefore, given the high prevalence, calcified breast masses should be considered in the differential diagnosis when evaluating initial chest radiographs in women.

Calcifications in the breast can overlie the lung fields and mimic pulmonary nodules.

doi:10.3949/ccjm.84a.16048

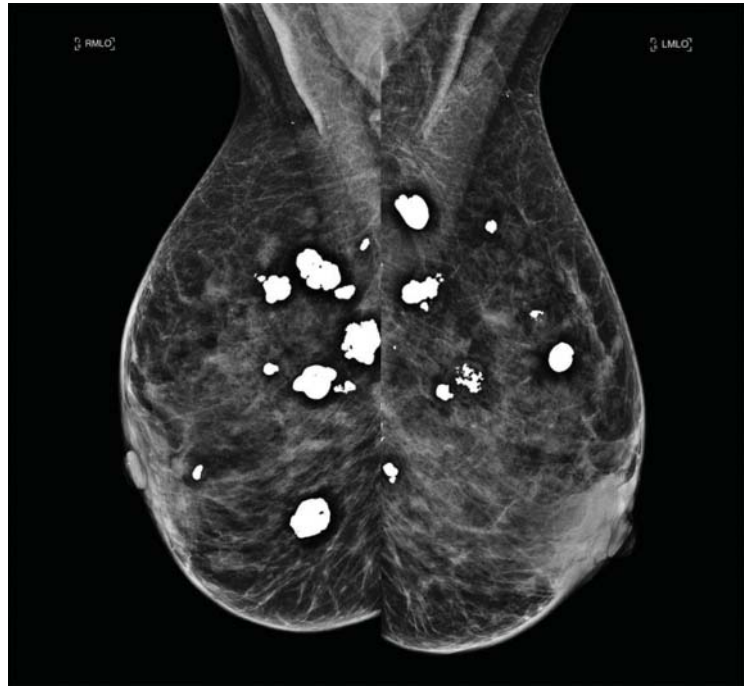When assessing pulmonary nodules, prior imaging of the chest should always be assessed if available to determine if a lesion is new or has remained stable.

Given our patient's age and 35-pack-year history of smoking, apparent pulmonary lesions caused concern and prompted chest CT to clarify the diagnosis. However, if the patient has no risk factors for lung malignancy, it can be safe to proceed with mammography.

By including breast calcifications in the differential diagnosis of apparent pulmonary nodules on chest radiography, the clinician can approach the case differently and inquire about a history of fibroadenomas and prior mammograms before pursuing a further workup. This can avoid unnecessary radiation exposure, the costs of CT, and apprehension in the patient raised by unwarranted concern for malignancy. ■

## REFERENCES

1. **Sitzman SB.** A useful sign for distinguishing clustered skin calcifications within the breast on mammograms. *AJR Am J Roentgenol* 1992; 158:1407–1408.
2. **Anastasiades OT, Bouropoulou V, Kontogeorgos G, Rachmanides M, Gogas I.** Microcalcifications in benign breast diseases. A histological and histochemical study. *Pathol Res Pract* 1984; 178:237–242.
3. **Millis RR, Davis R, Stacey AJ.** The detection and significance of calcifications in the breast: a radiological and



**FIGURE 2.** Mammography confirmed the presence of lesions in both breasts.

pathological study. *Br J Radiol* 1976; 49:12–26.

4. **Santen RJ, Mansel R.** Benign breast disorders. *N Engl J Med* 2005; 353:275–285.

.....  
**ADDRESS:** Moiz Salahuddin, MD, Department of Internal Medicine, Albert Einstein Medical Center, 5501 Old York Road, Philadelphia, PA 19141; salahudm@einstein.edu