

Online Features

Access

Cleveland Clinic Journal of Medicine content is readily available to all and is free of charge at www.ccjm.org. On your first visit, we will ask you to take a few minutes to register, but subsequent visits will be unencumbered except for an occasional request for your e-mail address when you visit using another device (eg, mobile phone, tablet).

Services

- Navigate quickly to articles in current and past issues via links on the home page and pull-down menus at the top of the page. Use the search function to find a specific article, or browse by topic or article type.
- Continuing medical education activities are accessible from article links and from a CME pull-down menu on the home page. Participation is free.
- Follow links on the home page to news, summaries of recent scientific meetings, and interactive quizzes.
- Click on the PDF symbol at the top of any online article to read, download, or print the article in PDF format.

Social Networking

To post a *CCJM* article to Facebook or Twitter, just click on the icon at the top of any online article.

www.ccjm.org

TABLE OF CONTENTS

FROM THE EDITOR

Watson, the game is a foot...or a palm 655

Sherlock Holmes I am not, but some useful clues are readily apparent if one is prepared to recognize them.

B.F. MANDELL

THE CLINICAL PICTURE.....

Heartburn or heart attack? A mimic of MI 664

The diagnosis: milk-alkali syndrome, complicated by thiazide use.

W.S. BOWMAN, A. FARID, AND P. ARONOWITZ

THE CLINICAL PICTURE.....

Palmar erythema as a sign of cancer 666

Red palms in an elderly patient can be due to a number of systemic diseases.

M. MAEKAWA

THE CLINICAL PICTURE.....

Metastatic pulmonary calcification and end-stage renal disease 668

CT may show diffusely calcified nodules, high-attenuation areas of consolidation, or fluffy ground-glass nodules.

J.M. WALTER, M. STANLEY, AND B.D. SINGER

SMART TESTING

Measuring both serum amylase and lipase for acute pancreatitis lowers quality and raises cost 670

Measuring lipase alone is sufficient.

A. AKHTAR, R. SARODE, AND D. AGRAWAL

MEDICAL GRAND ROUNDS.....

Antibiotic stewardship: Why we must, how we can 673

It has always been a good idea; now it is required.

A. SRINIVASAN

INTERPRETING KEY TRIALS.....

Renal denervation: What happened, and why? 681

Despite promising initial results, this treatment failed in its largest trial to date. Is it dead? Can it be revived?

M.H. SHISHEBOR, T.A. HAMMAD, AND G. THOMAS

CONTINUED ON PAGE 654

CONTINUED FROM PAGE 651

EDITORIAL

Renal denervation: Are we on the right path? 687

Before renal denervation can be a mainstream therapy, we need proof that it reduces blood pressure or clinical events.

A.E. DENKTAS, D. PANIAGUA, AND H. JNEID

IM BOARD REVIEW

Postoperative delirium in a 64-year-old woman 690

Nine days after surgery, her mental status takes an abrupt turn for the worse. What is going on?

M. IMM, L.F. TORRES, AND M. KOTTAPALLY

EDITORIAL

Bedside manners: How to deal with delirium 699

Delirium is often overlooked. Clinical observation remains important.

R.G.J. WESTENDORP

CME CREDIT IM BOARD REVIEW

Another complication of cirrhosis 701

A patient with cirrhosis presents with acute abdominal pain and shock.

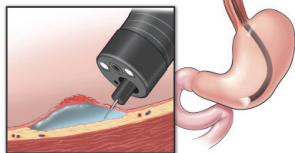
H. AYOUBIEH AND E. ALKHALILI

CME CREDIT REVIEW

A minimally invasive treatment for early GI cancers 707

Endoscopic submucosal dissection allows curative resection of early malignant gastrointestinal lesions.

L.K. MEJÍA-PÉREZ, S. ABE, T. STEVENS, M.A. PARSİ, S.N. JANG, I. ODA, J.J. VARGO, Y. SAITO, AND A. BHATT



CME CREDIT REVIEW

Reproductive planning for women after solid-organ transplant 719

Pregnancy can succeed, but patients must wait at least a year. Until then, meticulous contraception is mandatory.

M. AL-BADRI, J.M. KLING, AND S. VEGUNTA

DEPARTMENTS

CME Calendar 680

Letters to the Editor 658

Readers comment on anticoagulation for atrial fibrillation (January 2017) and on cardiac masses (July 2017).

CME instructions Inside back cover

Upcoming Features

- Cardiovascular outcomes with diabetes drugs
- PCI for stable angina: No benefit, but still common
- Idiopathic hypercalciuria: Stones and bones
- Disparities in cervical cancer: Biology is not destiny
- Treating obesity with counseling and drugs
- VTE, anticoagulation, bridging: One size doesn't fit all
- Cardiovascular risk management in the frail elderly
- Long-term azithromycin for respiratory diseases
- Perioperative risk stratification
- Raynaud phenomenon: Help for the cold and blue

