

NICHOLAS S. DUCA, MD
Assistant Professor of Medicine,
Division of General Internal Medicine,
Penn State Health Milton S. Hershey
Medical Center, Hershey, PA

KRISTIAN FETERIK, MD, MBA
Division of General Internal Medicine,
University of Pittsburgh, PA

JONHAN HO, MD, MS
Department of Dermatology and Pathology,
University of Pittsburgh, PA

Pancreatitis: The great masquerader?

The syndrome
mimics
rheumatologic
disease,
often presenting
without
abdominal pain

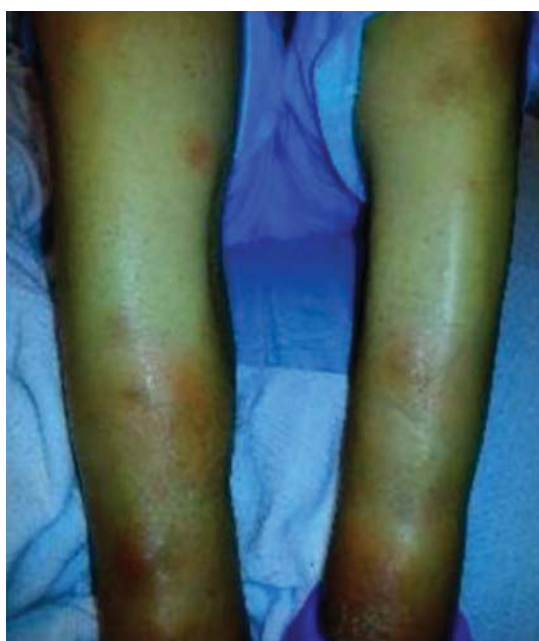

Figure 1. The patient had multiple raised erythematous nodules on the lower extremities consistent with panniculitis.

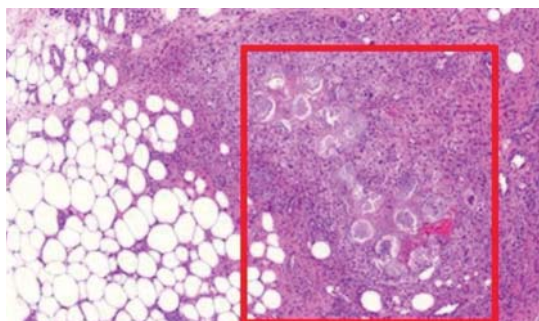


Figure 2. Biopsy study revealed pancreatic panniculitis. The subcutis showed mixed inflammation with characteristic “ghost adipocytes” of adipocyte necrosis (red box) (hematoxylin and eosin, $\times 10$).

doi:10.3949/ccjm.85a.18062

A 55-YEAR-OLD MAN presented to the emergency department with 1 week of bilateral lower-extremity joint pain associated with painful skin nodules. He had a history of chronic recurrent alcoholic pancreatitis. He denied abdominal pain, nausea, or vomiting.

Physical examination revealed synovitis of the ankles and knees bilaterally and circumferential erythematous nodules 0.5 to 1.5 cm in diameter on the lower extremities (**Figure 1**).

Results of initial laboratory testing:

- Alkaline phosphatase 300 IU/L (reference range 36–108)
- Erythrocyte sedimentation rate 81 mm/h (0–15)
- Lipase 20,000 U/L (16–61).

Skin biopsy of lower-extremity lesions showed lobular necrosis of the subcutaneous fat, consistent with pancreatic panniculitis (**Figure 2**). Computed tomography revealed an acute exacerbation of chronic (“acute-on-chronic”) pancreatitis, with pseudocyst formation and pancreatic duct dilation.

Because of the persistent elevation in the serum lipase level and the dilation of the pancreatic duct shown on imaging, endoscopic retrograde cholangiopancreatography was done to evaluate for malignant obstruction; it confirmed pancreatic duct stricture and dilation (**Figure 3**). Brush cytology study was negative for pancreatic or biliary malignancy. The pancreatic duct was dilated and stented, and the panniculitis and polyarthritis rapidly improved, with normalization of serum lipase levels. At a 3-month follow-up visit, the patient was asymptomatic with no recurrence of pancreatitis, panniculitis, or polyarthritis. He was subsequently lost to follow-up.

AN ATYPICAL PRESENTATION OF A COMMON DISEASE

Epidemiology and pathophysiology

Pancreatitis, panniculitis, and polyarthritides syndrome is a rare systemic complication of pancreatic disease occurring most often in middle-aged men with an acute exacerbation of chronic pancreatitis and a history of alcohol use disorder.^{1,2} It is also associated with pancreatic pseudocyst, pancreas divisum, and pancreatic adenocarcinoma.^{3–6} It is characterized by systemic fat necrosis secondary to severe and persistent elevation of pancreatic enzymes. The mortality rate is high; in a case series of 25 patients, 24% died within days to weeks after admission.¹

Clinical presentation and treatment

The diagnosis of pancreatitis, panniculitis, and polyarthritides syndrome is often missed. Abdominal pain is mild or absent in over 60% of patients.¹ Therefore, a high index of suspicion is required for early diagnosis.

The differential diagnosis includes sarcoidosis (including Löfgren syndrome), subcutaneous infection, and vasculitis. “Ghost adipocytes” on skin biopsy are pathognomonic for pancreatic panniculitis and are the result of saponification; they appear to be anuclear, with basophilic material throughout the cytoplasm.⁷ Arthrocentesis of affected joints may reveal thick, creamy material, rich in triglycerides, which is diagnostic of pancreatic arthritides.^{1,8}

Treatment relies on correction of the underlying pancreatic pathology. Pancreatitis, panniculitis, and polyarthritides syndrome has

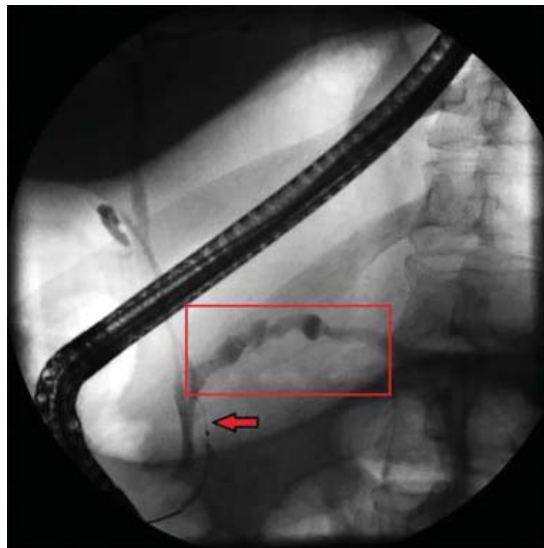


Figure 3. Endoscopic retrograde cholangiopancreatography confirmed pancreatic stricture (arrow) and dilation of the pancreatic duct (box).

been successfully treated by cyst gastrostomy, pancreatic duct stenting, and pancreaticoduodenectomy.^{7,9–11}

TAKE-HOME POINTS

- Pancreatitis, panniculitis, and polyarthritides syndrome mimics rheumatologic disease and often presents without abdominal pain.
- The diagnosis is confirmed by the presence of elevated serum lipase or amylase, pancreatic imaging showing pancreatitis, and ghost adipocytes on skin biopsy.
- Treatment is aimed at correcting the underlying pancreatic abnormality.

REFERENCES

1. Narváez J, Bianchi MM, Santo P, et al. Pancreatitis, panniculitis, and polyarthritides. *Semin Arthritis Rheum* 2010; 39(5):417–423. doi:10.1016/j.semarthrit.2008.10.001
2. Mourad FH, Hannoush HM, Bahlawan M, Uthman I, Uthman S. Panniculitis and arthritis as the presenting manifestation of chronic pancreatitis. *J Clin Gastroenterol* 2001; 32(3):259–261. PMID:11246359
3. Borowicz J, Morrison M, Hogan D, Miller R. Subcutaneous fat necrosis/panniculitis and polyarthritides associated with acinar cell carcinoma of the pancreas: a rare presentation of pancreatitis, panniculitis and polyarthritides syndrome. *J Drugs Dermatol* 2010; 9(9):1145–1150. PMID:20865849
4. Hudson-Peacock MJ, Regnard CF, Farr PM. Liquefying panniculitis associated with acinous carcinoma of the pancreas responding to octreotide. *J R Soc Med* 1994; 87(6):361–362. PMID:8046712
5. Vasdev V, Bhakuni D, Narayanan K, Jain R. Intramedullary fat necrosis, polyarthritides and panniculitis with pancreatic tumor: a case report. *Int J Rheum Dis* 2010; 13(4):e74–e78. doi:10.1111/j.1756-185X.2010.01548.x
6. Haber RM, Assaad DM. Panniculitis associated with a pancreas divisum. *J Am Acad Dermatol* 1986; 14(2 pt 2):331–334. PMID:3950133
7. Francome J, Kingsnorth AN, Tunn E. Panniculitis, arthritis and pancreatitis. *Br J Rheumatol* 1995; 34(7):680–683. PMID:7670790
8. Price-Forbes AN, Filer A, Udeshi UL, Rai A. Progression of imaging in pancreatitis panniculitis polyarthritides (PPP) syndrome. *Scand J Rheumatol* 2006; 35(1):72–74. doi:10.1080/03009740500228073
9. Harris MD, Bucobo JC, Buscaglia JM. Pancreatitis, panniculitis, polyarthritides syndrome successfully treated with EUS-guided cyst-gastrostomy. *Gastrointest Endosc* 2010; 72(2):456–458. doi:10.1016/j.gie.2009.11.040
10. Lambiase P, Seery JP, Taylor-Robinson SD, Thompson JN, Hughes JM, Walters JR. Resolution of panniculitis after placement of pancreatic duct stent in chronic pancreatitis. *Am J Gastroenterol* 1996; 91(9):1835–1837. PMID:8792709
11. Potts JR. Pancreatic-portal vein fistula with disseminated fat necrosis treated by pancreaticoduodenectomy. *South Med J* 1991; 84(5):632–635. PMID:2035087

ADDRESS: Nicholas S. Duca MD, Division of General Internal Medicine, Penn State Health Milton S. Hershey Medical Center, 500 University Drive H034, Hershey, PA 17036; nduca@pennstatehealth.psu.edu