

TABLE OF CONTENTS

FROM THE EDITOR

**Deprescribing:
When trying for less is more** **179**

We should periodically revisit the goals and rationale for all prescribed medications.

B.F. MANDELL

THE CLINICAL PICTURE.....

Primary livedo reticularis of the abdomen **181**

Livedo reticularis can be the manifestation of a wide range of conditions—or not.

M. CHEW AND P. ARONOWITZ

THE CLINICAL PICTURE.....

Methemoglobinemia in an HIV patient **186**

He had restarted his home dapsone prophylaxis, but his dyspnea worsened and his urine became dark.

R. RAIKER, W.C. LIPPERT, AND R. CHADHA

THE CLINICAL PICTURE.....

Ascites from intraperitoneal urine leakage after pelvic radiation **188**

Six years earlier, the patient had undergone hysterectomy and chemoradiotherapy for cervical cancer.

T. FUJIKAWA AND Y. TOKUDA

1-MINUTE CONSULT

**Hypertension in older adults:
What is the target blood pressure?** **193**

Goal: systolic pressure below 130 mm Hg if the patient can take multiple medications and be followed closely.

A. GARG AND B.J. MESSINGER-RAPPORT

CME CREDIT **IM BOARD REVIEW**.....

A 67-year-old woman with bilateral hand numbness **200**

Her history includes type 2 diabetes mellitus, dyslipidemia, hypertension, diastolic heart failure, and thyroid surgery.

S.S. RADWAN, K.M. HAMO, AND A.A. ZAYED

CONTINUED ON PAGE 178

Online Features

Access

Cleveland Clinic Journal of Medicine content is readily available to all and is free of charge at www.ccjm.org. On your first visit, we will ask you to take a few minutes to register, but subsequent visits will be unencumbered except for an occasional request for your e-mail address when you visit using another device (eg, mobile phone, tablet).

Services

- Navigate quickly to articles in current and past issues via links on the home page and pull-down menus at the top of the page. Use the search function to find a specific article, or browse by topic or article type.
- Continuing medical education activities are accessible from article links and from a CME pull-down menu on the home page. Participation is free.
- Follow links on the home page to news, summaries of recent scientific meetings, and interactive quizzes.
- Click on the PDF symbol at the top of any online article to read, download, or print the article in PDF format.

Social Networking

To post a *CCJM* article to Facebook or Twitter, just click on the icon at the top of any online article.

www.ccjm.org

CONTINUED FROM PAGE 176

CME CREDIT REVIEW
Alzheimer dementia: Starting, stopping drug therapy **209**

It is reasonable to consider discontinuing therapy when a patient has progressed to advanced dementia.

L.D. KIM AND R.M. FACTORA

CME CREDIT REVIEW
Primary care management of chronic pelvic pain in women **215**

While referral may eventually be indicated, primary care doctors can take steps to diagnose and manage the condition.

R. BONNEMA, M. McNAMARA, J. HARSH, AND E. HOPKINS

CME CREDIT REVIEW
Which test for CAD should be used in patients with left bundle branch block? **224**

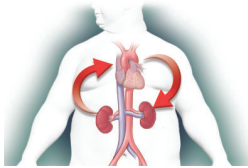
CT angiography is the first-line test in those under 65; for older patients there are SPECT and dobutamine echocardiography.

B. XU, P. CREMER, W. JABER, S. MOIR, S.C. HARB, AND L.L. RODRIGUEZ

CME CREDIT REVIEW
Acute cardiorenal syndrome: Mechanisms and clinical implications **231**

Volume overload is central to its pathogenesis, and accurate assessment of volume status is critical.

G.S. THIND, M. LOEHRKE, AND J.L. WILT



EDITORIAL
Hemodynamically, the kidney is at the heart of cardiorenal syndrome **240**

In heart failure, the heart and the kidneys share a rocky relationship.

J.L. GRODIN

DEPARTMENTS
Correction **189**

Errors occurred in: Bartholomew JR. Update on the management of venous thromboembolism. *Cleve Clin J Med* 2017; 84(suppl 3): 39–46.

CME Calendar **192**

CME instructions **243**

Upcoming Features

- **Female athlete triad: It takes a team**
- **Gallstones: Intervene or observe?**
- **Should we supplement calcium and vitamin D?**
- **Troponin elevation: Not just in acute coronary syndrome**
- **Genitourinary syndrome of menopause: A proactive approach**
- **Renal disease in surgical patients: Minimizing the impact**
- **Hypertrophic cardiomyopathy: It's complicated**



DEDICATED TO LIFELONG LEARNING
CLEVELAND CLINIC JOURNAL OF MEDICINE