

TABLE OF CONTENTS

FROM THE EDITOR

Understanding the tests we order: Comments and an invitation 257

Some new laboratory tests go through a life cycle, first being used by subspecialists and then by physicians everywhere.

B.F. MANDELL

THE CLINICAL PICTURE.....

Hyperkeratotic fissured plaques on both hands: Mechanic’s hands 268

This sign is seen in about 30% of patients with antisynthetase syndrome.

A. BISHNOI AND D. PARSAD

THE CLINICAL PICTURE.....

Hidden lesion easily missed on chest radiography 270

Chest radiography showed an opacity behind the heart, and CT angiography revealed it to be an aortic aneurysm.

K. LAPUMNUAYPOL AND J.M. STEMPEL

1-MINUTE CONSULT

Are serum troponin levels elevated in conditions other than acute coronary syndrome? 274

Yes. Troponin elevation is a nonspecific sign.

K. SEBASTIAN, A. WESTER, A. KOTTAM, AND A.O. SOUBANI

REVIEW

Musculoskeletal ultrasonography basics 283

Ultrasonography is emerging as a core method to evaluate musculoskeletal problems.

M.C. FORNEY AND P.B. DELZELL

EDITORIAL

Musculoskeletal ultrasonography has arrived 301

With its many advantages, it has become a mainstay in many subspecialties.

J. SZCZYGIEL CUNHA AND A.M. REGINATO

CONTINUED ON PAGE 256

Online Features

Access

Cleveland Clinic Journal of Medicine content is readily available to all and is free of charge at www.ccjm.org. On your first visit, we will ask you to take a few minutes to register, but subsequent visits will be unencumbered except for an occasional request for your e-mail address when you visit using another device (eg, mobile phone, tablet).

Services

- Navigate quickly to articles in current and past issues via links on the home page and pull-down menus at the top of the page. Use the search function to find a specific article, or browse by topic or article type.
- Continuing medical education activities are accessible from article links and from a CME pull-down menu on the home page. Participation is free.
- Follow links on the home page to news, summaries of recent scientific meetings, and interactive quizzes.
- Click on the PDF symbol at the top of any online article to read, download, or print the article in PDF format.

Social Networking

To post a *CCJM* article to Facebook or Twitter, just click on the icon at the top of any online article.

www.ccjm.org

CONTINUED FROM PAGE 252

CME CREDIT SYMPTOMS TO DIAGNOSIS 303

A 71-year-old woman with shock and a high INR

She presents with an acute change in mental status, blood pressure 80/40 mm Hg, pulse 130, INR 6.13.

R.Y. ZAGHLOL, M.E. TIERNEY, L.Y. ZAGHLOL, AND A.A. ZAYED

CME CREDIT REVIEW 313

The female athlete triad: It takes a team

An energy deficit from increased exercise, decreased intake, or both can suppress the menstrual cycle and lead to bone loss.

J. MEHTA, B. THOMPSON, AND J.M. KLING

EDITORIAL 321

Make no bones about it!

It is important to diagnose and treat the female athlete triad to maintain optimal bone health.

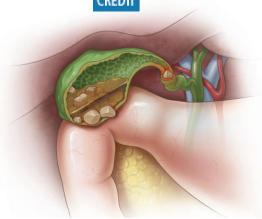
E. MATZKIN

CME CREDIT REVIEW 323

Gallstones: Watch and wait, or intervene?

Consider laparoscopic cholecystectomy for symptomatic cholelithiasis, expectant management for asymptomatic cases.

M. IBRAHIM, S. SARVEPALLI, G. MORRIS-STIFF, M. RIZK, A. BHATT, R.M. WALSH, U. HAYAT, A. GARBER, J. VARGO, AND C.A. BURKE



DEPARTMENTS 261

Letters to the Editor

Readers comment on perioperative interruption of dual antiplatelet therapy (November 2017).

CME Calendar 282

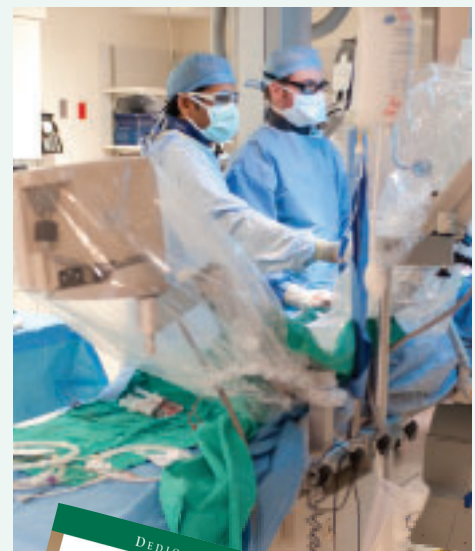
Corrections 332

Errors occurred in Shellenberger RA, Balakrishnan B, Avula S, Ebel A, Shaik S. Diagnostic value of the physical examination in patients with dyspnea. *Cleve Clin J Med* 2017; 84(12):943–950; and in Matsuura H, Hata H. Gas under the right diaphragm. *Cleve Clin J Med* 2018; 85(2):98–100.

CME Instructions 333

Upcoming Features

- Hypertrophic cardiomyopathy: A complex disease
- Should we supplement calcium and vitamin D?
- Infective endocarditis: How urgent is surgery?
- Genitourinary syndrome of menopause: A proactive approach
- Renal disease in surgical patients: Minimizing the impact
- Life after critical care: The journey forward
- Traveling while diabetic: A survival guide



DEDICATED TO LIFELONG LEARNING
CLEVELAND CLINIC JOURNAL OF MEDICINE